

GREENLIGHT XPS™ LASER THERAPY SYSTEM:

A SYSTEMATIC APPROACH
TO VAPORIZATION



Gregg R. Eure, MD, FACS

Urology of Virginia
Virginia Beach, Virginia

GREENLIGHT XPS™ LASER THERAPY SYSTEM:

A SYSTEMATIC APPROACH TO VAPORIZATION

TECHNIQUE SPOTLIGHT

Gregg R. Eure, MD, FACS

Focusing on key fundamentals and following a systematic approach to laser vaporization can enhance **GreenLight™ Laser Therapy** procedural experience. Dr. Gregg Eure has used GreenLight Laser Therapy effectively in his practice for over 14 years and has performed well over 2,000 procedures using the technology. The following technique summary was developed based on his experience with the technology and his patient outcomes.

Patient selection

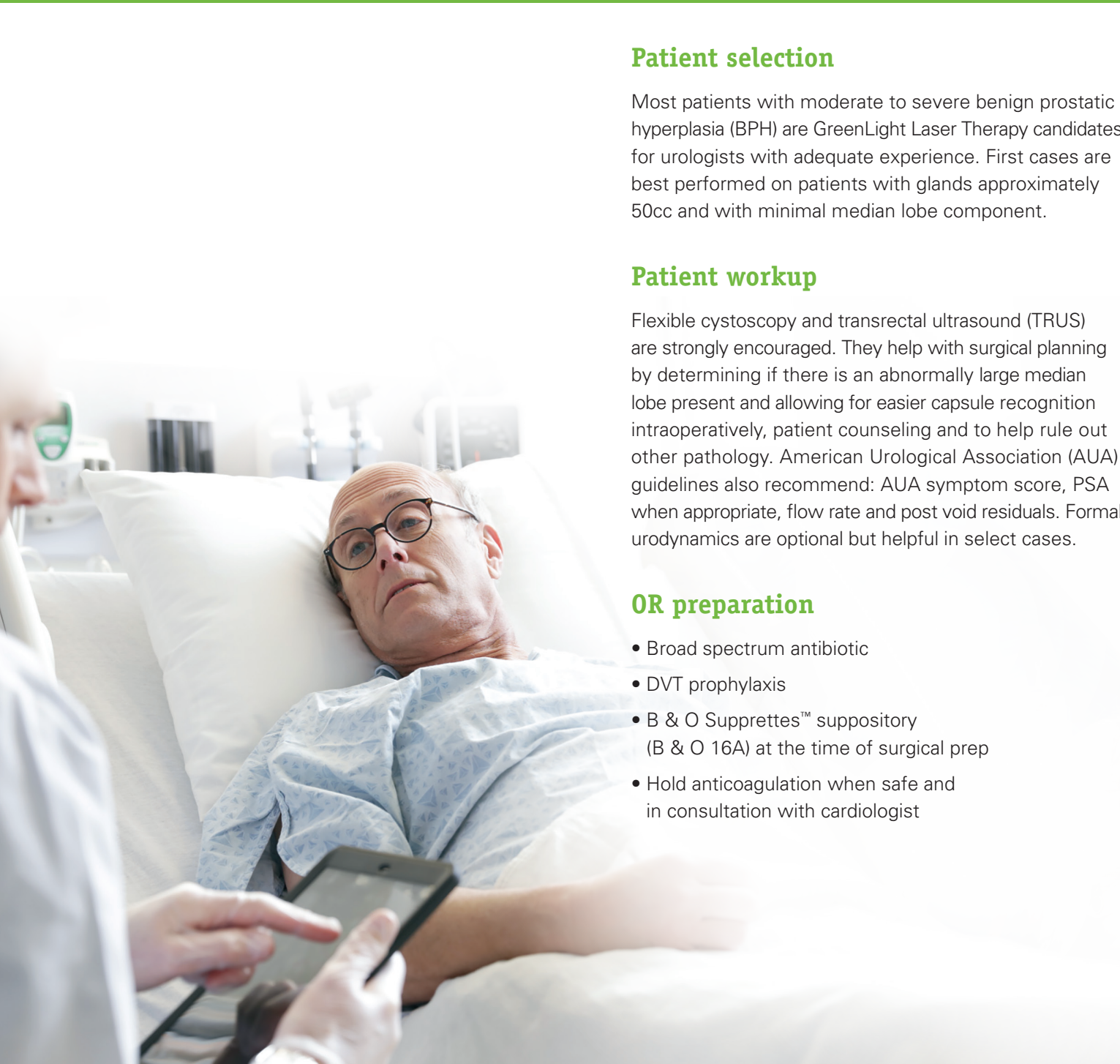Most patients with moderate to severe benign prostatic hyperplasia (BPH) are GreenLight Laser Therapy candidates for urologists with adequate experience. First cases are best performed on patients with glands approximately 50cc and with minimal median lobe component.

Patient workup

Flexible cystoscopy and transrectal ultrasound (TRUS) are strongly encouraged. They help with surgical planning by determining if there is an abnormally large median lobe present and allowing for easier capsule recognition intraoperatively, patient counseling and to help rule out other pathology. American Urological Association (AUA) guidelines also recommend: AUA symptom score, PSA when appropriate, flow rate and post void residuals. Formal urodynamics are optional but helpful in select cases.

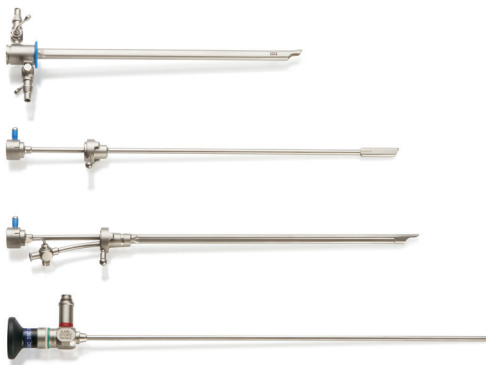OR preparation

- Broad spectrum antibiotic
- DVT prophylaxis
- B & O Supporettes™ suppository (B & O 16A) at the time of surgical prep
- Hold anticoagulation when safe and in consultation with cardiologist



OR equipment and anesthesia

- General anesthesia with laryngeal mask preferred, but spinal can also be used.
- Comfortable rolling chair with arms to perform the procedure sitting.
- Continuous flow cystoscope (23–24.5F) with laser bridge for MoXy™ Liquid Cooled Fiber, and visual obturator to avoid traumatizing mucosa upon scope insertion.
- Continuous flow resectoscope (26–28F) with a separate laser bridge for MoXy Fiber may be helpful for larger, bloody glands.
- Dedicated urology HD camera (pendulum style) recommended.



Cystoscope set with visual obturator



Resectoscope set with visual obturator

- Camera filter or 30 degree telescope with built-in GreenLight system filter preferred.
- Two to four 3 liter bags of normal saline with large irrigation tubing.
- Additional 1 liter bag of saline for irrigation of the MoXy Fiber; ensure this is connected utilizing IV tubing and irrigating prior to fiber insertion into the scope.

GreenLight™ Laser Therapy fundamentals

- **Fiber-to-tissue distance:** 1–3mm away from tissue is optimal, but not in contact with tissue. The MoXy Fiber tip is 2.1mm and provides a good visual to help determine proper fiber-to-tissue distance.



Optimal fiber-to-tissue distance

- **Sweep speed:** adjust sweep speed to maximize vaporization efficiency. The key is to heat the tissue to 100 degrees Celsius for vaporization to occur.
- **Sweep arc:** 30 degrees is optimal.
- **Power settings:** start low and increase to maintain maximal vaporization while maintaining visibility.
- Minimize the number of times the bladder is drained during the procedure, as this can result in undesired bleeding due to reduction of pressure within the bladder.

Scope handling and maneuvering

This is important and differs somewhat from transurethral resection of the prostate (TURP):

- Rotate the fiber as described in the *Fundamentals* section with the dominant hand.
- Hold the scope (not the camera) with the non-dominant hand.
- Move both hands together and rotate the scope, as one would with TURP, to circumferentially treat the prostate.

A SYSTEMATIC APPROACH TO VAPORIZATION PROCEDURE

Identifying landmarks 1 2 3

- Atraumatically, locate the ureteral orifices (UOs) using a visual obturator. If they cannot be seen, at least try to identify the ureteric ridge. After vaporizing down the bladder neck, the UOs can usually be found. (Fig. 1)
- Assess how much median lobe is present and assess the amount of intravesical tissue to be vaporized. (Fig. 2)
- Identify the verumontanum. You may consider marking beside it on the lateral lobe for ease in locating later. (Fig. 3)
- The bladder should be kept at least moderately distended. This helps identify the prostate from the bladder anteriorly and laterally, and also helps control bleeding.

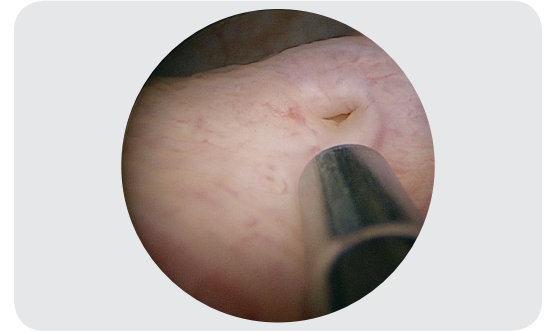


Figure 1 - Left ureteral orifice

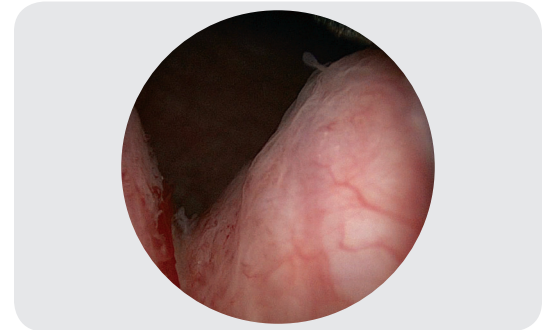


Figure 2 - Assessment of median lobe

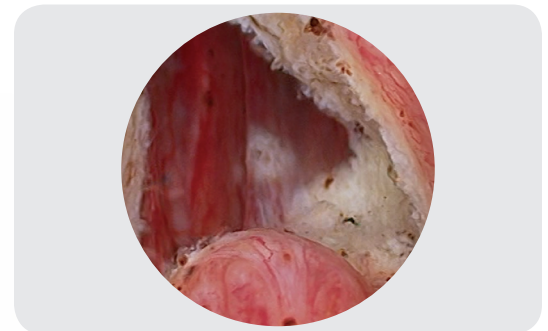
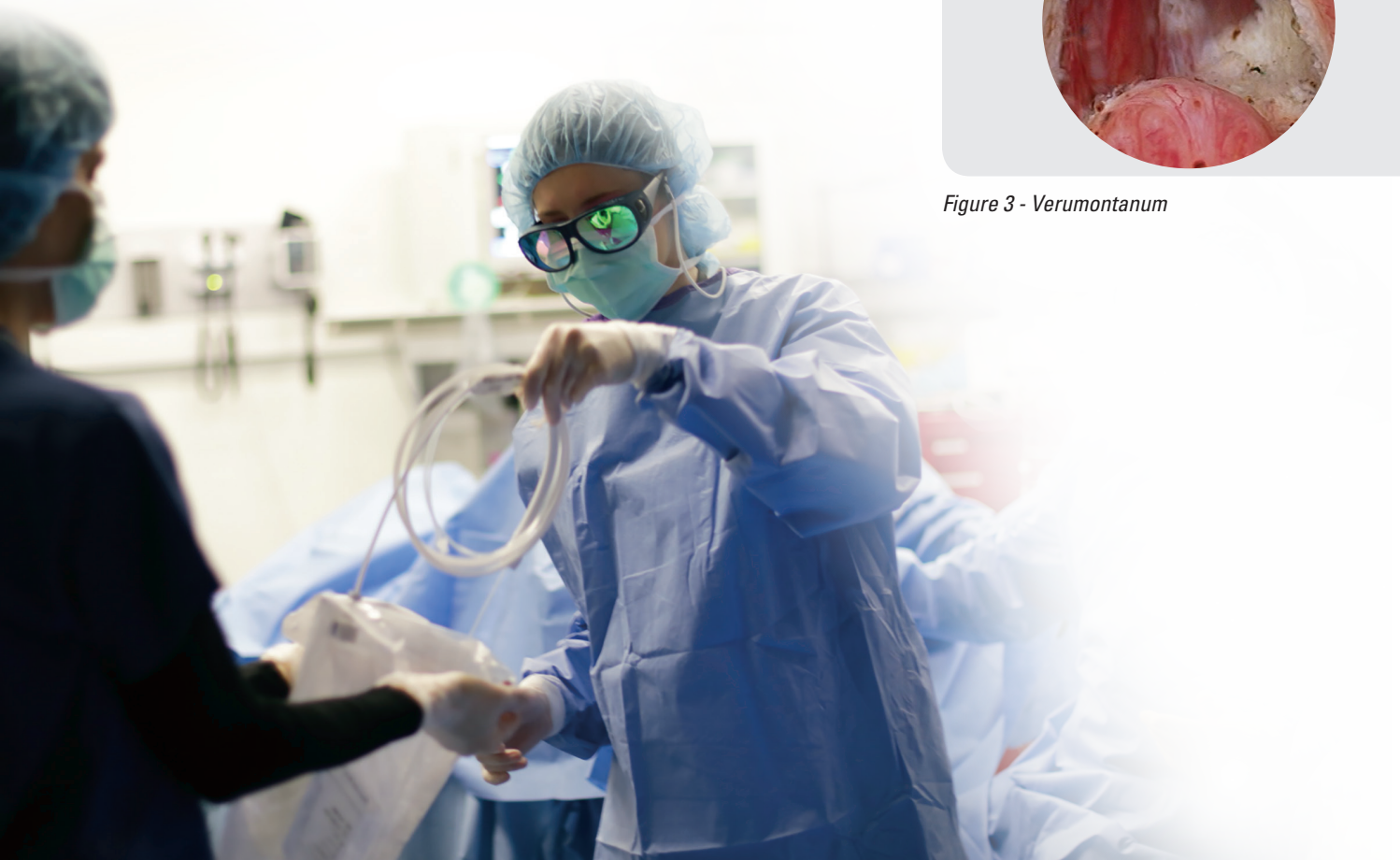




Figure 3 - Verumontanum



Laser vaporization

- Activate aiming beam by putting the laser on “ready.” (Fig. 4)  4
- Begin with low power (80W) with the goal to turn up the power quickly as a working channel is created and good flow is established. On prostate glands over 60–80g, the goal is to maintain efficient vaporization by titrating power accordingly.  5
- Efficient vaporization remains the key goal and is confirmed with the creation of large (scuba-like) bubbles. Small “champagne-like” bubbles result from a combination of vaporization and coagulation. Vaporizing without the creation of bubbles is evidence of coagulation and is the biggest cause of post-operative irritative symptoms. (Fig. 5)
- The first step is to open the bladder neck to improve flow of bubbles and irrigation into the bladder. Start at 5 and 7 o’clock. Create grooves at these locations from the bladder neck back towards the apex. Extend this down at the bladder neck to see circular fibers and even the bladder neck level with the trigone of the bladder. Increasing to 120W (still considered low wattage with the GreenLight XPS System) may be needed to maintain efficient vaporization. (Fig. 6, 7 & 8)  6
- Bleeding may be encountered at the 5 and 7 o’clock locations where the vasculature enters the prostate. Vaporizing around and through these areas to control it is important. If needed, utilize the TruCoag™ feature and “paint” around the bleeder to create haemostasis.
- Vaporizing to create these grooves then demarcates what median lobe is present.

Efficient vaporization remains the key goal and is confirmed with the creation of **large (scuba-like) bubbles**. Small “champagne-like” bubbles result from a combination of vaporization and coagulation.

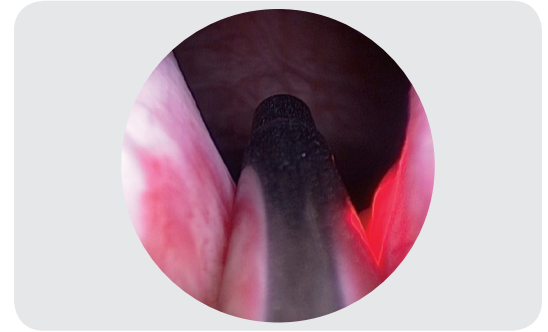


Figure 4 - Aiming beam

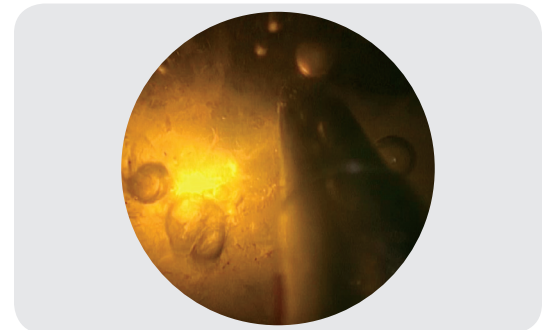


Figure 5 - Scuba-like bubbles

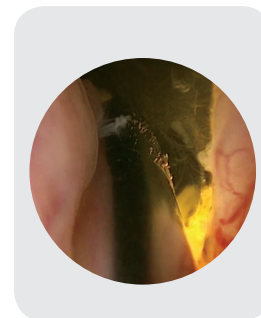


Figure 6 - Laser firing at 5 o'clock

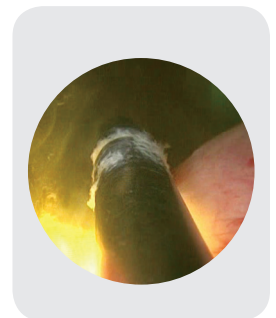


Figure 7 - Laser firing at 7 o'clock

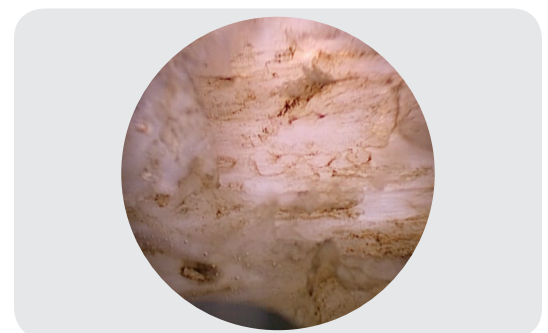


Figure 8 - Bladder neck fibers

A SYSTEMATIC APPROACH TO VAPORIZATION PROCEDURE

Median lobe

- Usually at this point, attention is turned to the median lobe. Vaporizing up the sides of the median lobe is the quickest and most efficient way to treat it. (Fig. 9)
- Even when the median lobe extends into the bladder, it can be successfully treated by lasing it from the sides with the fiber kept close to the tip of the scope and the scope rotated laterally. Maintain visibility to see where the aiming beam is at all times.
- More power may be needed to continue efficient vaporization of a larger median lobe.

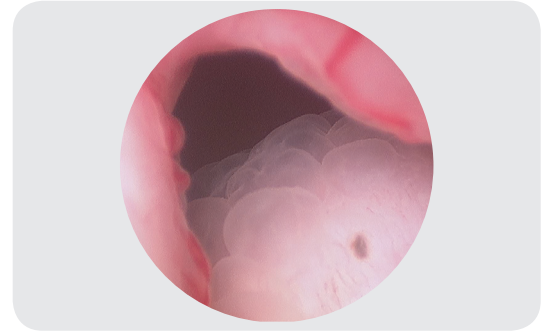


Figure 9 - Inflamed median lobe

Creating a channel at lower wattage

- Between 80 and 120W (low power), create a circumferential channel. The goal here is to vaporize through the 1–2mm of mucosa to control bleeding.
- Work from the bladder neck back towards the apex. This allows improved flow and visibility.
- It is important to be systematic. Not only will this lead to a quicker procedure, but if bleeding is encountered it will be easier to find and address. A smoother fossa will also be more apparent at the end of the procedure.
- Laser vaporize up and down the lateral lobes with an overlapping path.



It is important to be systematic. Not only will this lead to a quicker procedure, but if bleeding is encountered it will be easier to find and address.

Increasing the power for the most efficient vaporization and minimal coagulation

- After an adequate channel is created, increase the power systematically to achieve efficient vaporization as evidenced by scuba-like bubbles.
- Continue methodically vaporizing the lateral lobes to the capsule. Once a small area of capsule is identified, move to nearby areas to create the same depth of treatment. Try not to continue vaporizing in the same area of capsule to avoid excessive venous sinus bleeding.



Anterior tissue

- After the lateral lobes and median lobe are adequately treated, address the anterior tissue. Remember, the prostate is the thinnest in this area and the anterior lateral lobes. (Fig. 10)
- If anterior tissue falls into the field and obscures visibility, it may need to be vaporized sooner.

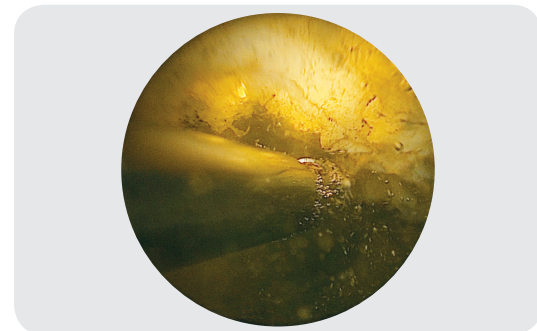


Figure 10 - Lasing anterior tissue

Apical tissue

- Vaporize alongside and even beyond the veru if adenoma extends distally in larger glands. (Fig. 11 & 12)
- Decrease the power to lower wattage (~120W) for less effect on the external sphincter.
- Working “around the corner” at the apex is important to treat transition zone tissue that may fall into the fossa laterally and potentially cause post-op obstruction.

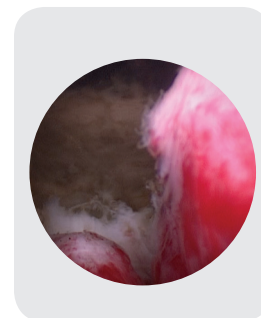


Figure 11 - Untreated left apical tissue

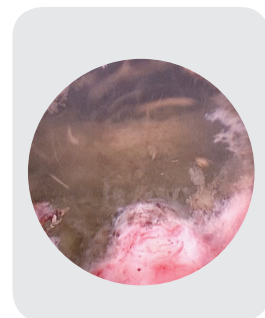

Figure 12 - Treated apical tissue

Completing the procedure 9

- The goal is an open fossa with vaporization to the surgical capsule. Fifty to 70% of the prostate volume will be eliminated. The PSA should drop greater than 50% after adequate healing. The fossa should look like a well-resected TURP defect. (Fig. 13)
- Vaporizing to the capsule not only helps prevent regrowth, but gives the best outcomes and durability. The remaining fossa will be relatively smooth. Any small hanging tissue will flush out, and within 3 to 4 weeks there is generally smooth re-epithelialization. (Fig. 14)
- Confirm the UOs are left unharmed.
- Confirm there is no arterial bleeding, and treat if needed.
- Administer Lasix™ 20mg approximately 10 minutes prior to completing the procedure, if desired. This not only helps diuresis, but also helps irrigate the catheter.
- Place a 20 or 22F 2-way Foley catheter (a 3-way Foley may be placed, but is of no benefit for patients treated as outpatients).

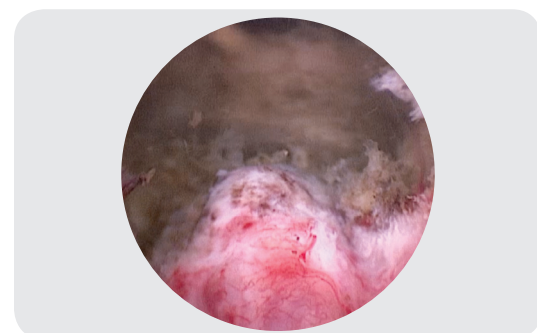


Figure 13 - Open fossa

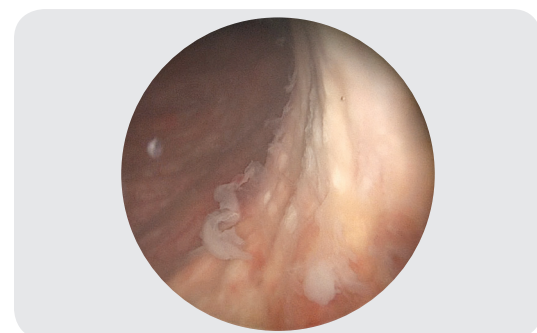


Figure 14 - Fossa 4 weeks post-op

A SYSTEMATIC APPROACH TO VAPORIZATION

As with all surgical procedures, there are a number of ways to successfully treat BPH using the GreenLight XPS Laser Therapy System. However one chooses to systematically approach a given procedure, adherence to the basic principles outlined below is the cornerstone to repeatable surgical success and patient satisfaction.

- | | | |
|-------------------------------------|---|--|
| <input checked="" type="checkbox"/> | 1 | Atraumatically introduce continuous-flow cystoscope. |
| <input checked="" type="checkbox"/> | 2 | Identify landmarks and rule out other pathology. |
| <input checked="" type="checkbox"/> | 3 | Introduce laser fiber and confirm irrigation of scope and fiber. |
| <input checked="" type="checkbox"/> | 4 | Activate aiming beam by putting the laser on ready. |
| <input checked="" type="checkbox"/> | 5 | Create a working channel using low energy (80–120W), starting proximal to distal. |
| <input checked="" type="checkbox"/> | 6 | Start at 5 and 7 o'clock, and create grooves at these locations from the bladder neck back towards the apex. |
| <input checked="" type="checkbox"/> | 7 | Vaporize systematically until all obstructing tissue is removed. |
| <input checked="" type="checkbox"/> | 8 | Titrate energy as needed for efficient vaporization. |
| <input checked="" type="checkbox"/> | 9 | Confirm the endpoint and preservation of key landmarks. |

The GreenLight™ Laser System is intended for incision/excision, vaporization, ablation, hemostasis and coagulation of soft tissue, including photoselective vaporization of the prostate for benign prostatic hyperplasia (BPH). The laser system is contraindicated for patients who: are contraindicated for surgery, contraindicated where appropriate anesthesia is contraindicated by patient history, have calcified tissue, require hemostasis in >2mm vessels, have uncontrolled bleeding disorders, have prostate cancer, have acute urinary tract infection (UTI) or severe urethral stricture. Possible risks and complications include, but are not limited to, irritative symptoms (dysuria, urgency, frequency), retrograde ejaculation, urinary incontinence, erectile dysfunction, hematuria - gross, UTI, bladder neck contracture/outlet obstruct, urinary retention, perforation - prostate, urethral stricture.

Prior to using these devices, please review the Operator's Manual and any accompanying instructions for use for a complete listing of indications, contraindications, warnings, precautions and potential adverse events.

CAUTION: Federal (U.S.) Law restricts this device to sale by or on the order of a physician.
CAUTION: The law restricts this device to sale by or on the order of a physician.

All trademarks are the property of their respective owners.

**Boston
Scientific**
Advancing science for life™

Manufactured by AMS, a fully owned subsidiary of Boston Scientific, 300 Boston Scientific Way, Marlborough, MA 01752

www.bostonscientific.com

© 2016 Boston Scientific Corporation or its affiliates. All rights reserved.

URO-392607-AA JUL 2016