

# 50W HoLEP WITH AURIGA XL FEATURING THE EN-BLOC NO-TOUCH TECHNIQUE

INNOVATIVE CONCEPTS OPTIMIZING  
ENDOSCOPIC LASER ENUCLEATION  
OF THE PROSTATIC ADENOMA



**Cesare Marco Scoffone, MD**

Department of Urology,  
Cottolengo Hospital of Torino, Italy

# 50W HoLEP WITH AURIGA XL FEATURING THE EN-BLOC NO-TOUCH TECHNIQUE

## INNOVATIVE CONCEPTS OPTIMIZING ENDOSCOPIC LASER ENUCLEATION OF THE PROSTATIC ADENOMA

### 1. Dr. Scoffone, overall experience

Dr. Cesare Marco Scoffone has been working for more than 20 years in the Department of Urology of the University Hospital, the University Hospital of Orbassano (Torino, Italy) (Fig. 1), especially developing a wide and solid experience in uro-oncologic and reconstructive surgery, retrograde ureteroscopic and percutaneous treatment of urolithiasis, and mininvasive approaches to benign prostatic obstruction.

Since 2010 he has been the Chief of the Department of Urology of the Cottolengo Hospital of Torino (Italy) (Fig. 2). His personal case series include thousands of open, laparoscopic and endoscopic procedures performed as first surgeon in all urologic fields, and during the last ten years he has often been invited for Live Surgeries (mainly RIRS, ECIRS, bipolar TURP, HoLEP) all over the world.

He is author of many publications, guidelines, book chapters (including one in the 4<sup>th</sup> edition of the Smith's Textbook of Endourology on ECIRS) and didactic videos (also for ESU/Surgery in Motion), editor of a Springer book on ECIRS (Fig. 3), reviewer for many international journals, member of a number of national and international urological societies, consultant for various companies, part of the EAU, CIE and SIU Faculties, and Chairman of the Technology and Training in Endourology Congress in Torino (7<sup>th</sup> edition in 2017) (Fig. 4).



Figure 1 – University Hospital of Orbassano (Torino), Italy



Figure 2 – Cottolengo Hospital of Torino, Italy




Figure 3 – Book published by Springer on ECIRS



Figure 4 – Announcement of the 7<sup>th</sup> Technology and Training in Endourology 2017

## 2. Dr. Scoffone, experience with HoLEP and his personal modification of the traditional technique into the en-bloc no-touch approach

Dr. Scoffone started his experience with HoLEP in 2011, applying the traditional three-lobe technique described by Peter Gilling using a 100W laser device (settings: 2J/50 Hz).

Dr. Scoffone encountered some critical and difficult steps during his learning curve, including:

- A demanding search of the right plane between adenoma and prostatic capsule for three times, at 5, 7 and 12 o'clock
- Difficult performance of an adequate 12 o'clock incision
- Bothersome rotation of the single lobes once detached one from another
- Laborious preservation of the mucosal sphincteric strip from 10 to 2 o'clock (see EMJ Urol 2015;3(2):1-6) (Fig. 5)

As a result he progressively modified the traditional endoscopic approach into the so-called en-bloc no-touch HoLEP, published on WJUrol 2016; 34(8):1175-81 (Fig. 6).

### Why en-bloc?

Because the adenoma is enucleated in one single horseshoe-like piece (Fig. 7) and sometimes in a whole piece with the intact urethra inside, as we will describe later, respecting all the anatomic details.

### Why no-touch?

Because it largely, but not exclusively, exploits the vaporizing plasma and vapour bubble generated around the tip of the laser fiber, firing at a short distance from the tissue (Fig. 8a). The connective fibers are put in tension gently raising the adenoma from the capsular plane with the beak of the endoscope, creating a sort of dihedral angle where vision is optimal. The energy dissolving such fibers is not directly supplied to the capsule, thus reducing postoperative dysuria (Fig. 8b).

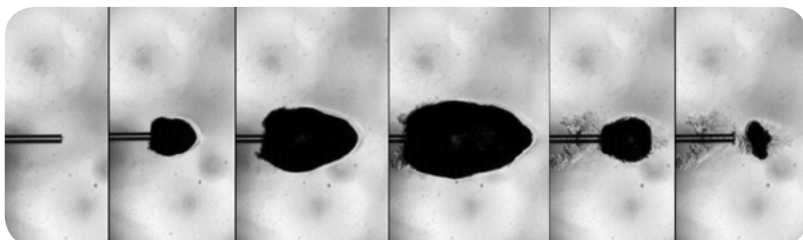


Figure 8a – Drawing of the plasma and vapour bubble on the tip of the laser fiber

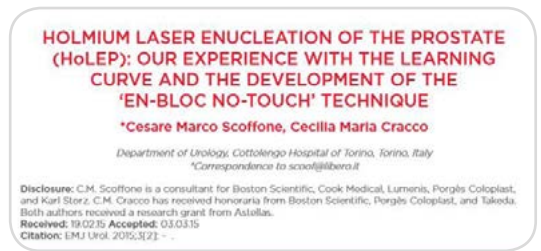

Figure 5 – EMJ Urol 2015




Figure 6 – WJUrol 2016




Figure 7 – Plasticine model of the enucleated horseshoe-like adenoma (red rectangle, behind) and remaining prostatic capsule (in front), red = right lobe, green = left lobe, yellow = median lobe

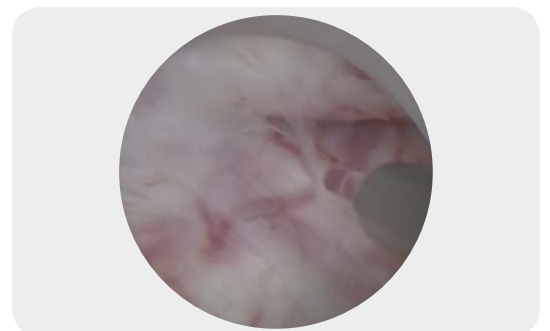

Figure 8b – Intraoperative no-touch approach during HoLEP

### 3. From high-power to low-power en-bloc no-touch HoLEP: less is more?<sup>1</sup>

In 2015 Dr. Scoffone started decreasing the amount of energy delivered to the capsular plane during the enucleation phase, with the aim of minimizing post-operative dysuria (9-59% according to the literature, about 10% in our series). This also possibly correlated with a reduction in energy consumption. He maintained the same energy setting (2 J) but progressively reduced the frequency setting (from 50Hz down to 25 Hz).

Having realized that safety and efficacy of the low-power HoLEP were unchanged, in 2016 he started using the 50W Auriga XL device, energy setting 2.2 J, frequency setting 18 Hz, long pulse length.

Currently he has performed about 200 low-power en-bloc no-touch HoLEPs, with the same safety and efficacy of the high-power procedure.

In particular, enucleation time and efficiency were unchanged, as were the negligible complication rates. On the other hand, the amount of energy employed for enucleation was significantly reduced, from about 85 kJ to about 50 kJ per procedure, as well as the kJ/g of adenoma ratio.

Postoperative dysuria (at 10%) displayed a reduction in intensity and duration. Further clinical evaluations are ongoing and encouraging (EAU 2017 and AUA 2017 published poster abstracts).

### 4. Description of the low-power en-bloc no-touch HoLEP step-by-step

#### a. Patient selection

Any patient suffering from BPO (any prostate volume, normal PSA, Q<sub>max</sub> <15 ml/sec, IPSS >10, PVR <300 cc) can undergo HoLEP (see also the latest EAU guidelines).

For the first HoLEP cases it is better to choose medium-sized prostates (about 50 grams of estimated weight, with no particular events in the medical history such as prostate biopsies, past acute prostatitis or suspect prostate cancer).

#### b. Patient work-up

- Medical history and normal DRE apart from prostate enlargement
- IPSS (+/- IIEF-5) questionnaire
- Voiding diary
- Uroflowmetry
- Blood exams (with renal function and PSA)
- Urinalysis and urine culture (+/- cytology)
- Urethrocytoscopy (for prostate morphology and shape evaluation)
- Imaging of the lower and upper urinary tract (with post-void residual evaluation)
- Urodynamic investigation optional but fundamental in selected cases

1. Postoperative dysuria after high- and low-power en-bloc no-touch HoLEP, Eur Urol Suppl 2017; 16(3);e500

### c. Patient's preoperative preparation

- Hold antiaggregants whenever possible in consultation with cardiologist
- Usually stop anticoagulants and substitute them, always in consultation with cardiologist
- Preoperative enema
- DVT prophylaxis according to the hospital protocol
- Broad spectrum antibiotics according to the hospital protocol

### d. OR equipment

- Adequate operating table with padded leg stirrups
- Comfortable rolling chair to perform the procedure sitting
- Sterile draping with bags for fluid irrigation retrieval and fluid aspirator (*Fig. 9*)
- Irrigation device with adjustable height and warming option (no heating during the enucleation phase) (*Fig. 10*)
- Saline irrigation bags with large tubing
- 26F Storz continuous flow resectoscope with separate laser bridge and working element with bipolar loop, visual obturator, 12° optics (*Fig. 11*)
- 600µm LightTrail fiber (*Fig. 12*)
- HD fixed camera and video network
- Laser device (50W Auriga XL) (*Fig. 13*)
- Mechanical morcellator with 26F rigid nephroscope
- 20Ch 3-ways Tieman-tip silicon catheter (30-50 ml vs 50-80 ml vs 80-120 ml ballon inflation)

### e. Anaesthesia

The choice is made by the anaesthesiologist, usually spinal but also general, also with laryngeal mask.

### f. Patient's postoperative care

- Saline continuous irrigation and i.v. hydration with gastric protection until the morning after surgery
- Bedrest until the following morning
- Gradual hydration and light dinner after surgery
- Catheter removal on postoperative day 2 or 3
- Blood count the day after surgery



Figure 9 – Sterile draping

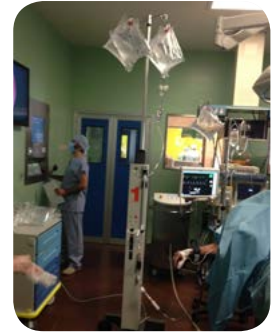


Figure 10 – Irrigation and warming device

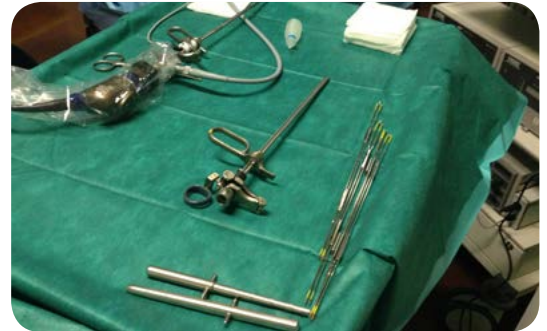


Figure 11 – Endoscope, working element, camera



Figure 12 – Laser fiber



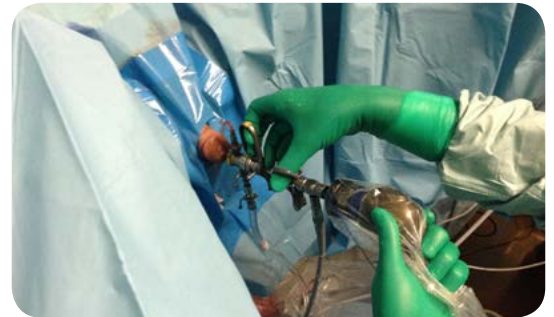
Figure 13 – 50W Auriga XL Holmium laser device

**g. HoLEP fundamentals**

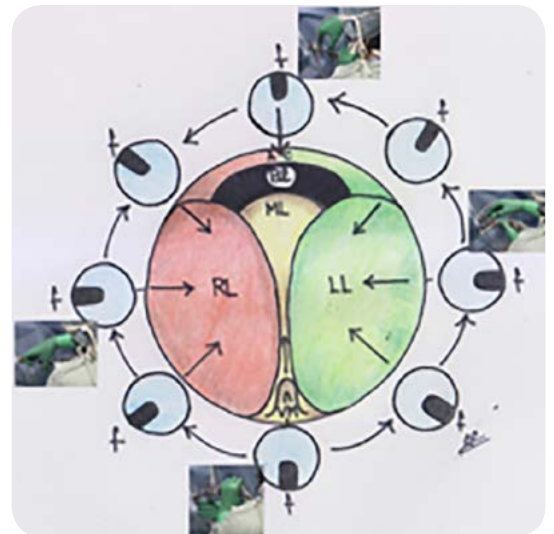
- **Enucleation phase:** control laser settings, check the integrity of the laser fiber; don't use heated irrigation; put the irrigation bags about 40-50 cm above the operating table; follow a standardized step-by-step approach with progressive and targeted haemostasis; avoid marked angulations of the endoscope in order to prevent inadvertent traction on the external sphincter; be systematic; always be aware of where you are.
- **Morcellation phase:** control the correct functioning before surgery; renew blades in time; a dedicated pump is more reliable than the general vacuum of the OR; fill the bladder maximally elevating the irrigation bags (heating allowed); stay in the middle of the bladder lumen away from the walls; start covering the blades with the adenoma aspirating it with the first step of the pedal, then go on with morcellation, without moving the instrument; don't chase small pieces of adenoma within the bladder lumen.

**h. Scope handling and maneuvering**

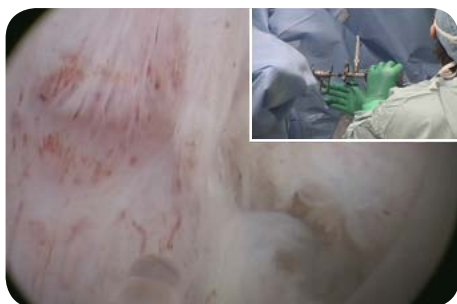- Hold the movement of the laser fiber with the dominant hand
- Hold the camera with the non-dominant hand (*Fig. 14a*)
- Always try to keep the laser fiber perpendicular to the plane between adenoma and capsule, rotating the scope in any quarter of the circumference to enucleate, with a specular position of the dominant hand (*Fig. 14b*): at 6 o'clock above the veru montanum (*Fig. 15*), from 6 to 3 o'clock enucleating the lower part of the left lobe (*Fig. 16*), from 3 to 12 o'clock enucleating the upper part of the left lobe (*Fig. 17*), at 12 o'clock working on the midline of the anterior commissure (*Fig. 18*), from 6 to 9 o'clock enucleating the lower part of the right lobe (*Fig. 19*), from 9 to 12 o'clock enucleating the upper part of the right lobe (*Fig. 20*).



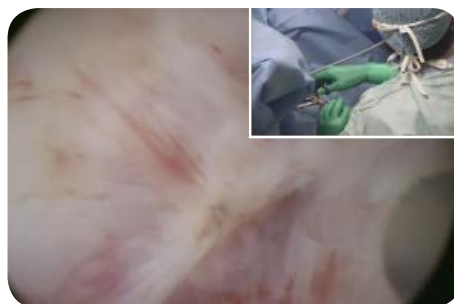*Figure 14a – Scope handling*



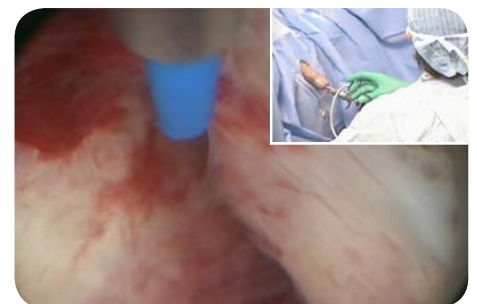*Figure 14b – Schematic drawing of the specular position of laser fiber and dominant hand, in the four quarters of the adenoma. RL = right lobe, LL = left lobe, ML = median lobe, VM = veru montanum, BI = bladder, AC = anterior commissure, f = laser fiber*



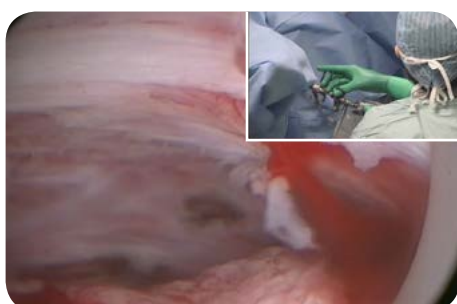*Figure 15 – 6 o'clock*



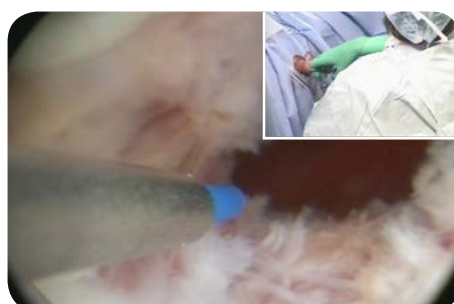
*Figure 16 – 6-3 o'clock*



*Figure 17 – 3-12 o'clock*



*Figure 18 – 12 o'clock*



*Figure 19 – 6-9 o'clock*



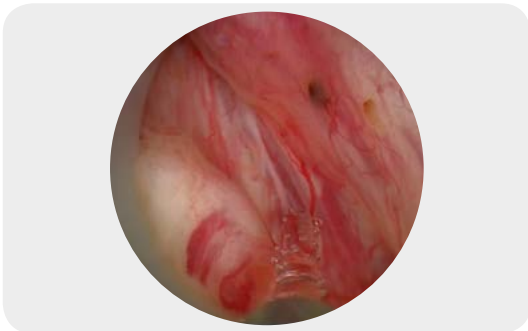*Figure 20 – 9-12 o'clock*

- In order to avoid the risk of inadvertent traction of the external sphincter do not force scope movements, be gentle, delicately lift or move the adenoma towards the prostatic urethra rather than pushing it forward, towards the bladder neck.

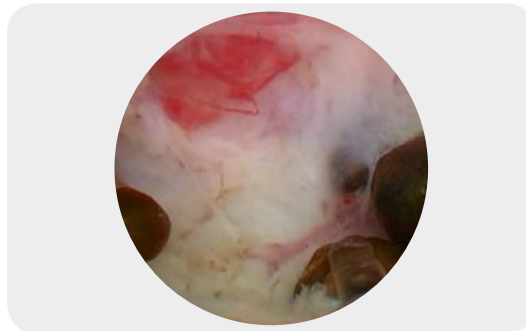#### **i. Step-by-step enucleation phase of the en-bloc technique**

- **Step 1: Exposing the correct plan for enucleation at the apex of the left lobe, once for all**

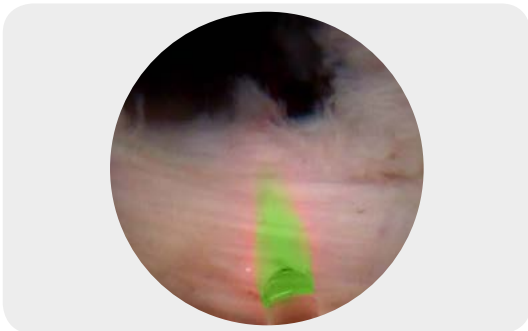
Adenoma enucleation begins at the apex of the left lobe, lateral to the veru montanum, where the opening of the prostatic ducts can be seen (Fig. 21). The correct cleavage plane between adenoma and capsule is prominent at this site independently from the size of the adenoma, and particularly easy to identify once and for all, reducing the risk of mistaking it and creating mismatching planes (Fig. 22). This incision between median and left lobe is retrogradely deepened and widened towards the bladder neck, which can be fully preserved, in front of the left ureteral orifice (Fig. 23), while ascending from the apex towards the bladder neck from 5 to 3 o'clock in a side-to-side manner (Fig. 24).



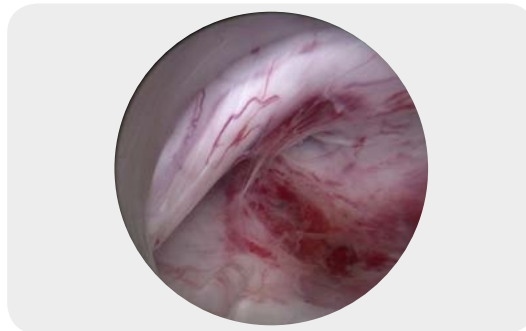
*Figure 21 – Initial left apical incision*



*Figure 22 – Identification of the right plane*



*Figure 23 – Retrograde 5 o'clock incision reaching the bladder neck*



*Figure 24 – Ascending towards the bladder neck from 5 to 3 o'clock*

- **Step 2: complete enucleation of the left lobe, overpassing the anterior commissure towards the right side**

The detachment of the left lobe is completed from 3 to 12 o'clock in the same manner (Fig. 25), behind the external sphincter and again until reaching the bladder neck (Fig. 26), always following the identified capsular plane without ever leaving it, thus avoiding the risk of incomplete removal of the adenoma or capsular perforation. At this point enucleation goes on towards the right side, from 12 to 9 o'clock (Fig. 27-28).

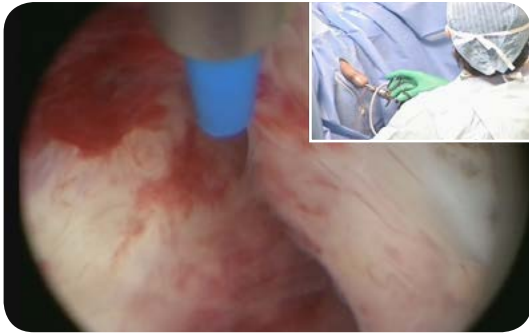

Figure 25 – Ascending from 3 to 12 o'clock

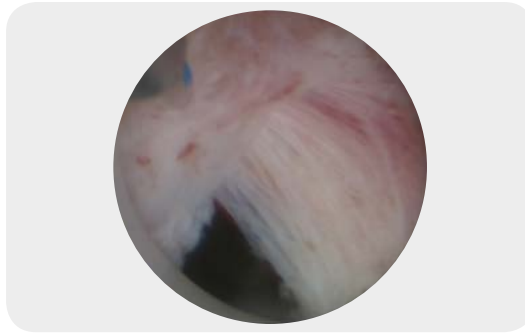


Figure 26 – Reaching the bladder neck at 10 o'clock

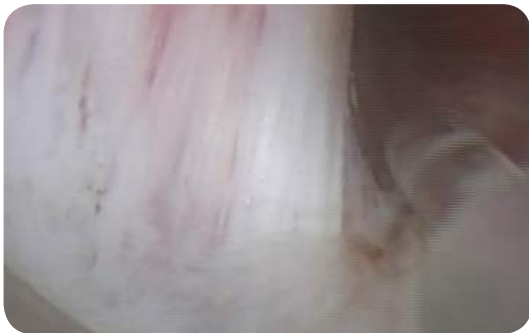

Figure 27 – Fibers of the bladder neck at 12 o'clock

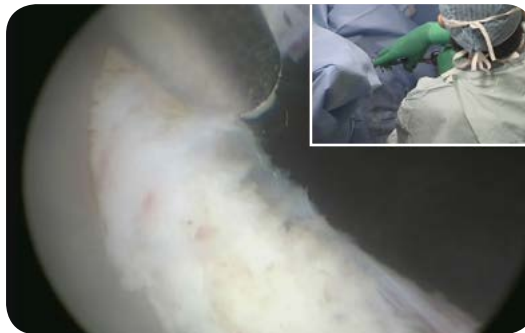

Figure 28 – Descending from 12 towards 9 o'clock



- **Step 3: back to the initial apical incision, completing the en-bloc enucleation with the dissection of the median and right lobes**

Going back to the initial left apical incision the mucosa is horizontally incised above the veru montanum (Fig. 29), reaching the apex of the right lobe; there the mucosa is incised within the cleft on the right side of the veru montanum (Fig. 30). Median and right lobes are then isolated together exactly as described for the left lobe, ascending from 7 to 9 o'clock (Fig. 31) and towards the bladder neck (Fig. 32), and then from 9 to 12 o'clock (Fig. 33), reaching from below the already detached cranial part of the right lobe (Fig. 34). In this way, a final horseshoe-like enucleated adenoma is obtained, with the left lobe on one side and the median and right lobes on the other side, cranially connected by the anterior commissure, still fixed within the prostatic fossa.

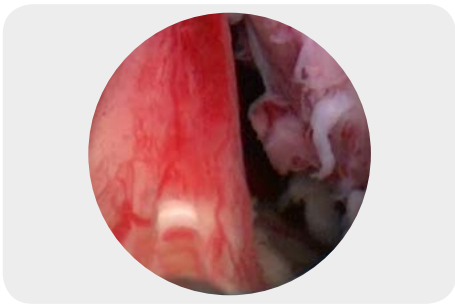


Figure 29 – Transverse incision above the veru montanum, median lobe

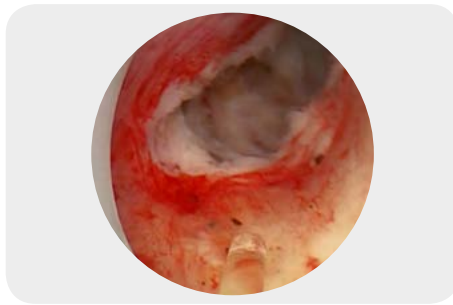


Figure 30 – Right apical incision

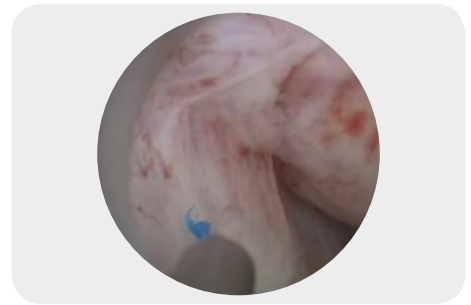

Figure 31 – Ascending from 7 to 9 o'clock

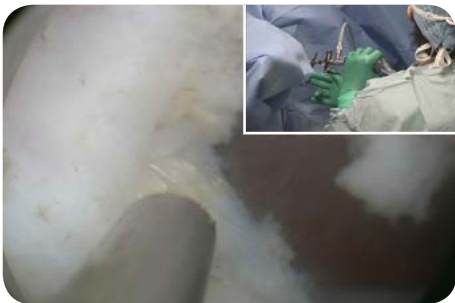

Figure 32 – Reaching the bladder neck at 8 o'clock

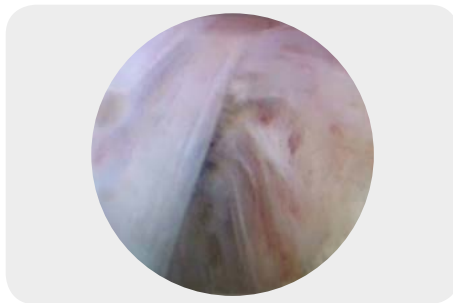


Figure 33 – Ascending from 9 to 12 o'clock

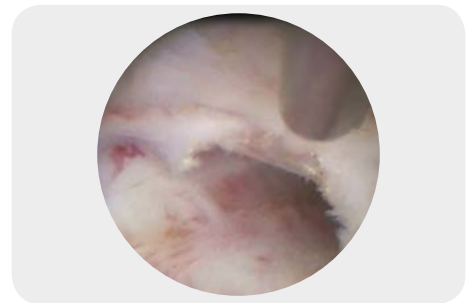


Figure 34 – Reaching from below the already detached adenoma

• **Step 4: final incision of the parasphincteric anterior mucosal strip**

The en-bloc enucleated adenoma (*steps 1 and 2, Fig. 35; step 3, Fig. 36*) is now completely isolated in one piece, but still fixed from 10 to 2 o'clock in its downward part by a residual fan-shaped urothelial strip (*Fig. 37*), which has to be incised without damaging the external sphincter. A reverse V-shaped incision is carried out on the mucosa of the lateral lobes at least 1 cm away from the sphincter (*Fig. 38-39*), converging at 12 o'clock as proximal as possible to the bladder neck (*Fig. 40*), leaving a consistent residual mucosal flap (*Fig. 41*). Now the completely enucleated adenoma can be pushed inside the bladder lumen for morcellation.

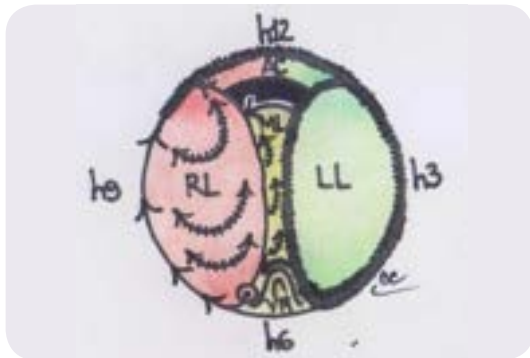


Figure 35 – Schematic drawing of steps 1 and 2 of the enucleation

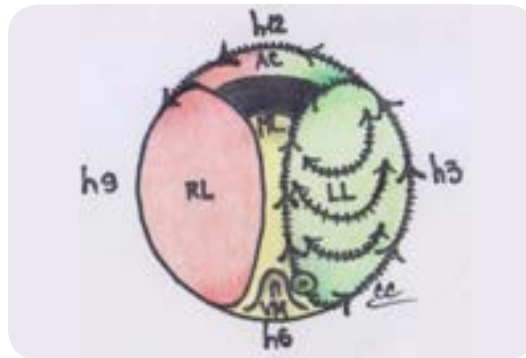


Figure 36 – Schematic drawing of step 3 of the enucleation (RL = right lobe, LL = left lobe, ML = median lobe, AC = anterior commissure, VM = veru montanum)

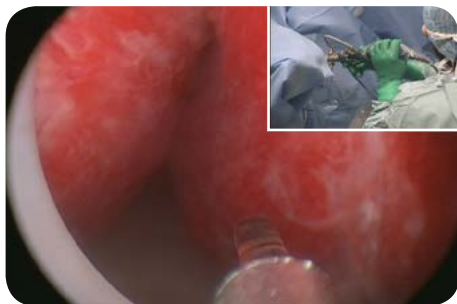


Figure 37 – Fan-shaped mucosa from 10 to 2 o'clock, final vision after enucleation

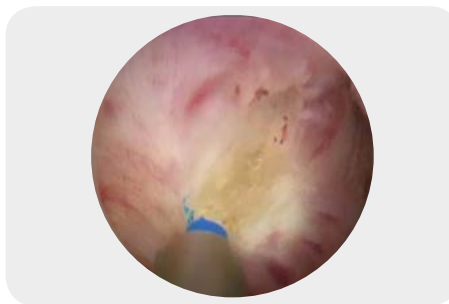


Figure 38 – Right branch of the reverse V incision of the mucosa

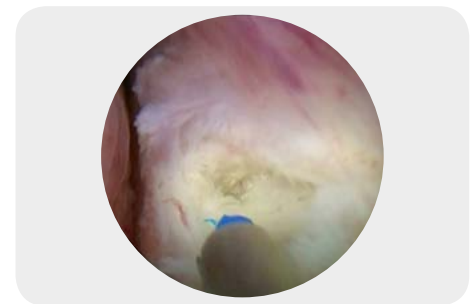


Figure 39 – Left branch of the reverse V incision of the mucosa

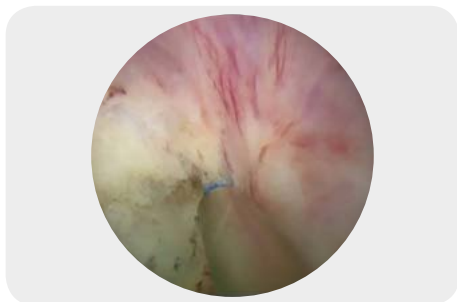


Figure 40 – 12 o'clock incision, apex of the reverse V incision of the mucosa



Figure 41 – Drawing of the reverse V incision of the sphincteric mucosa (RL = right lobe, LL = left lobe)

A series of horizontal dotted lines for writing notes, spanning the width of the page.

