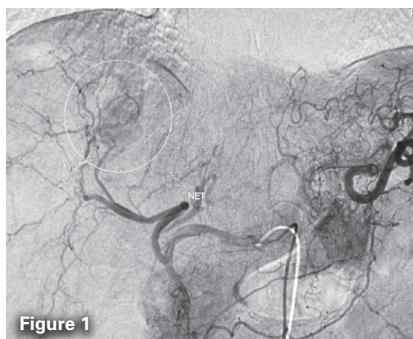

CASE STUDY

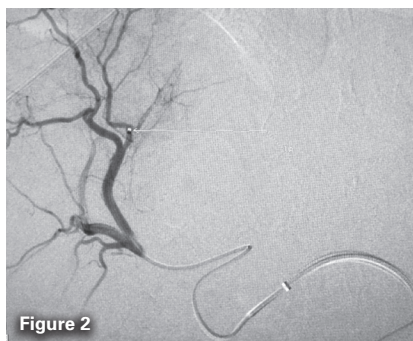Share Your Direxion Story

Tracking in Unfavorable Anatomy for Liver Cancer

Ilan Rzadkowolsky-Raoli, MD – Palmetto General Hospital, Hialeah, Florida

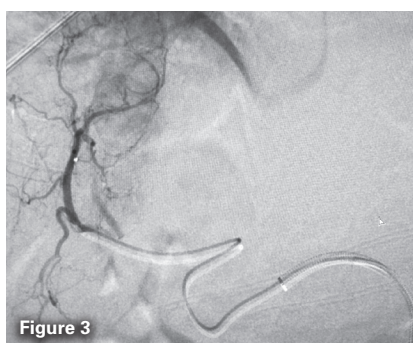

A 57-year-old woman with a history of primary neuroendocrine tumor of the colon was treated with hemicolectomy. A metastatic lesion straddling segments 7 and 8 of the liver had been previously treated with percutaneous thermal ablation (both radiofrequency and microwave) with partial success. The patient presented for bland embolization. A celiac angiogram showed faint tumor blush near the dome of the liver, with hepatic arterial supply derived from both the segment 7 and 8 branches (Figure 1).

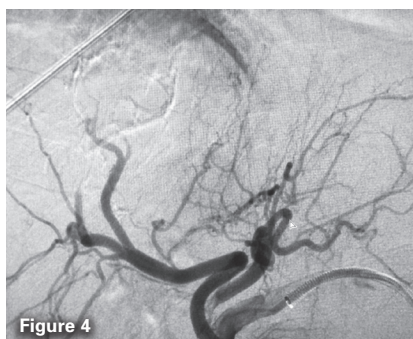

There was severe bend of the proper hepatic artery after the gastroduodenal artery and near 180° angulation of the right hepatic artery distal to the left hepatic artery takeoff. **This second flexure could not be crossed with a conventional microcatheter without buckling the support catheter.** Embolization of the medial branch was performed (Figure 2).

“ This singular tool allowed me to successfully complete therapy where other microcatheters failed. ”



This position was gained using the Direxion Microcatheter, which did not yield trackability despite the unfavorable anatomical bend of the proximal right hepatic artery. A superselctive angiogram from the segment 7 hepatic artery showed tumor blush medially, and preparation was made for embolization (Figure 3).



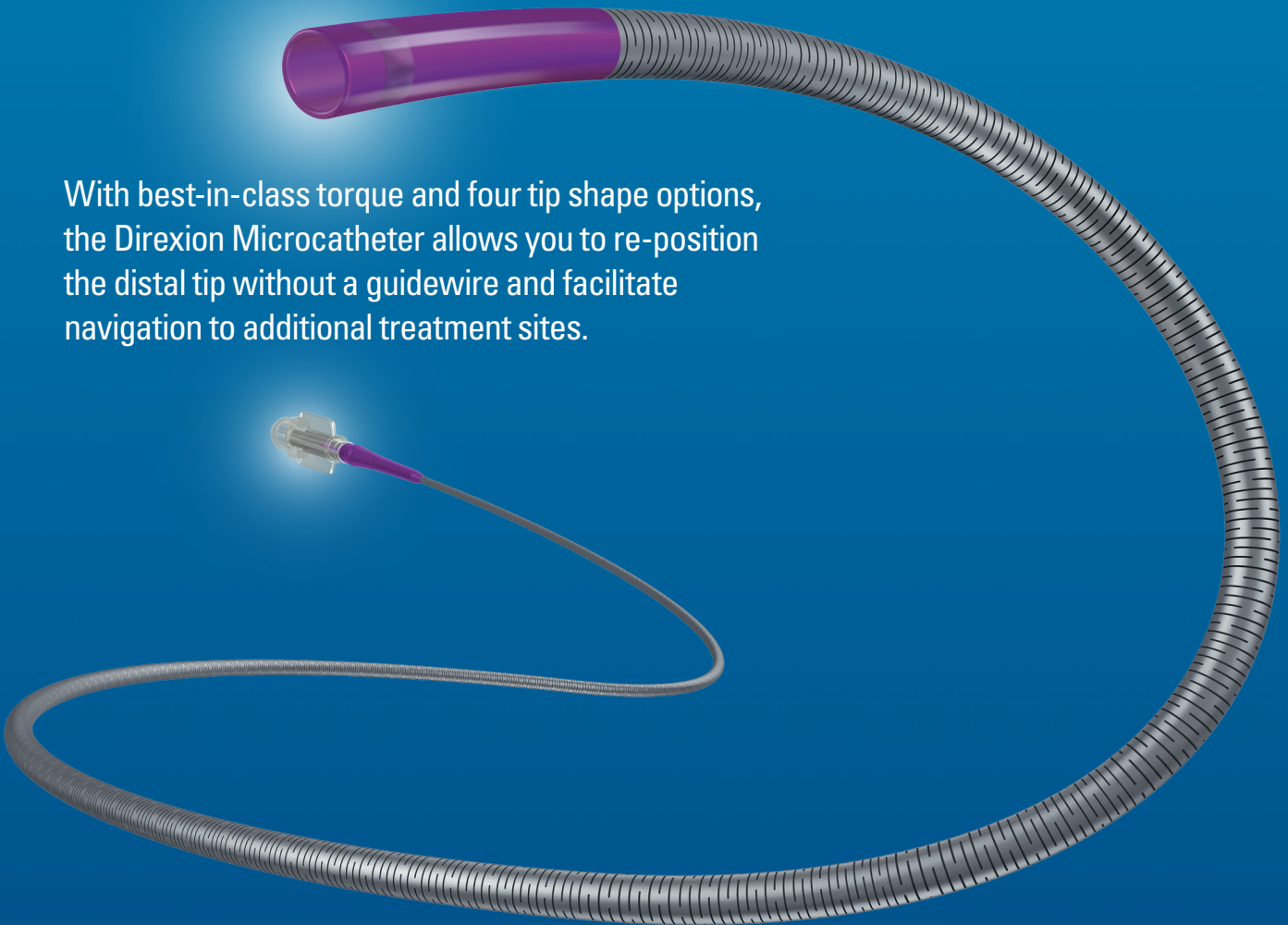
Again, this location was attained despite power-bleeding anatomy. Embolization of the tumor-feeding arterial branches was successful, with stasis of contrast and cast of vessels (Figure 4).

The case in this article illustrates the capabilities of the Direxion Microcatheter to outperform most other examples of its class. With its **unmatched torqueability and trackability as a consequence of its unique shaft design**, as well as its slick feel due to its lubricious outer coating, the Direxion is rapidly becoming my first choice for slightly challenging anatomy. Add to this mix the array of tip configurations and both high-flow and low-profile diameters, and there is no location that cancer is safe!

DIREXION™ Torqueable Microcatheter

REPOSITION WITHOUT THE WIRE

With best-in-class torque and four tip shape options, the Direxion Microcatheter allows you to re-position the distal tip without a guidewire and facilitate navigation to additional treatment sites.



Share Your Direxion Story

www.bostonscientific.com/Direxion

DIREXION™ DIREXION HI-FLO™

CAUTION: Federal law (USA) restricts this device to sale by or on the order of a physician. Rx only. Prior to use, please see the complete "Directions for Use" for more information on Indications, Contraindications, Warnings, Precautions, Adverse Events, and Operator's Instructions.

INTENDED USE/INDICATIONS FOR USE: The Direxion and Direxion HI-FLO Torqueable Microcatheters are intended for peripheral vascular use. The pre-loaded Fathom and Transend Guidewires can be used to selectively introduce and position the microcatheter in the peripheral vasculature. The microcatheter can be used for controlled and selective infusion of diagnostic, embolic, or therapeutic materials into the vessel. **CONTRAINDICATIONS:** None known. **WARNINGS:** • Never advance or withdraw an intravascular device against resistance until the cause of resistance is determined by fluoroscopy. Movement of the microcatheter or guidewire against resistance may result in damage or separation of the microcatheter or guidewire tip, or vessel perforation.

• This Direxion Microcatheter family is not intended for use in the coronary vasculature or neurovasculature. • The Direxion HI-FLO Microcatheter is not designed for the delivery of embolic coils. • Use of excessive force to manipulate the microcatheter against resistance can cause a fracture in the nitinol shaft. Take care not to over-torque the microcatheter, and to relieve any tension before withdrawal by rotating the microcatheter in the opposite direction. **PRECAUTIONS:** • This device should be used only by physicians thoroughly trained in percutaneous, intravascular techniques and procedures. • Do not introduce the microcatheter without guidewire support as this may cause damage to the proximal shaft of the catheter. • Because the microcatheter may be advanced into narrow sub-selective vasculature, repeatedly assure that the microcatheter has not been advanced so far as to interfere with its removal. **ADVERSE EVENTS:** The Adverse Events include, but are not limited to: • Allergic reaction • Death • Embolism • Hemorrhage/Hematoma • Infection • Pseudoaneurysm • Stroke • Vascular thrombosis • Vessel occlusion • Vessel spasm • Vessel trauma (dissection, perforation, rupture) **REV AB**

Indications, contraindications, warnings and instructions for use can be found in the product labeling supplied with each device. Information for the use only in countries with applicable health authority product registrations. This material is not intended for use or distribution in France.

Direxion and HI-FLO are registered or unregistered trademarks of Boston Scientific Corporation or its affiliates. © 2015 Boston Scientific Corporation or its affiliates. All rights reserved. PI-195602-AB MAR2015