

COMPLEX ELECTROGRAMS ANNOTATION IN ACTIVATION MAPS: LUMIPOINT SOFTWARE TOOL IN A HYBRID AF REDO CASE

Physicians: M. Cireddu MD, S. Gulletta MD, P. Della Bella MD
Rhythmia Specialists: Fabio Crotta, Francesco Maddaluno
San Raffaele Hospital (Milan, Italy)

Hybrid ablation (a combination of thoracoscopic epicardial ablation and catheter ablation) has become a new technique for atrial fibrillation treatment. This combined approach seems to be a valid alternative to overcome the limitations of the epi- or endocardial ablation approach alone for persistent atrial fibrillation ablation. Estech COBRA Fusion was designed to form reliable epicardial transmural lesions and overcome the technical limitations of earlier devices for surgical AF treatment.

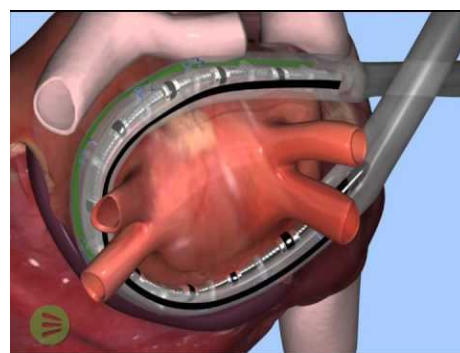


Figure 1: Cobra System for surgical AF treatment

CASE PRESENTATION

A 53 years old patient was referred to our Center for symptomatic persistent atrial fibrillation ablation (lasting 6 months). The arrhythmia history started in 2017 with an episode of persistent atrial fibrillation treated by electrical cardioversion and multiple atrial fibrillation recurrences despite antiarrhythmic drug therapy (AADS) (class IC and III). In November 2017 he underwent an ineffective atrial fibrillation ablation (PVI).

Patient was scheduled for surgical ablation with Cobra system in November 2018. After discharge the remote monitoring documented symptomatic atrial fibrillation episodes lasting more than 24 hours treated by cardioversion. As AF episodes continued, the patient underwent a staged catheter procedure 60 days after the surgical ablation to assess the durability of conduction block and to deliver additional ablation lesions in case of presence of conduction gap. At the hospital admission, the patient was in sinus rhythm, normal AV conduction. During the endocardial procedure an activation map of the left atrium substrate was performed with [RHYTHMIA HDx™ Mapping System](#) (Boston Scientific) and [IntellaMap™ Orion catheter](#). The ablation was performed with an impedance-based open-irrigated ablation catheter by delivering with 30W - 35W, 43°.

In the hospital The [LUMIPOINT™ Software Module](#) (Boston Scientific,) was recently introduced. This is an algorithm that analyzes the complete electrogram tracing to determine activity at each location. An additional mapping window, called “LUMIPOINT™ window, may be used to highlight regions of the map that activate within a certain time within the cycle. This feature may be used in a variety of ways to enhance interpretation of electrograms aiding comprehension of the map and therefore plan a more focused ablation strategy.

In addition, the [LUMIPOINT™ Module can enlighten different areas of interest based on electrogram morphology](#). This feature has been implemented for Split Potentials (SPLIT tool) and for fragmented potentials area (COMPLEXITY tool).

After the complete map of the left atrium was collected in sinus rhythm, following our regular workflow, we started analyzing regular Rhythmia propagation based on the singular signal annotation. Endocardial map showed an incomplete box with gaps in the anterior and posterior lines (Figure 2)

LUMIPOINT™ analysis done with split potential tool confirmed the anterior line of block with a gap in the area close to the right superior pulmonary vein (Figure 3)

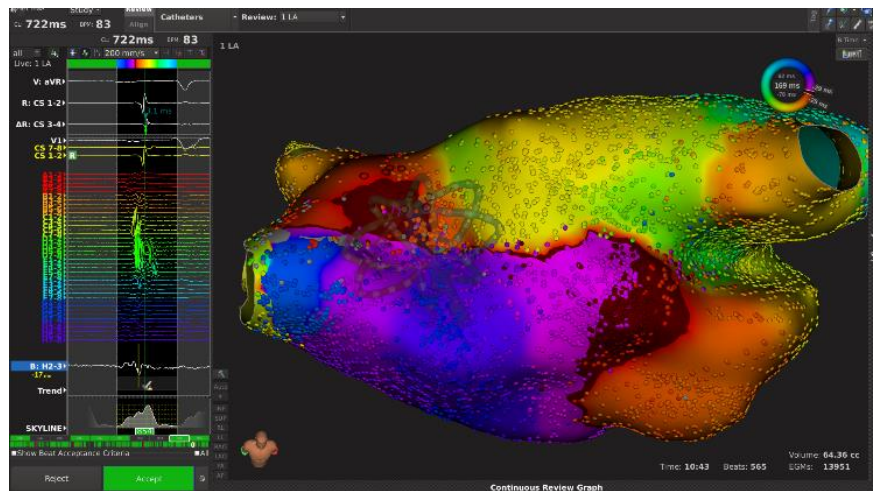


Figure 2: Activation map showing gap in the anterior line ablated in previous surgical procedure

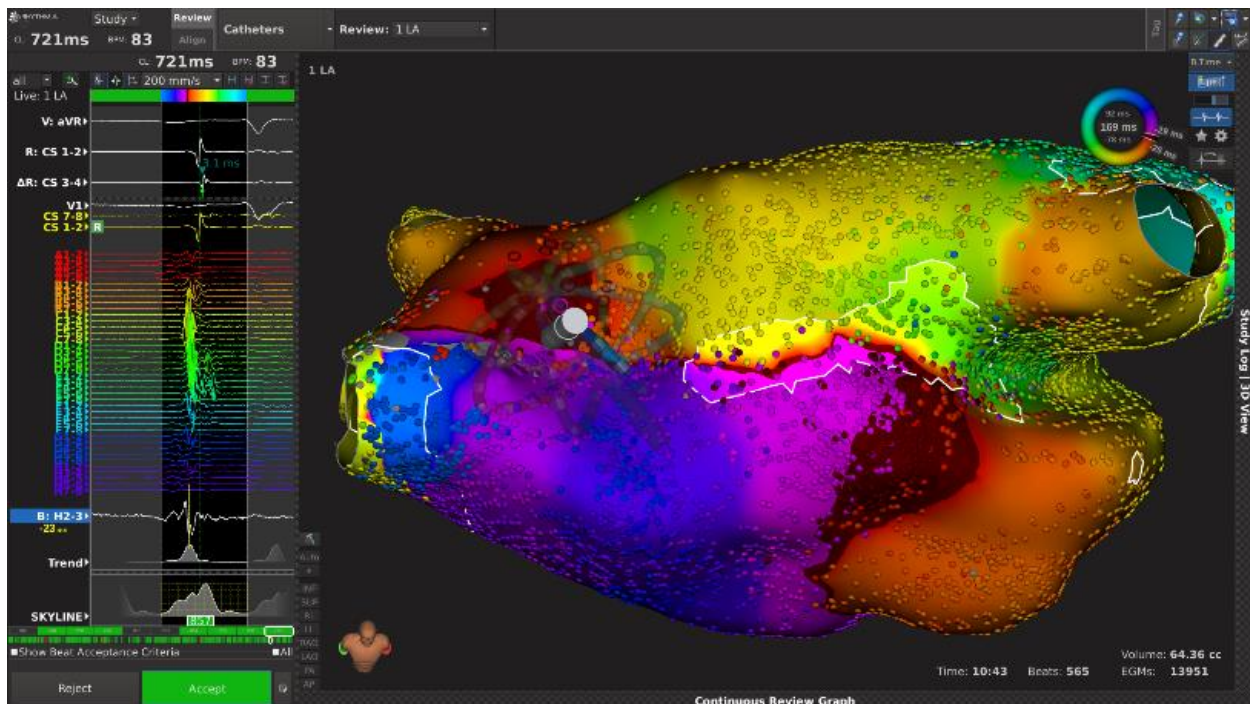


Figure 3: LUMIPOINT™ Split tool applied to the Anterior Line

An initial set of lesions was completed in the anterior line achieving the block in the anterior part on the area identified by LUMIPOINT™ analysis (Figure 4)

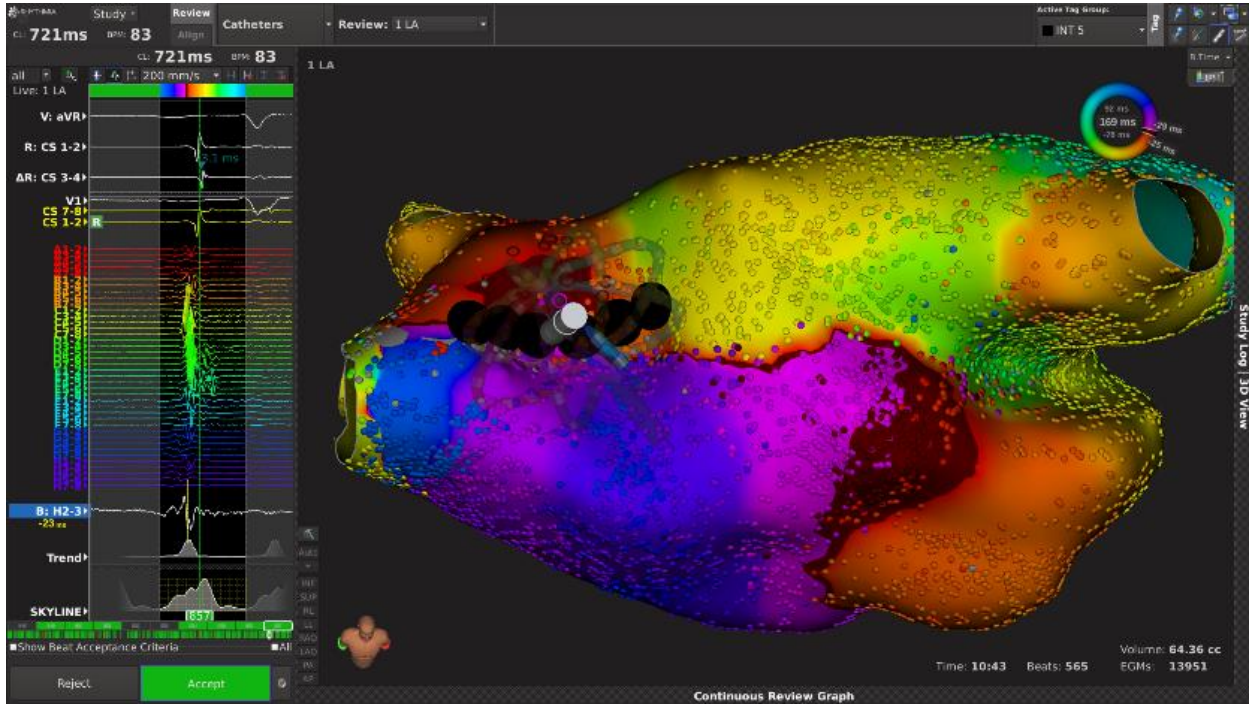


Figure 4: Ablation tags on the Anterior Line

At the same time regular Rhythmia propagation without manual EGM reannotation of the posterior wall showed a continuous propagation still ongoing (Figure 5):

- gap located posteriorly in a more antral part of the pulmonary veins
- second gap in the large area which seemed consistent on the posterior wall
- wavefronts collision in an area close to the right veins activated lately originated by gaps described above

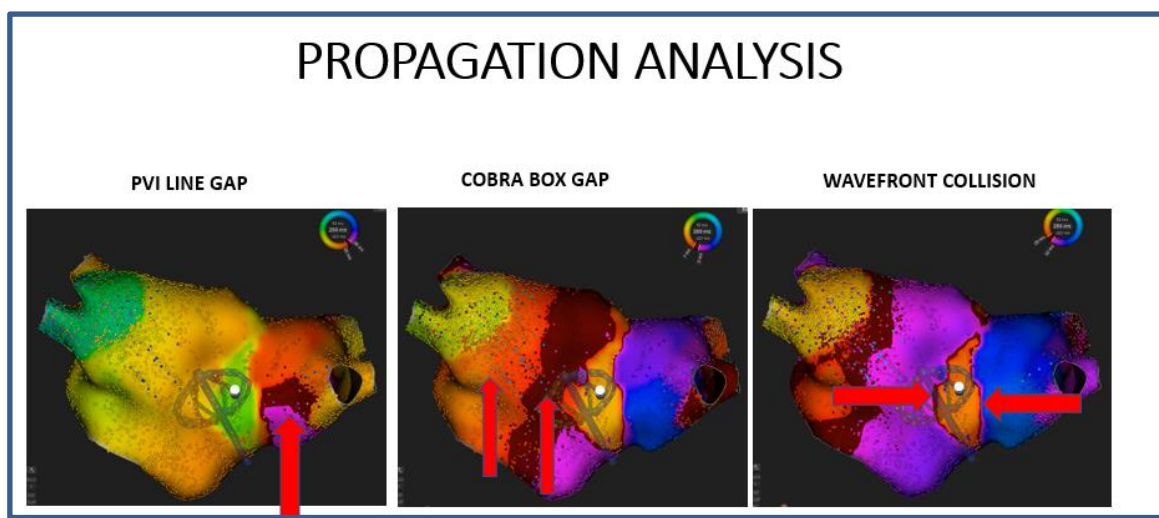


Figure 5: Regular Rhythmia Propagation analysis (no manual electrograms reannotation applied)

In order to go deeper in the analysis of the posterior wall, [LUMIPOINT™ software was used again and speeded up map analysis by focusing our attention on crucial electrograms.](#)

A very complex electrogram found by LUMIPOINT™ Complex Activation Tool (Figure 6) was located on the posterior aspect of the right inferior PV. By reviewing the EGM annotation it was clear that such a complex activation could not have been simplified by regular activation map annotation.

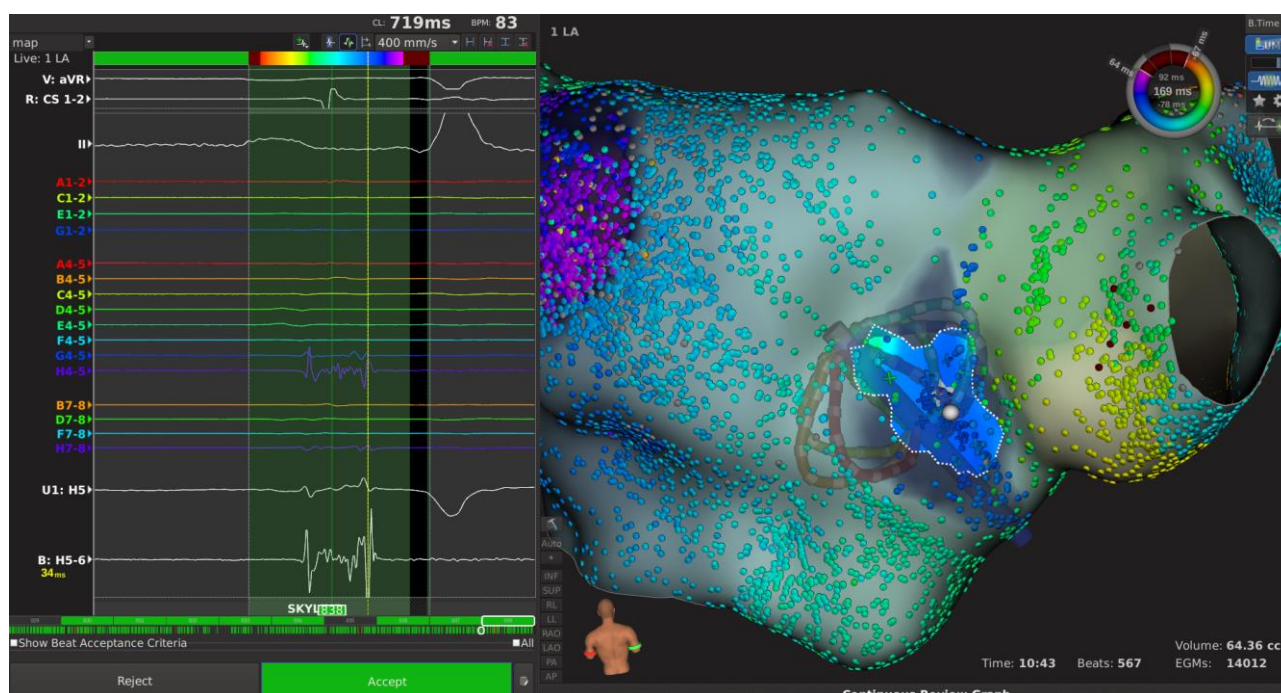


Figure 6: Long lasting EGM on the posterior wall found with COMPLEX EGM TOOL (number of peaks = 13)

As any automatic annotation system, this complex EGM was annotated in the last and highest voltage component, based on which playing regular propagation would have led the attention to an area of late activation. To avoid this, manual EGM review and reannotation would have been required, what could result in time consuming, until the first component had been identified. However, [by activating LUMIPOINT™, with a single click tool, we could easily unmask the complex activity EGMs leading to all the electrodes that could require more attention.](#)

[LUMIPOINT™ propagation tool, working independently on annotation, was even more powerful and easily unveiled complex activated areas without any manual check.](#) As shown in Figure 7, by playing LUMIPOINT™ propagation, all the initial components of this component were directly illuminated on the map what clarified the underlying mechanism of the tachycardia:

- gap in the PVI Line
- gap in the cobra box close to the antral part of the vein
- wavefront collision along Cobra line

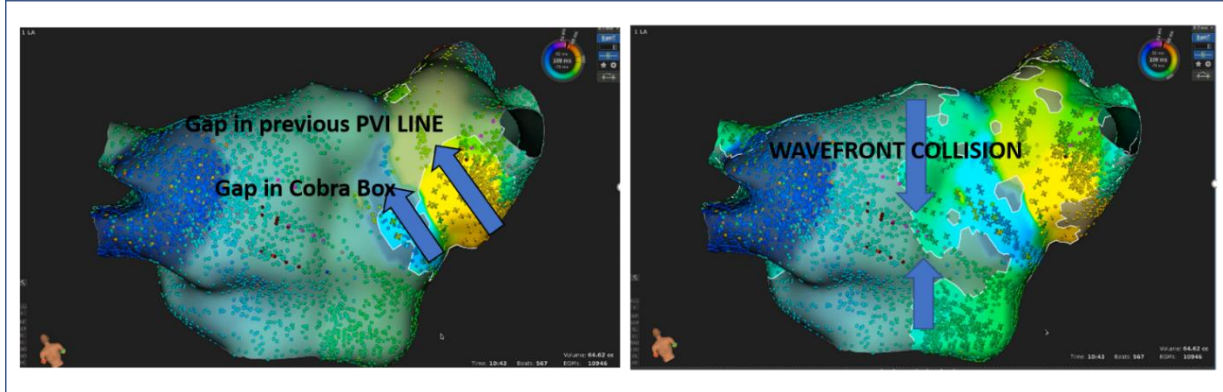


Figure 7: LUMIPOINT™ propagation interpretation. We concluded the posterior wall activation was generated from a single spot with a complex EGM easily unmasked by LUMIPOINT™ software. The remaining part of the line was activated from both sides starting from this gap though we realized the line was blocked

Abolition of this single spot in the posterior wall resulted in complete isolation of the posterior wall as showed in Figure 8.

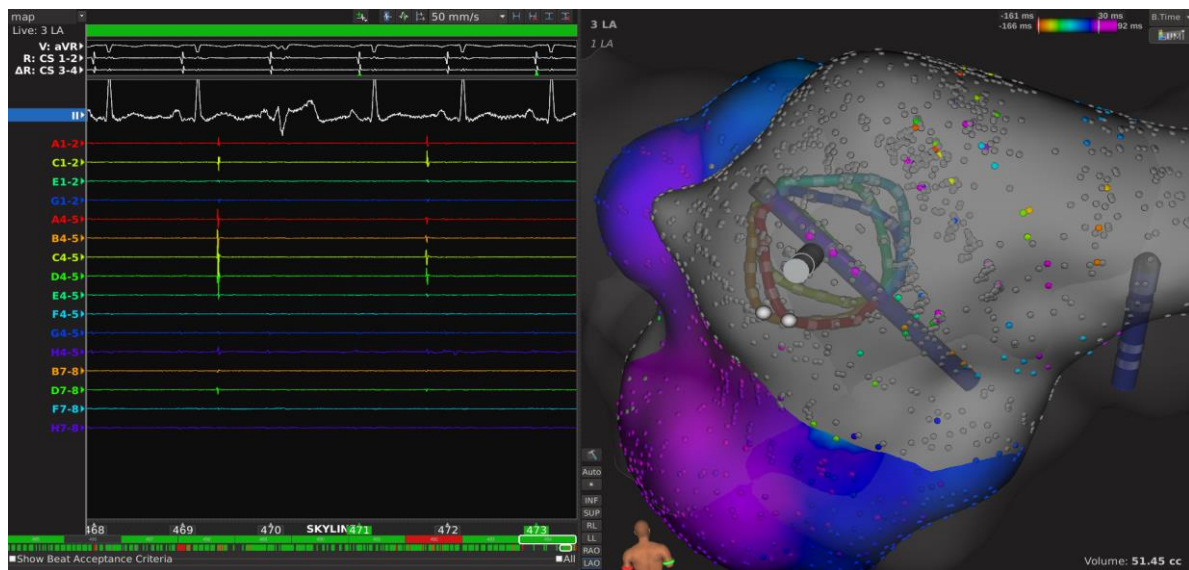


Figure 8: Dissociated potential inside the posterior wall “box” after EGM abolition

DISCUSSION

Bipolar electrogram annotation is an essential part of activation map building. Each annotation timing is translated into a color code where red stand for “early” into the mapping window and purple means “late”. Even dynamic propagation map relies on bipolar annotation to show the moving depolarization wavefront, making clear that choosing the wrong annotation for an electrogram can have deleterious effect on map interpretation and understanding. When a bipolar EGM has just one main deflection, annotating the bipolar peak corresponding to the maximum negative derivative of the unipolar signal provides the best choice for its activation timing.

However, when the electrogram has multiple and low amplitude components, the previous annotation algorithm is not that simple and information regarding the neighboring points becomes essential to choose the most reliable timing activation. In fact, by choosing one EGM component only as activation timing of the point might imply a loss of relevant information whose effect could impact the overall map interpretation.

The LUMIPOINT™ algorithm analyzes and highlights every single component of each EGM on the map that is consistent both in space and in timing regardless of the annotation of that point.

In our case, the propagation map showed a very late activated area at the antral part of the right inferior pulmonary vein and a breakthrough in the posterior line connecting the two inferior veins.

The electrograms at the posterior antra of the right inferior vein were all fragmented with multiple components and the reason for this area to be displayed as a very delayed activated region was related to the choice of annotating the last bipolar deflection.

LUMIPOINT™ software propagation highlighted every component showing the earliest engagement of this area (due to the contribution of the first deflections) **and its continuous activity throughout the electrogram duration.** This area turned out to be the gap in the Cobra box rather than the latest activated area in the posterior wall. For the same reason, LUMIPOINT™ propagation tool also easily unveiled the two fronts that activated the posterior wall colliding exactly on the line between the two inferior veins.

CONCLUSION

This case highlights the inherent limitations of activation map building when electrograms with multiple components are present.

The obligated choice of just one electrogram deflection as activation timing of the point, automatically implies loss of some information relative to the other not annotated components. Before LUMIPOINT™ introduction, the only approach to check and clarify all those complex electrograms would require manual review and reannotation and would result time consuming.

The new **LUMIPOINT™ algorithm brings that information back on the map by highlighting every consistent deflection of each electrogram making map interpretation faster and more reliable.**

REFERENCES

1. ESC Guidelines for the management of atrial fibrillation developed in collaboration with EACTS. European Heart Journal (2016) 37, 2893–2962.
2. 2012 HRS/EHRA/ECAS expert consensus statement on catheter and surgical ablation of atrial fibrillation: recommendations for patient selection, procedural techniques, patient management and follow-up, definitions, endpoints, and research trial design. J Interv Card Electrophysiol (2012) 33:171–257.

3. ESC Guidelines for the management of atrial fibrillation developed in collaboration with EACTS. *European Heart Journal*, Volume 37, Issue 38, 7 October 2016
4. 2017HRS/EHRA/ECAS/APHR/SOLAECE expert consensus statement on catheter and surgical ablation of atrial fibrillation. *Europace* (2017) 00, 1–160