

# Benign Biliary Strictures Managed With a WallFlex Biliary RX Fully Covered Metal Stent



CASE PRESENTED BY:

**JIN MING, M.D.**

Beijing Friendship Hospital  
Beijing, CHINA

## PATIENT HISTORY

A 73-year-old male was admitted with a chief complaint of jaundice for approximately ten days. He had a long history of alcohol intake. An abdominal CT scan revealed a dilated common bile duct, an enlarged pancreatic head and a granular calcification in the pancreas.

## PROCEDURE AND PATIENT OUTCOME

Upon examination he was jaundiced, underweight and malnourished. Laboratory investigations revealed obstructive jaundice. The tumor marker was normal. An endoscopic retrograde cholangiopancreatography (ERCP) revealed a mid-common bile duct stricture with proximal duct dilatation (**Figures 1-4**). A 6cm Fully Covered WallFlex® Biliary RX Metal Stent was placed. Cytology brush examination was negative. After seven months, a final ERCP revealed complete resolution of the stricture and the stents were removed (**Figures 5-8**).

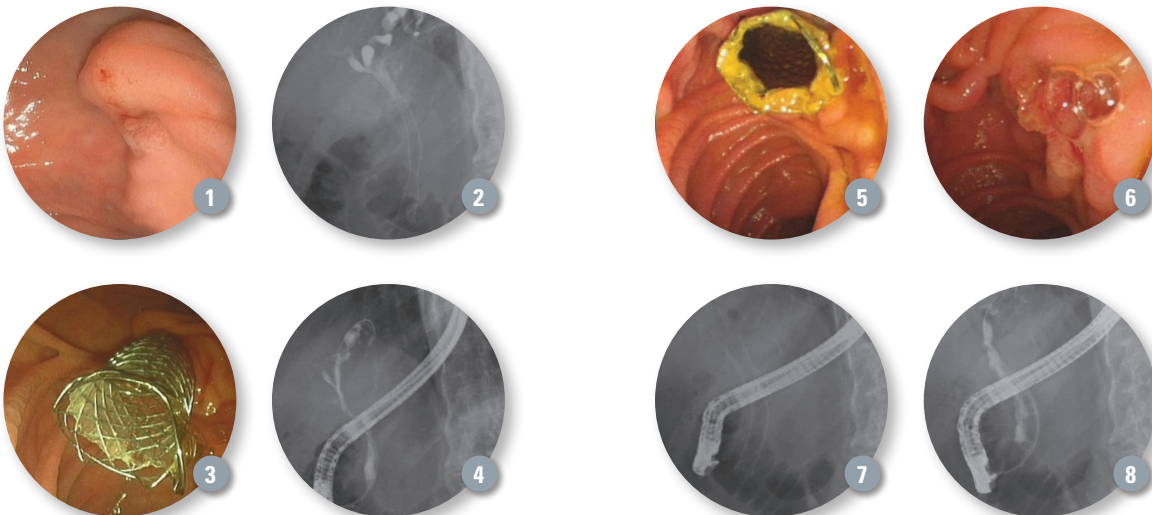
## DISCUSSION

From 2010 to 2011, WallFlex Fully Covered Metal Stents were placed in 36 patients with benign biliary strictures in our hospital. When adequate biliary drainage was achieved, metal stents were removed. Resolution of the benign biliary strictures was found in 28 of 36 patients (77.8%). All fully covered metal stents were removed successfully. Temporary placement of fully covered metal stents for benign biliary strictures is safe and efficacious.

Results from our experience are summarized in **Table 1**.

**Table 1:** Fully covered metal stent for treatment of benign biliary strictures

Number of patients	36
Sex (male / female)	17 / 19
Median age (y)	55.4
Etiology of BBS	
• Chronic pancreatitis	16
• Biliary calculi	12
• Surgical	8
CSEMS length	
• 6cm	23
• 8cm	13
Early complication	
• Mild acute pancreatitis	3
Late complication	
• Stent migration	1
Median stent placement time	2.4 months
Removal rate of stent	36 / 36
Immediate resolution rate of stricture	28 / 36



**NOTE:** Use of the WallFlex Biliary RX Fully Covered Stent for the treatment of benign strictures or stenoses has not been cleared for use in the United States.

**WARNING:** The safety and effectiveness of the WallFlex Biliary Stent for use in the vascular system has not been established.

ACCESS Magazine was produced in cooperation with several physicians. The procedures discussed in this document are those of the physicians and do not necessarily reflect the opinion, policies or recommendations of Boston Scientific Corporation or any of its employees.

Results from case studies are not predictive of results in other cases. Results in other cases may vary.

**CAUTION:** The law, including Federal (USA) law, restricts these devices to sale by or on the order of a physician. Indications, contraindications, warnings and instructions for use can be found in the product labeling supplied with each device.

WallFlex is a registered or unregistered trademark of Boston Scientific Corporation or its affiliates. ©2012 Boston Scientific Corporation or its affiliates. All rights reserved.

ENDO-101308-AA September 2012