

Endoscopic Management of a Benign Biliary Stricture due to Chronic Pancreatitis by Inserting a Fully Covered Self-expanding Metal Stent



Gianfranco Donatelli, M.D.

Unité d'Endoscopie
Interventionnelle

Hôpital Privé des Peupliers

Paris, France

technique spotlight

Patient History

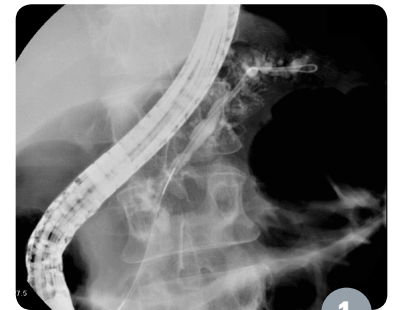
A 39-year-old man with a history of chronic alcoholism was admitted to the hospital, in an emergency, for abdominal pain and jaundice. A CT scan showed an obstructive chronic calcifying pancreatitis (chronic pancreatitis) with dilatation of the common bile duct above the head of the pancreas. The pancreatic duct was obstructed by the stricture. Possible treatments were surgery or endotherapy. Endoscopic stenting was chosen in order to treat biliary and pancreatic stenosis.

Procedure

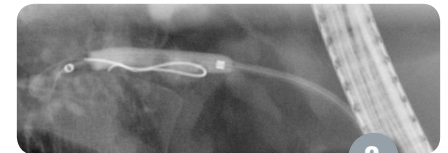
Under general anesthesia, the papilla was visualized and appeared normal, as there was no ampulloma or any other disease. Primary cannulation of the main pancreatic duct was successfully attempted and pacification showed a canal stricture at the level of the junction body-tails (Figure 1). A pancreatic sphincterotomy was performed, and after a 6mm hydrostatic dilation using a Hurricane™ RX Biliary Balloon Dilation Catheter (Figure 2), a multi-perforated 10Fr Advanix™ Pancreatic Stent was placed.

Post Procedure

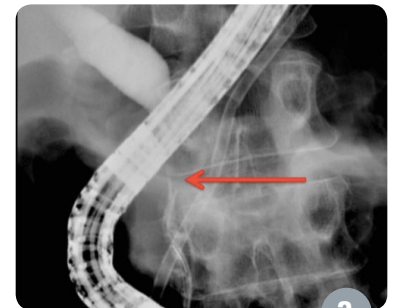
Using a standard three-lumen Ultratome™ Sphincterotome loaded with a straight guidewire, cannulation of the common bile duct was accomplished. Injection of medium contrast showed a long, benign extrinsic biliary stenosis evaluated at 3cm in length (Figure 3) with dilation of the common bile duct. The guidewire was inserted deeply in the intrahepatic ducts and a biliary sphincterotomy was performed. Then, in order to treat the stenosis, the decision was made to place a WallFlex™ Biliary RX Fully Covered Stent. Under fluoroscopy, a 6cm long and 10mm in diameter WallFlex Biliary RX Fully Covered Stent System RMV was placed. The 10mmx60mm stent was chosen based on the length of stenosis and considering at least 1cm of extension at both extremities to prevent migration, being careful to position the stent below the hilar region



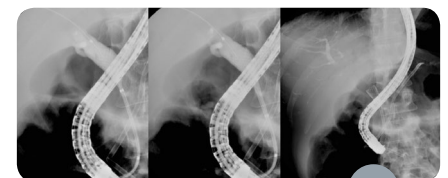
1



2

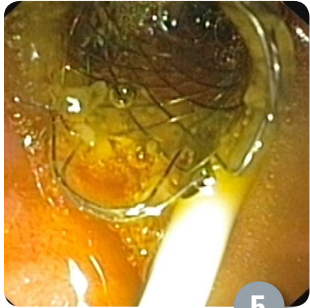

3



4

Endoscopic Management of a Benign Biliary Stricture due to Chronic Pancreatitis by Inserting a Fully Covered Self-expanding Metal Stent



technique spotlight

(Figures 4a-b-c, Figure 5). Following stent placement, we observed immediate biliary flow following deployment of the WallFlex Biliary RX Fully Covered Stent. The patient was discharged 48 hours later, with antibiotic therapy for five days in order to prevent cholecystitis, with improved liver function test results.

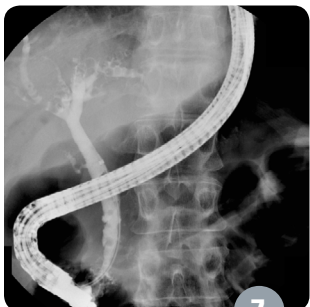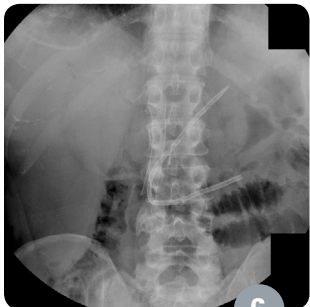
Discussion

Six months after stent implantation, the patient was scheduled for removal. Blood chemistry was normal. An abdominal x-ray was taken of the bile duct, which showed that the covered biliary stent was still in place and well positioned despite the partial migration of the plastic pancreatic stent into the duodenum (Figure 6). Both stents were removed and occlusive retrograde cholangiography indicated that the biliary stricture was resolved, (Figure 7). Main pancreatic duct contrast injection was achieved and showed improvement of the duct stricture. Nevertheless, a second plastic pancreatic stent placement was performed for another period of six months. At the time of pancreatic stent removal (one year since first ERCP) the common bile duct was free of stenosis. At 18-month follow-up, the patient is doing well, is completely asymptomatic and liver function tests are normal.

Conclusion

In conclusion, use of the WallFlex™ Biliary RX Fully Covered Stent System RMV can be a successful therapy option for management of benign biliary strictures secondary to chronic pancreatitis. It is a valid alternative to multiple plastic stenting and surgery.

Migration may occur spontaneously and can be treated by delivering longer stents: however, particular attention should also be paid during stent deployment to avoid obstruction of hilum biliary side branches.



Results from case studies are not predictive of results in other cases. Results in other cases may vary.

All trademarks are the property of their respective owners.

CAUTION: The law restricts these devices to sale by or on the order of a physician. Indications, contraindications, warnings and instructions for use can be found in the product labelling supplied with each device. Information for use only in countries with applicable health authority registrations. Material not intended for use in France.

CAUTION: Federal (USA) law restricts this device to sale by or on the order of a physician

Warning: The safety and effectiveness of this device for use in the vascular system has not been established.

Warning: Use caution when placing stent near ductal branches to avoid obstruction of duct. Placement of a fully covered biliary stent across a branch duct or major bifurcation may result in complications due to blockage of flow from the branch duct and prevent endoscopic or transhepatic access for future procedures.

Warning: The safety and effectiveness of the stent for benign stricture treatment has not been established for indwell periods exceeding 12 months.

A complete list of Indications, Contraindications, Warnings and Instructions for Use can be found in the product labeling supplied with each device.

Boston Scientific Corporation
300 Boston Scientific Way
Marlborough, MA 01752-1234
www.bostonscientific.com/gastro
www.EndoSuite.com

©2016 Boston Scientific Corporation
or its affiliates. All rights reserved.

ENDO-415316-AA August 2016