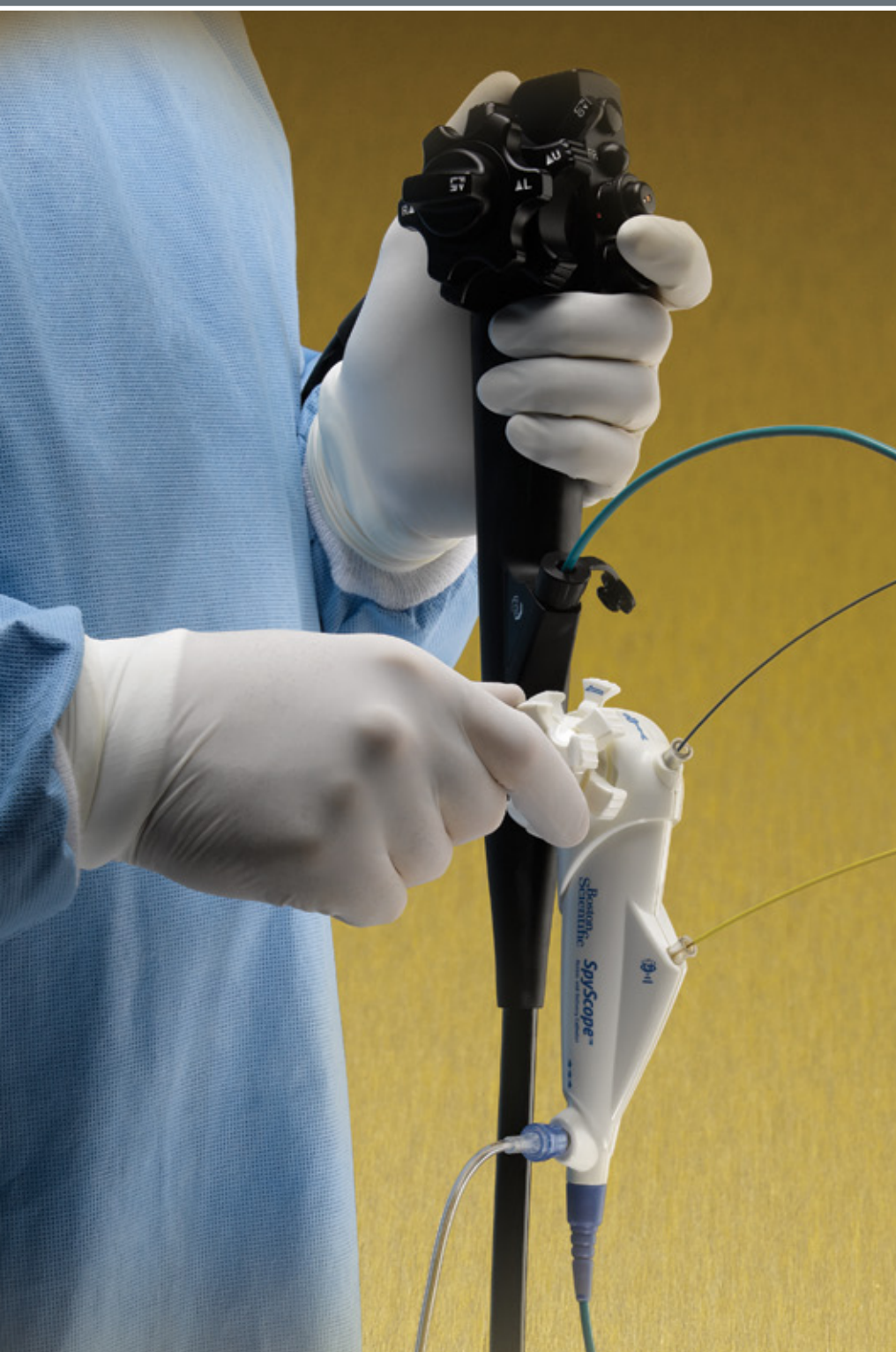

# SpyGlass™ Direct Visualization System

FINAL RESULTS FROM LARGEST PROSPECTIVE INVESTIGATION  
OF PERORAL CHOLANGIOSCOPY

Published in *Gastrointestinal Endoscopy (GIE)*  
October 2011

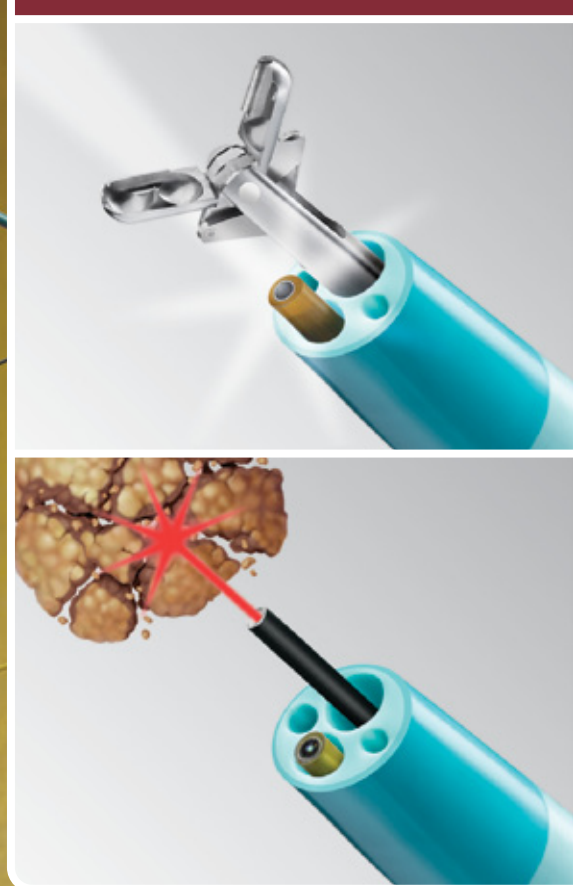

## LEAD AUTHORS

Yang K. Chen, MD\*

Mansour A. Parsi, MD

Douglas Pleskow, MD



## Study Investigators



**Yang K. Chen, MD, FASGE, AGAF, FACG**  
June 20, 1952 – Oct. 15, 2010



**Peter D. Stevens, MD**  
Nov. 1, 1961 – Aug. 13, 2011

### Two gifted physicians, two extraordinary men

For years, many of us at Boston Scientific had the privilege to know and work with Dr. Yang Chen and Dr. Pete Stevens, two gifted physicians with a passion for patient care and a deep commitment to clinical research, particularly in the area of developing and evaluating new endoscopic technologies. Along with this team of investigators, their pioneering work with single operator cholangioscopy helped establish and expand its use in gaining acceptance as a new standard of care in the management of biliary stricture and stone disease.

As gifted physicians, Dr. Chen and Dr. Stevens will be remembered for their vision, leadership and tireless dedication to improving patient care. As extraordinary men, they will be remembered for the strength of their relationships – as teachers, mentors, colleagues and friends – and their passion for life and learning.

**Yang K. Chen\*, MD, Lead Investigator\*\***  
University of Colorado  
Health Sciences Center  
Denver, Colorado (USA)

**Mansour A. Parsi\*, MD, Lead Investigator**  
Cleveland Clinic Foundation  
Cleveland, Ohio (USA)

**Douglas K. Pleskow\* MD,**  
Lead Investigator  
Beth Israel Deaconess Med.  
Center/Harvard Medical School  
Boston, Massachusetts (USA)

**Kenneth Binmoeller\*, MD**  
California Pacific Medical Center  
San Francisco, California (USA)  
Phone: 415-600-1151

**Prof. Guido Costamagna**  
Università Cattolica del Sacro Cuore  
Rome, ITALY

**Prof. Jacques Devière**  
Universite Libre de Bruxelles/  
Hopital Erasme  
Brussels, BELGIUM

**Oleh Haluszka\*, MD**  
Fox Chase Cancer Center  
Philadelphia, Pennsylvania (USA)

**Robert Hawes\*, MD**  
Medical University of South Carolina  
Charleston, South Carolina (USA)

**Prof. Søren Meisner\***  
H. S. Bispebjerg Hospital (S.M.)  
Kobenhavn, DENMARK

**Prof. Horst Neuhaus**  
Evangelisches Krankenhaus Dusseldorf  
Dusseldorf, GERMANY

**Bret T. Petersen\*, MD**  
Mayo Clinic  
Rochester, MINNESOTA (USA)

**Prof. Thierry Ponchon**  
Hopital Edouard Herriot  
Lyon, FRANCE

**Stuart Sherman, MD**  
Indiana University School of Medicine  
Indianapolis, Indiana (USA)

**Adam Slivka\*, MD, PhD**  
Pittsburgh Medical Center Health System  
Pittsburgh, Pennsylvania (USA)

**Peter D. Stevens\*, MD\*\***  
Columbia-Presbyterian Medical Center  
New York, New York (USA)

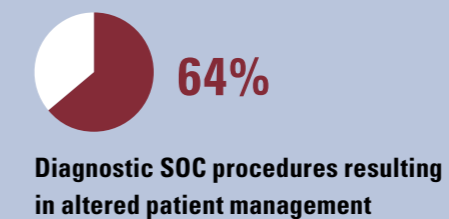
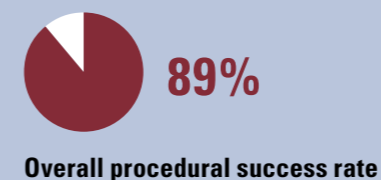\*Paid consultants to Boston Scientific  
\*\*Deceased

## Overall Study Results and Conclusions

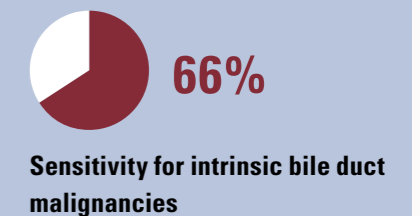
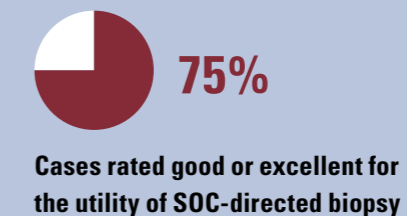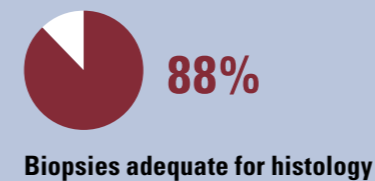
### HIGHLIGHTS OF RESULTS

Involving 15 U.S. and European centers and nearly 300 patients, this prospective study is the **largest investigation** of peroral cholangioscopy ever reported. In addition, in biopsy patients without tissue evidence of malignancy, follow-up was scheduled at **6 and 12 months** unless a definitive diagnosis was established sooner.

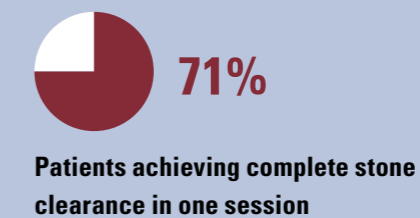
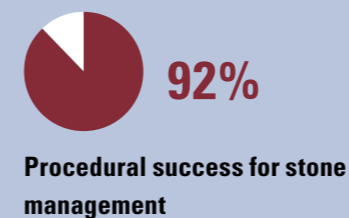#### Overall Study Results



#### Diagnostic SOC Results



#### Stone Therapy SOC Results



### Conclusions

Evaluation of bile duct disease and biliary stone therapy can be safely performed with a high success rate using the SpyGlass single-operator cholangioscopy (SOC) System. In this study, this technology demonstrated its adaptability for use by a wider group of skilled endoscopists and referral centers in the United States and Europe.

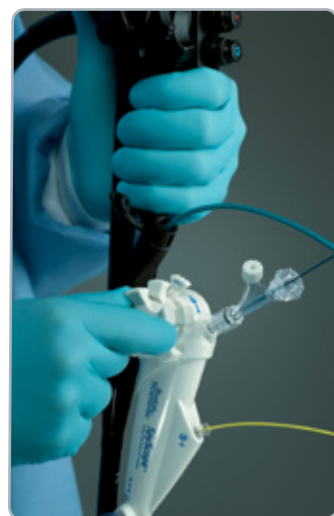
Abbreviations: EHL, electrohydraulic lithotripsy; IQR, interquartile range; SOC, single-operator cholangioscopy

# History of Cholangioscopy

## Development of the SpyGlass™ System

### HISTORY OF CHOLANGIOSCOPY

With over 300 articles published to date, it is well documented that direct visualization of the bile ducts by peroral cholangioscopy can be of value in the diagnosis of biliary abnormalities, obtaining biopsy specimens, and guiding stone therapy.<sup>1</sup> And, although the first use of peroral cholangioscopy was reported in the 1970s, its adoption has been significantly hampered by the technical limitations of traditional cholangioscopes – fragility that resulted in high repair costs, limited steerability, poor irrigation capabilities and the need for two operators.



### SpyGlass Direct Visualization System

The SpyGlass System was developed to overcome the limitations of traditional cholangioscopes and provide optically-guided therapeutics for targeted stricture and stone management. It is the first single-use, single-operator cholangioscopy (SOC) system with two dedicated irrigation channels, an optic channel and a 1.2mm diameter therapeutic channel – all within the 10Fr (3.3mm) SpyScope™ Access and Delivery Catheter that also provides 4-way tip deflection to facilitate steerability and maneuverability through small ducts.

The irrigation channels of the SOC system permit irrigation fluid flow rates four- to five-fold those achievable through the working channel of conventional systems.<sup>1</sup> In bench simulations with the SpyBite™ Biopsy Forceps loaded, the SOC system was successful twice as often in gaining access to target sites compared with a conventional choledochoscope limited to 2-way deflection.<sup>1</sup>

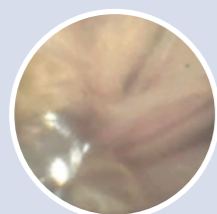
### SPYGLASS SYSTEM TODAY

Since its launch in July 2007, the SpyGlass SOC System has been utilized in more than 30,000 patient procedures and has been installed in over 700 medical facilities worldwide. Clinical data have been published in more than 100 abstracts and articles in medical journals.\*

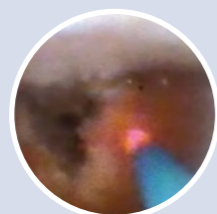### Expanding Therapeutic Applications

Although this clinical registry focused on tissue acquisition and large stone management in the bile ducts, there are now many other documented applications of the SpyGlass System throughout the pancreato-biliary system that continue to reaffirm its expanded utility and versatility.

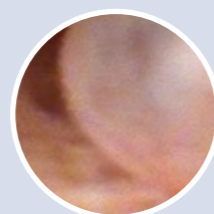#### SPYGLASS SYSTEM INTRADUCTAL IMAGES



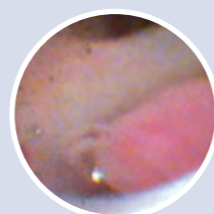Biopsy of IPMN with SpyBite Forceps



Stone Therapy with Holmium Laser



Biliary Variceal



Biliary Leiomyoma

\*Through January 2012

# Study Overview

### STUDY OBJECTIVES

A feasibility study at two tertiary centers previously reported that this system can provide adequate samples for histological diagnosis and successfully facilitate stone therapy.<sup>1</sup> The objective of this study (the **largest** ever to report on peroral cholangioscopy) was to confirm the utility of this system in more widespread clinical use.

### Design/Setting/Patients/Limitations

This was a prospective clinical cohort study of 15 endoscopic referral centers in the U.S. and Europe, with 297 patients requiring evaluation of bile duct disease or biliary stone therapy. The study was observational in design with no control group.

### Outcome Measurements/Endpoints

Procedural success was defined as the ability to: (1) visualize target lesions and, if indicated, collect biopsy specimens adequate for histological evaluation; or (2) visualize biliary stones and initiate fragmentation and removal.

### Summary of Evaluation Criteria

All patients were evaluated before the SOC procedure and 48 to 72 hours and 1 month thereafter. At baseline, a medical history was taken and demographic characteristics and the indication for ERCP were recorded. After completion of ERCP, a diagnosis and patient management plan were assigned based on the **cholangiographic** findings associated with impressions (benign, malignant or indeterminate), and the indication for the immediately succeeding SOC procedure was noted.

Based on the findings at **cholangioscopy**, associated with SOC impressions (benign or malignant), the diagnosis and management plan were updated. On review of the **histopathological** findings, the diagnosis and management plan were again updated. In biopsy patients without tissue evidence of malignancy, follow-up was scheduled for **6 and 12 months** unless a definitive diagnosis was established sooner.

#### BASELINE PATIENT DATA

Parameter	N – 297
<b>Age, y, mean (SD)</b>	<b>62.9 (16.2)</b>
Body mass index, kg . m <sup>-2</sup> , mean (SD)	26.6 (5.8)
<b>Sex, no. (%)</b>	
Male	145 (48.8)
Female	152 (51.2)
<b>Admission, no. (%)</b>	
Inpatient	107 (36.0)
Outpatient	190 (64.0)
<b>Previous ERCP procedures, no. (%)</b>	
0	41 (13.8)
1	90 (30.3)
2	77 (25.9)
≥ 3	89 (30.0)
<b>History of post-ERCP pancreatitis, no. (%)</b>	<b>23 (7.7)</b>
<b>Pre-existing hepatobiliary &amp; pancreatic conditions, * no. (%)</b>	
Cholangitis (< 4 wks before)	48 (16.2)
Cirrhosis	19 (6.4)
Chronic pancreatitis **	7 (2.4)
Acute pancreatitis (< 4 wks before)	4 (1.3)
Sphincter of Oddi dysfunction	2 (0.7)

SD, Standard deviation.

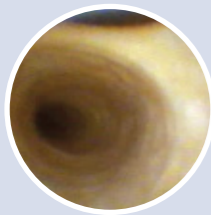\*In 3 patients, both cholangitis and cirrhosis were present, and in one of them, chronic pancreatitis also. In no other case were there more than 2 reported pre-existing hepatobiliary or pancreatic conditions. No patient exhibited coagulopathy at baseline.

\*\* Based on objective evidence.

# SOC Diagnostic Cases

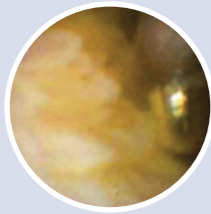
## Overview of Results

### SPYGLASS™ SYSTEM INTRADUCTAL IMAGES

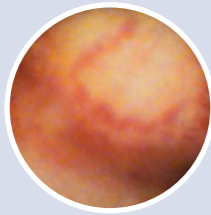


Normal Duct Wall with Bifurcation

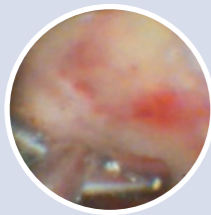
### Biopsies using SpyBite™ Forceps confirmed...



Benign Inflammation



Malignant Klatskin Tumor



Cholangiocarcinoma -  
Left Hepatic Duct

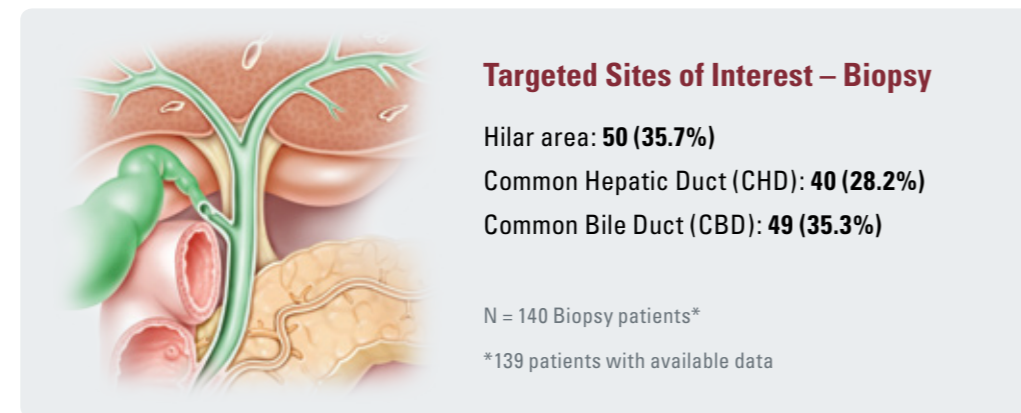
## Disposition of Diagnostic Cases (297 total cases)

226 underwent single-operator cholangioscopy (SOC) for diagnostic purposes

- 140 cases with biopsy (87% success rate)
- 86 cases without biopsy (93% success rate)

### Overview of Results

- 88% of SOC-directed biopsies obtained adequate tissue for histological evaluation
- 75% of investigators rated the utility of SOC-directed biopsy as Good or Excellent
- 64% of diagnostic SOC procedures altered clinical management of those patients (including changes to stricture management in 69% of patients and the decision to perform surgery in 25%)



### Number of Biopsy Bites

Median no. of biopsy bites attempted (IQR, Interquartile range)	<b>4 (3-5)</b>
Median no. of biopsy attempts successful (IQR, Interquartile range)	<b>3 (3-4)</b>

## Sensitivity Data for Intrinsic Malignancy\*

- 56% sensitivity for ERCP impression
- 84% sensitivity for SOC impression
- 66% sensitivity for SOC-directed biopsy histology

## Conclusions

Evaluation of bile duct disease can be safely performed with a high success rate using the SpyGlass SOC System in diagnostic procedures. In this study, this technology demonstrated its adaptability for use by a wider group of skilled endoscopists and referral centers in the United States and Europe.

\*The study also evaluated extrinsic malignancy data which had much lower sensitivity rates. An inherent limitation of cholangioscope-guided biopsy with miniaturized biopsy forceps is the inability to reach tumor tissue associated with extrinsic tumors.

### Adverse Events<sup>2</sup>

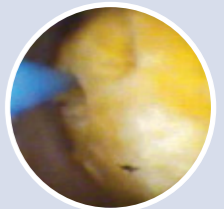- 7.5% (17 patients) experienced a serious ERCP- or SOC-related adverse event within 30 days
- Sixteen of the events resolved without sequelae. The remaining event, an episode of ERCP-related cholangitis, was managed with medication and stenting.

# SOC Stone Therapy Cases

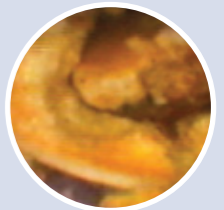## Overview of Results

### SPYGLASS™ SYSTEM INTRADUCTAL IMAGES

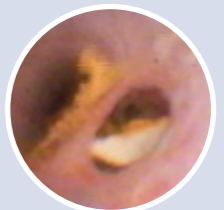#### Biliary Stones



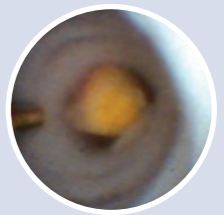Large Stone Disruption with Holmium Laser



Stones Occluding Bile Duct



Mirizzi's Syndrome



Large Stone Disruption with Electrohydraulic Lithotripsy

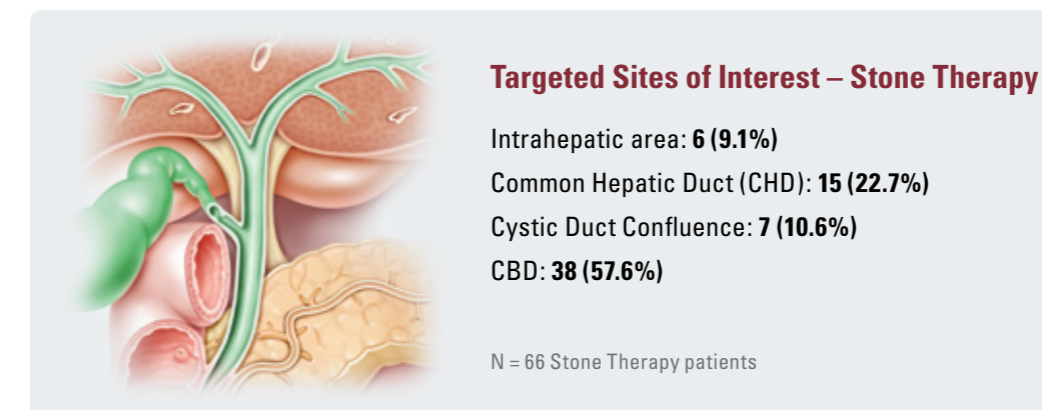
## Disposition of Stone Therapy Cases (297 total cases)

66 underwent EHL (electrohydraulic lithotripsy) or laser stone therapy

- The majority of patients who underwent SOC-directed stone therapy were referred after ERCP with failed or incomplete conventional stone removal (see Baseline Data Table)

### Overview of Results

- 92% success rate (61/66 patients) for stone therapy by EHL or laser lithotripsy\*
- 85% of cases were rated Good or Excellent for quality of stone visualization by investigators
- 71% of patients achieved complete stone clearance in one session
- 11% had one or more stones identified only by SOC but not ERCP\*\*



## Size of Stones

- Stones ranged from 5mm to a maximum of 60mm with a median stone size of 19mm
- 65% of patients had impacted stones

## Conclusions

Biliary stone therapy can be safely performed with a high success rate using the SpyGlass SOC System. In this study, this technology demonstrated its adaptability for use by a wider group of skilled endoscopists and referral centers in the United States and Europe.

\*Procedural success for SOC-directed stone therapy was defined as visualization of biliary stones and initiation of stone fragmentation and removal

\*\*The ability to detect stones missed by ERCP is consistent with the results of 3 earlier studies on peroral cholangioscopy and can be ascribed in large part to the quality of stone visualization with the SOC system<sup>1</sup>. The quality of stone visualization also aided in accurately targeting stones, for instance, allowing precise placement of the EHL or laser probes on the surface of difficult stones.

### Adverse Events<sup>2</sup>

- 6.1% (4 patients) experienced a total of 5 serious ERCP- or SOC-related adverse events, all within the first 5 days after therapy
- The duodenal perforation was treated surgically, whereas the other 4 events resolved without sequelae.

## SELECT BIBLIOGRAPHY OF PUBLISHED OR PRESENTED DATA

### Stone Therapy Articles

Sepe P, Berzin TM, Sanaka S, Patel N, Sawhney M, Chuttani R, Pleskow D; Single-operator cholangioscopy for the extraction of cystic duct stones (with video). *Gastrointest Endosc.* 2012; 75(1): 206-210.

Sephehrmanesh, D; Impacted dormia basket – effective non-surgical treatment with SpyGlass assisted electrohydraulic lithotripsy. Abstract. Presented at UEGW 2011.

### Diagnostic Articles

Draganov PV, Chauhan S, Wagh M, Gupte A, Lin T, Hou W, Forsmark C; Diagnostic accuracy of conventional and cholangioscopy-guided sampling of indeterminate biliary lesions at the time of ERCP: a prospective, long-term follow-up study. *Gastrointest Endosc.* 2012; 75(2): 347-353.

Ramchandani M, Reddy DN, Gupta R, Lakhtakia S, Tandan M, Darisetty S, Sekaran A, Rao GV; Role of single-operator peroral cholangioscopy in the diagnosis of indeterminate biliary lesions: A single-center, prospective study. *Gastrointest Endosc.* 2011; 74 (3): 511-9.

Robbins D; Biliary leiomyoma diagnosed by SpyGlass cholangioscopy (with video): Commentary. *Gastrointestinal Endoscopy.* 2011; 74 (2): 409-10.

Iqbal S, Stevens PD; Cholangiopancreatography for targeted biopsies of the bile and pancreatic ducts. *Gastrointestinal Endoscopy Clinics of North America.* 2009; 19(4): 567-77.

Parsi MA, Guardino J, Vargo JJ; Peroral cholangioscopy-guided stricture therapy in living donor liver transplantation. *Liver Transplantation.* 2009; 15(2): 263-5.

Johnson G, Hatfield A, Webster G, Groves C, Rodriguez-Justo M; A diagnosis of an intraluminal carcinoid tumor of the bile duct by using cholangioscopy. *Gastrointestinal Endosc.* 2010; 71(3): 622-623.

### Other Related Articles

Navaneethan U, Venkatesh P, Al Mohaheer M, Gelrud A; Successful diagnosis and management of biliary cast syndrome in a liver transplant patient using single operator cholangioscopy. Case Report. *Journal of the Pancreas.* 2011; 12(5): 461-463.

Barkay O, Bucksot L, Sherman S; Endoscopic transpapillary gallbladder drainage with the SpyGlass cholangiopancreatography system. *Gastrointestinal Endoscopy.* 2009; 70(5): 1039-40.

Dwyer LK, Polavarapu N, Hood S, Sheard J, Sturgess R; Per oral cholangioscopy – systematic evaluation in clinical practice. *Digestive Diseases, Pathology*, University Hospital Aintree, Liverpool, United Kingdom.



To learn more about SpyGlass™, go on: [www.youtube.com/bostonscientificendo](http://www.youtube.com/bostonscientificendo)  
Or use your smart phone to scan this code.

<sup>1</sup>Chen Y et al, Single-operator cholangioscopy in patients requiring evaluation of bile duct disease or therapy of biliary stones (with videos). *Gastrointest Endosc* 2011;74:805-814.

<sup>2</sup>Serious adverse events were defined as those leading to death, life-threatening or permanent illness or injury or intervention to prevent such illness or injury or hospital admission or prolongation of hospital stay.