


# SpyGlass™ Discover Digital Catheter

## SpyGlass™ Discover Digital Catheter Technique Spotlight

### Presented by:

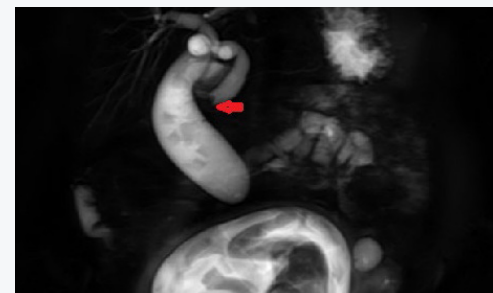[Dr. Amir Rahneimai Azar, MD](#)

Chief, Surgical Oncology and HPB Surgery  
Arrowhead Regional Medical Center  
Assistant Professor of HPB and Oncology Surgery,  
California University of Science and Medicine



### Patient Presentation

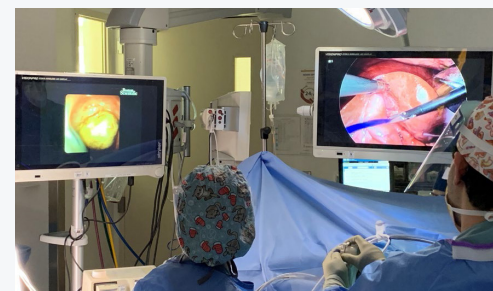A 30-year-old female in a second trimester of her pregnancy presented with symptoms and signs consistent with acute cholecystitis. Due to a deranged liver function test and a dilated common bile duct (CBD), from an ultrasound, a MRCP was obtained which revealed choledocholithiasis. A subsequent ERCP was aborted after a few stone extraction attempts. This was done to mainly minimize radiation exposure of the fetus, and a plastic stent was placed. However, the patient continued to be symptomatic after the procedure.



MRCP demonstrated distended gallbladder with multiple stones, and dilated CBD. Red arrow pointing to filling defects in the CBD.

### Procedure

In view of continuation of symptoms with leukocytosis despite conservative management, and after a lengthy discussion, the patient was taken to the operating room for laparoscopic cholecystectomy. During the procedure, trans-cystic exploration of the common bile duct (CBDE) was performed using the SpyGlass™ Discover Digital Catheter. After direct visualization of the dilated CBD with two stones at the level of the sphincter of Oddi, a basket was used to remove the stones under direct visualization. After confirming the duct was clear, an EndoLoop was placed over the cystic duct stump. The operation took 150 minutes with EBL of 10 cc.



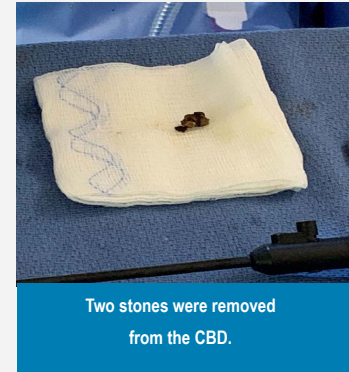
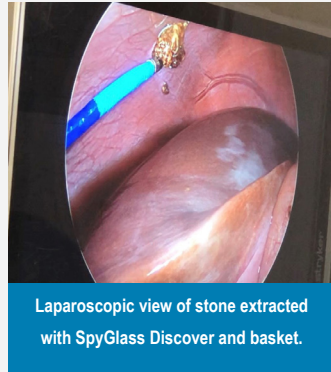Right: Laparoscopic view on right with SpyGlass Discover entering cystic duct.  
Left: Spy Discover direct image of stone in the CBD.

The patient was discharged home the next day with down-trending LFTs without any complications. Two weeks later during a post-operative clinic visit, the patient was doing well with normal liver function tests and a viable fetus.

## Procedure

Laparoscopic trans-cystic CBDE using SpyGlass™ Discover Digital Catheter during cholecystectomy can have several potential advantages over traditional method of duct imaging (e.g., MRCP) followed by ERCP and cholecystectomy<sup>1, 2, 3</sup>:

- Reduced length of stay
- Cost-effectiveness
- Prevention of ERCP-associated complications



## References:

- 1 Meta-analysis of single-stage versus two-staged management for concomitant gallstones and common bile duct stones. Li et.al. J Minim Access Surg. Jul-Sep 2020;16(3):206-214.
- 2 Efficacy and safety of laparoscopic bile duct exploration versus endoscopic sphincterotomy for concomitant gallstones and common bile duct stones: A meta-analysis of randomized controlled trials. Gao et.al. Medicine (Baltimore). 2017 Sep;96(37):e7925.
- 3 Laparoscopic common bile duct exploration plus cholecystectomy versus endoscopic retrograde cholangiopancreatography plus laparoscopic cholecystectomy for cholecystocholedocholithiasis: a meta-analysis. Lyu et.al. Surg Endosc. 2019 Oct;33(10):3275-3286.

**IMPORTANT INFORMATION:** These materials are intended to describe common clinical considerations and procedural steps for the use of referenced technologies but may not be appropriate for every patient or case. Decisions surrounding patient care depend on the physician's professional judgment in consideration of all available information for the individual case. Boston Scientific (BSC) does not promote or encourage the use of its devices outside their approved labeling. Case studies are not necessarily representative of clinical outcomes in all cases as individual results may vary.

This case study was produced in cooperation with Dr. Amir Azar. Results from case studies are not predictive of results in other cases. Results in other cases may vary.

**CAUTION:** The law restricts these devices to sale by or on the order of a physician. Indications, contraindications, warnings and instructions for use can be found in the product labelling supplied with each device. Products shown for INFORMATION purposes only and may not be approved or for sale in certain countries. This material not intended for use in France. Rx Only.

Images provided courtesy of Dr. Amir Azar. All trademarks are the property of their respective owners.

©2021 Boston Scientific Corporation or its affiliates. All rights reserved.

ENDO-1001302-AA

**Boston  
Scientific**  
Advancing science for life™

Boston Scientific Corporation  
300 Boston Scientific Way  
Marlborough, MA 01752-1234  
www.bostonscientific.com

©2021 Boston Scientific Corporation  
or its affiliates. All rights reserved.

ENDO-1030408-AA