


# access

ENHANCING PATIENT OUTCOMES. DELIVERING TOTAL VALUE.™



## ► The AXIOS™ Stent and Delivery System:

Changing the practice of therapeutic EUS

Improving the supply chain  
by leveraging  
industries'  
best practices

Boston Scientific  
Receives Supplier  
Excellence Award  
from the *Healthcare  
Transformation  
Group*



## A Message From Dave Pierce

The practice of endoscopy continues to expand and devices have played an important role in this evolution. Providing physicians with options to get an earlier diagnosis, treat less invasively and, in many cases, have alternatives to surgery has had a significant impact on the treatment of GI diseases and patient outcomes. Our products and services are making a difference for patients, their families and the healthcare providers who serve them.

Earlier this year we acquired the AXIOS™ Stent and Delivery System — the first metal stent with 510(k) clearance for the endoscopic drainage of pancreatic pseudocysts.\* Since then, we received 510(k) clearance for the AXIOS Stent and Electrocautery-Enhanced Delivery System. The CE Mark for this product has been in place since May of 2011 and the indication also includes the biliary tract. This system will allow

endoscopists to treat patients who are typically very sick and have few options for treatment. Dr. Kenneth Binmoeller, M.D., director of Interventional Endoscopy Services at California Pacific Medical Center in San Francisco,

talks about the design goal of the system and the potential benefits of a device that could enable a one-device, one-step stent deployment technique (p. 4).

We are hearing from physicians that the new SpyGlass™ DS System is quickly becoming the standard of care for many of their patients. The system's enhanced visualization capability is just one feature that is helping physicians obtain an earlier diagnosis. This allows for the development of a treatment plan that has the potential to reduce unnecessary procedures along with the associated costs and resources. Dr. Matthew Eves tells us how SpyGlass DS is changing his approach to care management (p. 9).

Visualization also plays a critical role in endoscopic mucosal resection (EMR). Professor Jacques Bergman talks about the importance of visibility and how the Captivator™ EMR device's 360-degree in field of view is instrumental in helping a physician inspect a lesion and determining a course of treatment (p. 6).

As costs and efficiencies remain a focus, hospitals are taking a closer look at how they perform their day-to-day operations. Through our ADVANTICS™ Innovative Healthcare Solutions we offer a suite of services, and we are working with customers to improve inventory management, workflow and lab efficiencies, and more as a way to help customers optimize performance. One of our customers reduced their inventory receiving and counting staff time by 67 percent (p. 2). When it comes to operational efficiencies, hospitals can benefit by leveraging best practices from the consumer packaged goods industry — a topic addressed by supply chain expert and senior lecturer at the MIT Sloan School of Management, Steven Spear (p. 3).

Clinician education remains a priority. In 2014, in the U.S. we offered close to 300 physician programs, including lectures, preceptorships and proctorships, and over 1,200 continuing nurse education programs. We continue to expand these programs and make training more accessible through our new EDUCARE EndoSuite web portal (p. 7), our new training center in Beijing, China, and our continued sponsorship of nurse development training through the Society of Gastroenterology Nurses and Associates (p. 8).

November is Pancreatic Cancer Awareness Month. In addition to our Close the Gap fundraising in support of this important cause, we will be making a donation to The Lustgarten Foundation for pancreatic cancer research (p. 5). Boston Scientific will donate up to one percent of its WallFlex™ Biliary Stents and Expect™ Needles sales in the month of November. Visit [www.bostonscientific.com/EndoCares](http://www.bostonscientific.com/EndoCares) to learn about what's being done to fight this disease.



**Dave Pierce**

Senior Vice President, Boston Scientific  
President, Endoscopy Division



*Boston Scientific's Marlborough, Massachusetts headquarters building received a Gold certification for Leadership in Energy and Environmental Design (or LEED). The building was constructed with locally available or recycled materials, and is designed to use 40 percent less water and 15 percent less energy.*



## Inside This Issue

### Articles



- 2 Working with You for a Better Supply Chain



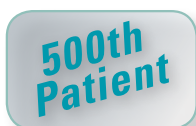- 3 Synchronizing Materials Management for Better Patient Care



- 4 An Interview with Kenneth Binmoeller, M.D.



- 5 November is Pancreatic Cancer Awareness Month  
New Donation Program for Pancreatic Cancer Research



- 5 Brazil Team Supports Colorectal Cancer Screening



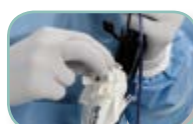- 6 An Interview with Professor Jacques Bergman



- 7 EndoSuite Expands Education and Training to Web Portal



- 8 Program Focuses on Developing Nurse Leaders  
Banner Health Delivers Advanced EUS Cytopathology Training



- 9 SpyGlass™ DS System  
For One Physician, Clearer Views Change Care Management

### Case Studies



- 10 AXIOS™ Stent and Delivery System



- 12-15 SpyGlass™ DS Direct Visualization System



- 16-17 Captivator™ EMR Device



- 18 Expect™ and Expect Slimline Needles for EUS FNA



- 19 NovaGold™ High Performance Guidewire



- 20 Resolution™ Clip



- 21 WallFlex™ Biliary RX Stent

Opt-in to receive ACCESS magazine electronically as well as email updates on new products, indications and resources. Visit [www.bostonscientific.com/endo-access-subscribe](http://www.bostonscientific.com/endo-access-subscribe).

# Working with You for a *Better Supply Chain*

As part of the Massachusetts Institute of Technology's Leaders for Global Operations (LGO) program and Boston Scientific's Supply Chain Optimization Services, M.B.A. recipient Suman

Machinani, M.D., led a supply chain process-improvement pilot program at a hospital endoscopy department — revealing opportunities that can be reproduced at other Boston Scientific customers' facilities.



**W**ITH PATIENT LIVES AT STAKE EVERY DAY, healthcare as an industry must exercise caution when implementing new ideas that other industries would readily adopt with a spirit of innovation. This restraint, though, can be turned into an advantage as healthcare — following in the footsteps of other industries — can observe best practices while avoiding pitfalls that early adopters experience.

In other industries such as **consumer packaged goods (CPG)**, **suppliers and customers collaborate** to reduce excess cost. Suppliers and customers can work together in a number of other ways to better utilize storage space, inform staff about what inventory is on hand and how reordering processes work, and prevent stock-outs while reducing expired or open-and-unused inventory.

For the endoscopy department at one of Boston Scientific's large Northeast U.S. hospital customers, Massachusetts Institute of Technology student Suman Machinani, M.D. — who has since earned his M.B.A. and a Master of Science in Engineering Systems — **embarked on a thesis project to improve inventory and care workflow** based on best practices of the CPG industry while working as an MIT LGO Fellow for Boston Scientific's Supply Chain team. He chose that sector because it, in many ways, resembles the typical hospital's relationship with its consumables suppliers. His theory: Practices that have proven to optimize inventory, improve service levels, and bring down costs in CPG will translate to healthcare.

Such process improvement takes both human interaction as well as automated data systems into account. "Either one, in and of itself, is necessary but not sufficient," said Machinani, who started his career as a physician and got into management because he wanted to improve healthcare as a whole, in addition to treating individual patients. "When those two entities are communicating and aligning with each other, that's where you can create more synergies and more harmony."

## DIAGNOSING INVENTORY'S ILLS

The hospital endoscopy department wanted to solve several problems: Running out of some items, overstocking others, and letting even more go unused. Arbitrary storage, varying levels of staff awareness of what inventory was stored where, and nonstandard ordering procedures all contributed to these problems.

**A three-and-a-half month survey using a new barcode-reading system, across four different endoscopy suppliers, revealed that the hospital possessed about \$145,000 worth of unused inventory and an additional \$29,000 worth of expired supplies.** "The data we collected were like patient vital signs — and they weren't great," Machinani said. "With that, we could come up with a therapeutic plan. And that is collaboration that may work — now it needs to be validated and tested."

With Machinani's detailed analysis and recommended collaboration between hospital staff and Boston Scientific, the endoscopy department began to reconfigure storage and standardize its processes for ordering and Boston Scientific inventory handling, as well as training employees on the new procedures.

A portion of the cure to this hospital's issues involved purely internal housecleaning, such as ensuring that staff unpack supplies soon after they are received to prevent accidental reorders because clinicians were unaware they had arrived. This wasn't just about handling physical material. It was about taking a physical action that created information in a timelier, more accurate fashion.

Yet it was more than just an internal project; other process improvements involved working with Boston Scientific to optimize the supply chain. Upon the request of the hospital, Boston Scientific representatives:

- **Helped educate physicians and nurses** on strategies to reduce situations in which product was opened but unused;
- **Shared with clinical staff** effective inventory-management practices observed across the industry;

- **Worked together with hospital staff** to understand when patient volumes were greater to design standardized reordering processes to accommodate increased traffic; and
- **Established a system with the hospital** to **communicate lead times** for the acquisition of high-volume and high-value items, as well as alerts for changes in **supplier inventory levels** on critical supplies.

To keep improvements happening, the hospital needs to continue to gather data and provide feedback to Boston Scientific. While the benchmarking process is still underway and the returns haven't yet been quantified, Machinani and his collaborators feel improvements will come with this process-improvement exercise. In the future, the hospital and its vendors will conduct periodic check-ins to review results and adjust supply flows as needed.

### BOSTON SCIENTIFIC'S APPROACH TO SERVICES

Collaboration with Boston Scientific begins with sharing information. Learning a hospital's pain points in daily operations helps Boston Scientific, along with the staff, diagnose and solve problems that lead to cost variances, such as expired inventory or frequent daily orders, some of them redundant.

Machinani says that many healthcare providers struggle with the same space limitations that the endoscopy department example in his thesis experienced. While inventory volume might vary from one

provider to another, he added, inventory management is a universal process all healthcare providers must perform — and most likely, there's room for improvement. The busier the hospital, the more critical inventory management becomes and the more likely costs will snowball when they're not managed well.

As a company, Boston Scientific is committed to helping customers achieve process improvements with such customized collaborations, said Bryan Gilpin, director of Global Solutions Delivery at Boston Scientific. "While some organizations have already undertaken complex — and successful — supply-chain improvement projects, many more are just starting to assess their own opportunities for reducing costs and improving patient care through workflow optimization."

"We learned a lot about how our customers operate, what's important to them, and their expectations of a supplier like Boston Scientific," Gilpin said. "We're operationally focused as well, but we got that way by focusing on what's going on inside Boston Scientific's operations. Machinani's work helped us focus outside of Boston Scientific and understand how what we do influences our customers — and vice versa."

For more information on customized collaborations to improve your supply chain processes, contact [supplychainoptimization@bsci.com](mailto:supplychainoptimization@bsci.com) or visit [www.bostonscientific.com/gastroservices](http://www.bostonscientific.com/gastroservices).

Dr. Machinani can be contacted at [smachinani@gmail.com](mailto:smachinani@gmail.com).



Steven Spear

## Synchronizing Materials Management for Better Patient Care

By Steven Spear

### Healthcare has to coordinate increasingly complex supply networks

to bring the best possible care to the bedside, office or home. It needs to cover most people, at the fairest cost. Static

planning and scheduling, no matter how precise, will never be robust. Establishment of a better dynamic — timely informational triggers leading to timely behavioral responses — can be the differentiator. Suman Machinani, M.D.'s research is a particular example of what can prove to be a general approach of great utility.

On the supply-chain side, there are opportunities for improvement. Ideally, clinicians should have exactly the materials they need, when and where they need them, presented in exactly the right way. Were this true all the time, quality of care would be the best possible, and staff would have maximum ease and convenience in performing their mission to improve patient care.

When this ideal of flawless material synchronization is not met and items are lacking, then there is risk of compromising patient and staff experience, and potentially outcomes. The natural reaction, overstocking on materials, is sub-optimal: it raises carrying costs, causes inconvenience by requiring storage and tracking of inventory, and creates the real possibility that the materials on hand will not be

the ones needed. Even if they are, they'll likely not be the most current. Returns against overstock are costly to customers and vendors.

Machinani's work focused on bringing greater synchronization between those at the point of care and those providing the materials. To do so, he drew on examples in other business sectors that place a high premium on synchronization and by drawing on fundamental theory as to what makes dynamic systems both resilient and also agile.

The lesson is that synchronization depends on effective two-way flow of information: headed upstream from users in terms of what has been consumed and what is needed, and downstream to users in terms of what is coming and when. The particular impact of the hospital's relationship with Boston Scientific is win-win for all. This approach of better managing information to keep elements of a larger system in harmony is not constrained to a hospital restocking consumable materials in a particular service line, but has much broader application.

**Steven Spear, DBA MS is senior lecturer at the MIT Sloan School of Management and was a thesis advisor to Dr. Machinani.** His book, *The High Velocity Edge: How Market Leaders Leverage Operational Excellence to Beat the Competition* (McGraw Hill, 2010), has won numerous awards. He is a nationally regarded expert on Lean and is a frequent interviewee in print and broadcast media.

<sup>1</sup>CPG comprises shorter-lived "soft goods" such as clothing, shoes, food and beverages as opposed to "durable goods" that typically last three years or more, examples of which include appliances, sports equipment and automobiles.



## AN INTERVIEW WITH

*Kenneth Binmoeller, M.D., Director of Interventional Endoscopy Services at California Pacific Medical Center in San Francisco*

*Dr. Binmoeller talks about the influences that shaped his career in interventional endoscopy and led to his invention of the FDA-approved AXIOS™ Stent and Delivery System for drainage of pancreatic fluid collections. His company, Xlumena, was recently acquired by Boston Scientific.*

### Q Were there particular experiences that helped shape your passion for interventional endoscopy?

During my fellowship training, we had a patient with bleeding esophageal varices who had undergone several sessions of sclerotherapy. We decided to use a prototype endoscope for band ligation. Treating esophageal varices using a mechanical method was completely new. It was easily performed and worked flawlessly.

Another case was a pregnant woman in her first trimester admitted with sepsis from obstructive cholangitis. We could see that the ampulla was bulging. We used a needle knife to unroof the papilla and the stone just popped out with a gush of infected bile. The patient's critical condition reversed 180 degrees. That was an inspirational moment for me.

So early on in my career I learned to be **inventive and innovative**, always thinking about what type of tool or device I would need **to accomplish the task at hand**.

### Q What do you mean by the art of interventional endoscopy?

The art is about an approach. It's about applying different imaging modalities that complement one another to guide our procedures. It's about delivering and executing the maneuvers with elegance, control, and precision. It's about eliminating redundancy and making sure that every maneuver is purposeful.

### Q What were the influences that led you to develop the AXIOS platform?

The more steps in a procedure, the greater the chance for complications. Each time you exchange a device over a guidewire, there's a potential to lose access. The tract needs to be large enough to place multiple plastic stents for drainage, which increases the potential for leakage alongside the guidewire. If the cyst is not fully adherent to the wall, it may cause the cyst to leak or separate from the wall as you dilate the tract. Thinking in terms of grace, elegance, purposeful maneuvers and reducing redundancy, I knew that we could do a lot to improve on that technique. Those were the seeds that inspired the AXIOS platform.

### Q What is the AXIOS Stent and Delivery System and how does it work to provide an endoscopic solution for the drainage of pancreatic pseudocysts?

The AXIOS platform consists of two components: The AXIOS Stent and the Access and Delivery System.

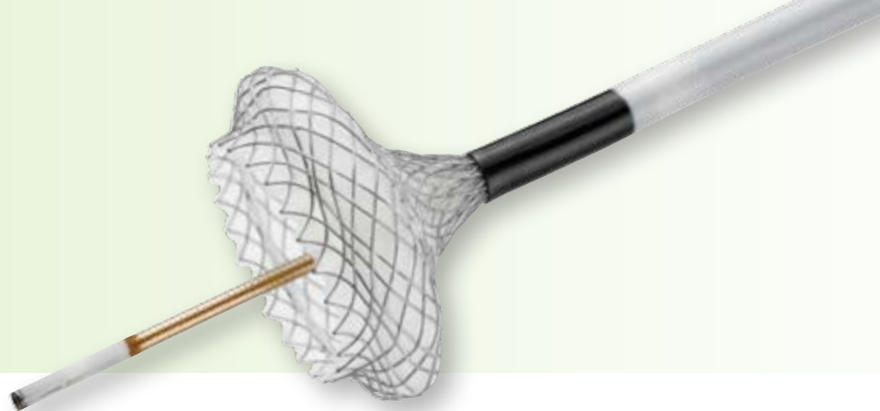
The stent is soft and flexible yet sturdy to reduce the risk of migration, and it's also removable. It's lumen apposing, so you don't get leakage between the two lumens. It's fully covered, which helps prevent leakage, ingrowth and bleeding. It has a large diameter to handle debris in the cysts. It's a short stent that doesn't extend into the lumen of the cavity. That's important because as the cyst drains, the wall collapses down on the stent. If the end of the stent extends into the lumen of the cavity, it can cause injury, bleeding and perforation.

The delivery system eliminates the redundancy. The design goal for the AXIOS platform was '**one device, one step**.' As soon as you're inside the cyst, you can deploy the stent. The individual steps of the Seldinger technique are combined into one. You need dedicated tools such as this to perform EUS-guided transluminal therapy quickly, safely and efficiently.

**Editor's Note:** Since this interview took place, the AXIOS Stent and Electrocautery-Enhanced Delivery System received 510(k) clearance in the U.S.







Q

### Where is the field of interventional endoscopy headed?

Pseudocyst drainage used to be treated surgically; now endoscopic drainage is becoming the preferred approach. Today, a cholecystectomy is the standard treatment for a patient who is symptomatic for gallstones. While that's a less-invasive surgical procedure today, you're still removing a healthy organ. With interventional endoscopy, we can facilitate drainage, prevent the reformation of the gallstones and preserve the organ. The surgical paradigm is to resect and reconfigure. As interventional endoscopists, our goal should be to preserve as much as possible.

Q

### How will the acquisition of your company by Boston Scientific help advance the field of interventional endoscopy?

We're just scratching the surface with the AXIOS platform. I think the **next wave will be a boom in innovations in EUS-guided accessories**. Boston Scientific has already contributed so much to the success of this field. Without question, it is the company that will take interventional endoscopic ultrasound to the next level.

## November is Pancreatic Cancer Awareness Month

In support of Pancreatic Cancer Awareness Month, Boston Scientific's Close the Gap team is once again participating in The Lustgarten Foundation's New England and Long Island Pancreatic Research Walks. The company is an event sponsor, and employees and their families will participate in the walks to fundraise and to help generate awareness about this disease. To learn more or to make a donation, visit [www.lustgarten.org](http://www.lustgarten.org).



## New Donation Program for Pancreatic Cancer Research

With only a 6% five-year survival rate<sup>1</sup>, pancreatic cancer is the 4th leading cause of cancer-related death<sup>1</sup> and Boston Scientific is committed to helping change this alarming statistic. In support of Pancreatic Cancer Awareness Month, Boston Scientific will **donate 1%** of WallFlex™ Biliary Stent and Expect™ Needle sales in November to The Lustgarten Foundation, a non-profit organization dedicated to advancing the scientific and medical research related to the diagnosis, treatment, cure and prevention of pancreatic cancer. To learn more about this donation program and its restrictions,\* please contact your Boston Scientific representative or visit [www.bostonscientific.com/gastro](http://www.bostonscientific.com/gastro).

## Brazil Team Supports Colorectal Cancer Screening

Less than a year after its start, the Boston Scientific team in Brazil reached a major milestone by enrolling the **500th patient** in a free colorectal cancer screening program. The program offers free exams to thousands of people who have limited access to endoscopic screening for what is now the third most common type of cancer in Brazil.

1. The Lustgarten Foundation; [www.lustgarten.org](http://www.lustgarten.org)

\* This program may not be available in all countries.



## AN INTERVIEW WITH Professor Jacques Bergman – World Renowned KOL in Endoscopic Detection and Resection of Esophageal Disease

*Jacques Bergman is professor of gastrointestinal endoscopy and director of endoscopy at the University of Amsterdam MC, Netherlands. Professor Bergman is a therapeutic endoscopist, and a world-renowned KOL in endoscopic detection, ablation and resection of esophageal disease, including Barrett's esophagus. He has a special interest in endoscopic detection and treatment of early neoplasia in the upper digestive tract and has led many global multicenter studies on EMR as a treatment for Barrett's.*

Q

**What are the clinical implications of endoscopic visualization during EMR? How can an EMR device play a role in the procedure?**

The endoscopic resection procedure itself is pretty straightforward. It's a combination of a ligation and a resection — you suck in a lesion, release a band and cut it. Determining where the lesion is and what the outer margins are that you need to resect is where experience comes in. And, for that, endoscopic visualization is crucial. If you have a procedural plan but you can't really execute the plan because the visualization through the cap is fairly limited, this can truly be a significant limitation of the procedure.

A big advantage of the Captivator™ EMR Device is the visibility through the cap when the device is on the tip of your endoscope. The bands are pulled back outside the field of view which leaves virtually the whole **360-degree angle** of the endoscopic view intact. So, the whole field of view is actually available for the endoscopist to inspect the lesion. And this makes it much easier to see what your pre-therapeutic plan was and then to actually execute that plan. So I think the better visualization with this device is clinically very relevant and important.

Q

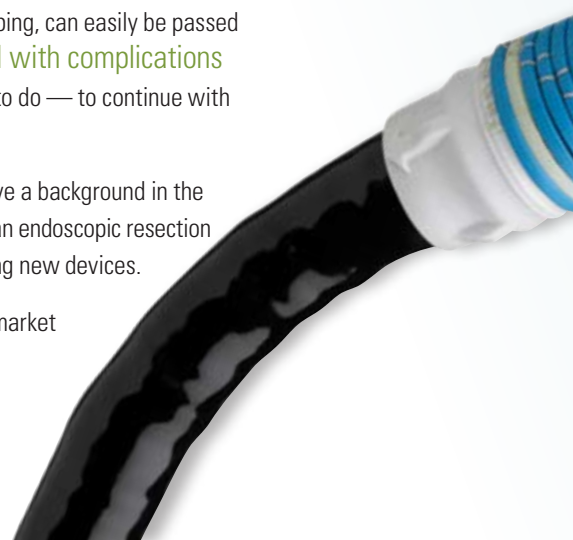**Regarding the future of EMR, do you see opportunities to expand adoption of this treatment option throughout the world with the development of new devices such as the Captivator EMR Device?**

I think the Captivator EMR Device will bring a higher quality treatment option to the field of EMR and perhaps bring a more systematic approach to dealing with these patients. With better visualization, you make your pre-procedural plan and then you can stick to that plan more easily, as well as tackle complications. If you do four or five resections, it will inevitably bleed. It's crucial that you are able to see the bleeding spot and then target it with a coagulation device that you can now easily pass through the working channel with the Captivator EMR Device in place.

With the Captivator EMR Device, most of the devices used for dealing with bleeds or for clipping, can easily be passed alongside the tripwire for the bands. So it gives me a better view and it **allows me to deal with complications quicker** without losing the opportunity — once I've dealt with a bleed or done what I have to do — to continue with the resection with those bands that I still have left on the device.

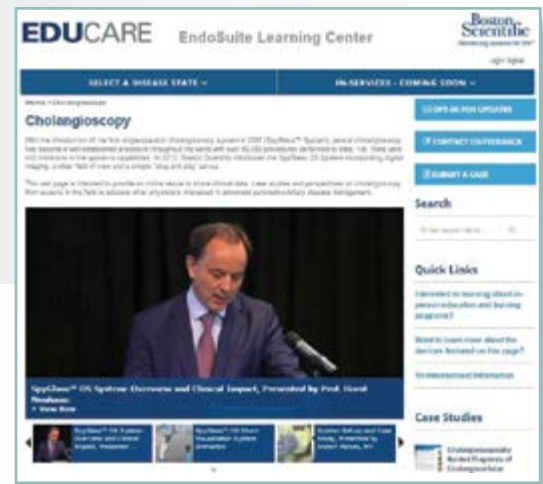I think it's good that a big company like Boston Scientific — a company that really did not have a background in the tissue resection field — now introduces a device that significantly improves the application of an endoscopic resection technique for endoscopists in general, and that also creates a potential platform for developing new devices.

I also think the way that Boston Scientific is taking the new Captivator EMR Device into the market by doing a large-scale multicenter study in which the major respected centers in this field of Barrett's neoplasia are participating will add credibility for the device and help open the door to change and moving this field forward.





# EndoSuite Expands Education and Training to Web Portal



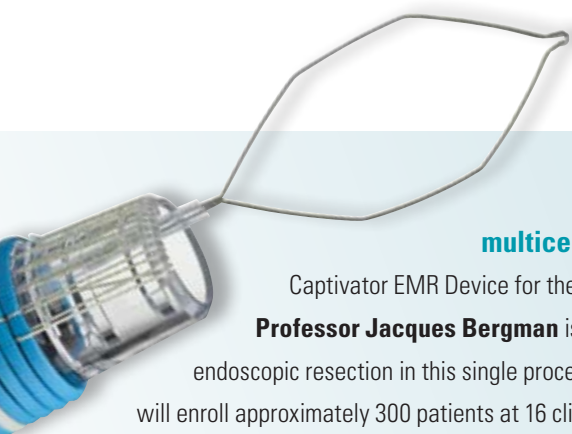
EndoSuite is a new web portal designed to provide easy access to education and training materials for endoscopy clinicians worldwide from virtually any laptop or mobile device anytime, anywhere. EndoSuite is part of a comprehensive suite of EDUCARE education and training programs designed to support healthcare professionals in the delivery of patient care worldwide.

**Featured videos on the EndoSuite portal include** physician lectures on disease management, demonstrations of procedural techniques, case studies, device in-service training and more. The portal will also serve as a platform for live webcasts with question-and-answer sessions as well as archived webcasts for replay.

In addition to video, EndoSuite will host hardcopy materials such as technique guides and connect viewers to a wide range of key resources, including Boston Scientific's GUIDEPOINT Reimbursement Resources, services and programs for administrators and service line managers, as well as access to a variety of in-person EDUCARE programs for physicians, nurses and fellows.

**Content will be continually updated** but the site is currently featuring information on pancreatobiliary disease management, including, cholangioscopy, diagnostic endoscopic ultrasound (EUS), therapeutic EUS, biliary access and cannulation, stricture management and biliary stone management.

Visit **EndoSuite.com**. To learn about EDUCARE programs visit **BostonScientific/educare**.



## Boston Scientific Endoscopy has enrolled the first patient in a multicenter, prospective, global post-market registry to evaluate the new

Captivator EMR Device for the endoscopic resection of early neoplasia in Barrett's esophagus patients.

**Professor Jacques Bergman** is the lead investigator for the post-market registry which will specifically assess endoscopic resection in this single procedure, and also analyze procedure time and quality of tissue specimens. The registry will enroll approximately 300 patients at 16 clinical centers in eight countries, and is expected to be completed in 2016.

For more information about endoscopic management of Barrett's esophagus, you can go to the website that Professor Bergman and a team of other European experts founded, called **Best Academia** [<http://best-academia.eu>]. This website provides information on the endoscopic management of Barrett's esophagus, including videos and presentations on patient selection, early detection of relevant lesions, EMR techniques, and the preparation and assessment of tissue specimens.

## Program Focuses on Developing Nurse Leaders



Since 2012, the **Society of Gastroenterology Nurses and Associates' (SGNA) Nurse Manager Mentor Program** has offered nurses an opportunity to develop their non-clinical skills such as presentation, effective communication and team building skills — all important qualities in becoming a successful leader. The eight-month program provides mentoring, education sessions and networking opportunities to help nurses either prepare for a management role or to become more effective in their current position.

The program is an opportunity for nurses to learn from one another at regional events as well as regular virtual mentor group meetings. It aims to provide nurses with the tools to better manage people issues that may impact patient care, facilitate networking and relationship building, and give access to resources and information outside their own institutions. In addition, nurses learn how to motivate team members and resolve conflicts, communicate more effectively with hospital managers and staff, and manage the issues impacting the changing healthcare environment.

Boston Scientific has sponsored the Nurse Manager Mentor Program since its inception. In addition to financial support, the company has sponsored educational sessions at national conferences and regional events.

"The relationship we have with Boston Scientific is incredibly important in serving our members and fulfilling our mission. The sponsorship dollars help support vital programs that are focused on our future. But the relationship is much deeper than simply providing funding. The partnership we've created is synergistic and drives innovation in SGNA programming. The individuals who have been helped through the programs funded by Boston Scientific are becoming our future leaders — in their units and within the SGNA," said SGNA Executive Director Dale West.

**The 2015-2016 program kicks off in October with a session at the SGNA's headquarters in Chicago, Illinois.** Participants are responsible for travel to this event and the one-time registration fee of \$200 that covers all sessions.

“Nurse managers play a critical role in endoscopy. By developing their leadership abilities and skills, we believe this program has the potential to impact patient care as well as patient satisfaction, which is becoming an increasingly important focus for healthcare providers.”

— Dale West, SGNA Executive Director



To learn how to participate, visit  
<http://www.sgna.org/Education/SGNA-Mentorship-Program>  
or email [dwest@smithbucklin.com](mailto:dwest@smithbucklin.com).

Interested in becoming a nurse mentor?  
Contact Dale West at (312) 673-5911.

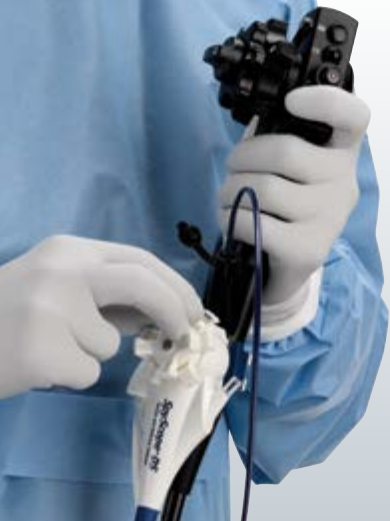To learn about Boston Scientific endoscopy  
training offerings, visit  
[www.bostonscientific.com/EDUCARE](http://www.bostonscientific.com/EDUCARE).

### BANNER HEALTH DELIVERS ADVANCED EUS CYTOPATHOLOGY TRAINING TO ITS NETWORK OF HOSPITALS

**With participation from ten of its hospitals** in the greater Phoenix, Arizona area, Banner Health conducted a half day of advanced training on endoscopic ultrasound (EUS) pathology at Banner University Medical Center in Phoenix. The course was developed in response to the region's increase of endosonographers from 1 to more than 20 over the past 5 years.

David Y. Lu, M.D., assistant professor, pathology and laboratory medicine at UCLA, served as the key lecturer for the event. More than 45 clinicians, including pathologists, gastroenterologists, nurses and technicians, attended the session held in early August that included both lectures and hands-on demonstrations.

"It was a pleasure to work with Boston Scientific in a joint effort to host the Advanced EUS Cytology course at Banner University Medical Center Phoenix. Our vision was to enhance education surrounding EUS and cytopathology and broaden the knowledge of advanced endoscopy," said Patricia Vencill, nurse manager at Banner University Medical Center Phoenix. "Boston Scientific was instrumental in helping us develop this program and organize the event." In addition to planning, the Boston Scientific team provided devices for the hands-on training and several representatives were on site for the event to answer questions about the devices and other educational opportunities offered by Boston Scientific.



*At a Southern U.S. community medical center, a gastroenterologist explains how digital imaging using the SpyGlass™ DS System has changed his practice — benefiting patients, and economically, putting his facility on the cholangiopancreatography map.*

## The SpyGlass DS Direct Visualization System

***For one physician, clearer views are changing patient management***

**Mobile, Alabama gastroenterologist Matthew Eves, M.D., FASGE, FACG**, has a strong career interest in the latest tools and technologies to diagnose cancers earlier, and he uses endoscopy to treat patients more precisely, reducing risks with fewer procedures. But he also has a personal connection, having participated in the treatment of a close relative who recently succumbed to pancreatic cancer.

“When you get that close and you see from the patient’s perspective what life is like — experiencing side effects of medication or not getting the relief you’d expected — it drives you to improve the quality of what we do,” Dr. Eves said.

### **Eves sees an enormous potential for the SpyGlass DS System to help physicians diagnose cancers earlier.**

Endemic to the region’s residents are neuroendocrine tumors and cholangiocarcinomas, conditions that the SpyGlass DS System is able to help visualize. In the case of cholangiocarcinoma, Dr. Eves said, negative biopsies don’t necessarily mean there’s no cancer because in his experience, there’s an “almost 50-50 chance it was missed” during cytology brushing. He’s also seen bile duct masses on EUS results that looked like possible cancer but were later able to be ruled out using the SpyGlass DS System. Using the SpyGlass DS System, there’s potential to improve the accuracy of the diagnosis.

Furthermore, on the treatment front, **the clearer view has helped Dr. Eves and his colleagues more effectively stent biliary and pancreatic strictures, simply because they can see them better.** In many cases, the enhanced view using the SpyGlass DS System has helped Dr. Eves alter the management of his patients and has changed their course of treatment. In one particular case, the SpyGlass DS System revealed gallstones after previous tests suggested that a female patient’s liver tissue had been damaged to the point where she would have needed a transplant. After Dr. Eves cleared out the stones, the patient was able to receive stents and avoided transplant surgery.

Dr. Eves’ home base, the 689-bed Mobile Infirmary Medical Center, is affiliated with four other hospitals. He brought advanced endoscopy to the health system about 10 years ago. Now, three physicians in the practice are performing advanced procedures

such as endoscopic ultrasound (EUS) and cholangioscopy. As the health system’s practice generates awareness about the capabilities of the SpyGlass DS System to referring gastroenterologists in the triangular-shaped region between Montgomery, Ala., Tallahassee, Fla. and Gulfport, Miss., Dr. Eves envisions it as a way to expand their reach while — more importantly — helping patients.

The digital imaging capabilities of the SpyGlass DS System enable Dr. Eves’ team to provide results to referring physicians the same day that their patients’ procedures are performed — another benefit to the practice that helps improve service.

**“We are able to get results back to referring physicians and, in turn, follow up with patients much faster with the SpyGlass DS System,”** Dr. Eves said. “We take really high-quality pictures with the system and can send a picture that communicates volumes to the referring physician. It’s easy for them, too, as they can access the report and images from a website for us to discuss. They just log on and get the information they need.”

After incorporating the SpyGlass DS System into his practice, Dr. Eves has been able to see more detail, better distinguish strictures in the bile ducts and pancreas, and fragment stones all as an extension of an ERCP procedure. He believes, as the body of images and experience grows with continued adoption, there is an enormous potential for the SpyGlass DS System to help physicians diagnose cancers more accurately, remove masses more effectively and, ultimately change their treatment algorithm.

### ***The SpyGlass DS System was Recognized for Excellence in Product Innovation***

A panel of independent judges and editors of **R&D Magazine** named the SpyGlass DS Direct Visualization System as a finalist in the Analytical/Test category for its 2015 **“R&D 100 Awards,”** which honors the most technologically significant new products introduced in the past year. Winners will be announced in November in Las Vegas, Nevada.





# EUS-Guided Cyst-Gastrostomy Using the AXIOS Stent and Delivery System



CASE PRESENTED BY:

**WILLIAM J. SALYERS, JR., M.D. (Pictured)**  
**AND MICHAEL S. GREEN, M.D.**

Wesley Medical Center  
University of Kansas School of Medicine  
Wichita, Kansas, USA

## PATIENT HISTORY

A 55-year-old male with a history of pancreatitis complicated by pancreatic pseudocyst formation was referred to the outpatient gastroenterology clinic for endoscopic cyst management. The pancreatic cyst was first identified two years prior to presentation and the patient reported that initially after cyst formation he underwent evaluation for surgical resection but the lesion was found to be un-resectable due to fusion of tissue planes. Cyst analysis at that time was consistent with a benign pseudocyst. Over the subsequent two years prior to presentation to the GI clinic, the cyst was monitored conservatively with interval follow up imaging.

At the time of presentation to the GI clinic, the cyst was noted to be increasing in size up to 10 cm by 8 cm on interval follow up computed tomography (CT) imaging. The patient reported increasing nausea, vomiting, abdominal pain, and early satiety with recurrent hospitalizations due to the severity of his symptoms. Due to the increasing pseudocyst size with worsening symptoms, EUS-guided cystgastrostomy with AXIOS™ stent placement was performed.

## PROCEDURE

The procedure was performed with general anesthesia to minimize the risk of aspiration due to the large fluid volume that would enter into the gastric lumen following cyst decompression with stent deployment. The patient received levofloxacin 500 mg intravenously prior to the procedure. CO<sub>2</sub> was used for insufflation throughout the procedure.

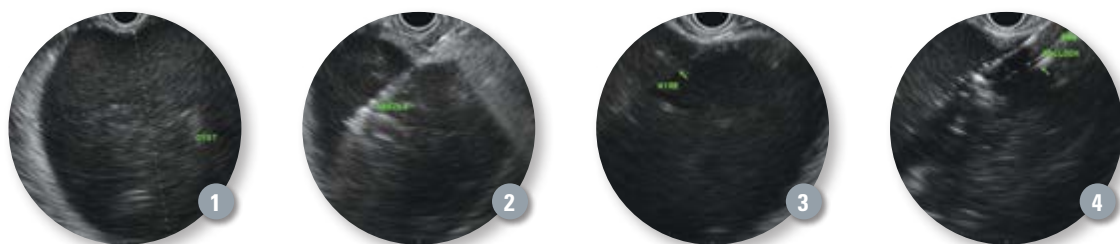Upper endoscopy was performed with an adult endoscope to first screen for gastroesophageal varices and none were found. An extrinsic impression was noted along the posterior wall of the gastric body consistent with the known pseudocyst, creating a mass effect on the gastric lumen. The upper endoscope was then exchanged for

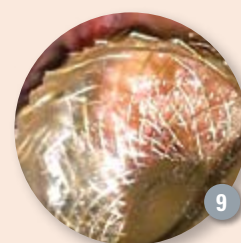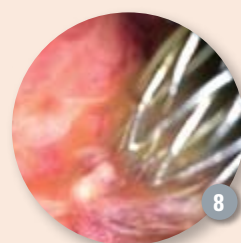
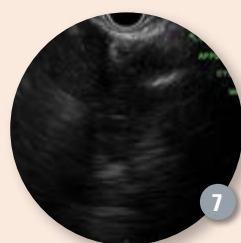
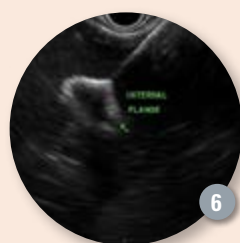
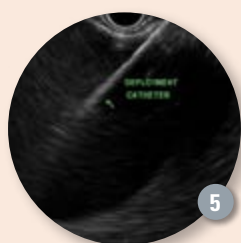
the linear echoendoscope. Echoendoscopic evaluation of the pancreatic pseudocyst revealed an anechoic lesion in the pancreatic body that was not in obvious communication with the main pancreatic duct. The cystic lesion measured up to 8.5 cm by 8.2 cm in maximal cross-sectional diameter within a single view (**Figure 1**). There was a small amount of internal debris present with the fluid-filled cavity. There was a single compartment with no septae present. The internal wall of the cyst cavity was confirmed to be less than 1 cm (measured at 5.4 mm) from the gastric lumen. Color Doppler imaging confirmed an absence of vascular structures within the needle path.

One pass was made into the cyst cavity with an EUS Needle (**Figure 2**) using the stylet with 5 ml of brown fluid collected and sent for analysis (CEA level, amylase, and cytology). A 450 cm by 0.035 inch Dreamwire™ High Performance Guidewire was then advanced through the needle into the cyst cavity (**Figure 3**) and allowed to coil several times under fluoroscopic guidance. The needle was then removed and a dilation balloon was advanced over the wire. Dilation was performed with the inflated balloon held in place across the cyst-gastrostomy tract for 60 seconds (**Figure 4**). The balloon was removed and the 15 mm diameter metal AXIOS Stent was advanced over the wire and secured into place at the echoendoscope hub.

## OUTCOME AND POST PROCEDURE

The patient was admitted for post-procedure observation and discharged 2 days after the procedure. He completed a 7 day course of levofloxacin 500 mg po once daily. On the first day post-procedure, he was started on clear liquids and advanced to a regular diet after 48 hours. Fluid analysis showed CEA and amylase levels that were consistent with the clinical diagnosis of a pseudocyst and cytology results were benign. He had no immediate or delayed post-procedure





### AXIOS™ Stent deployment was performed under echoendoscopic guidance using the 4 primary steps outlined below:

**Step 1) Advance the deployment catheter.** Unlock the catheter lock and push down on the AXIOS catheter hub (labeled “down-arrow 1”) to advance the deployment catheter deep within the cyst cavity until it nears the cyst wall farthest from the EUS probe (**Figure 5**). Lock the catheter lock once the deployment catheter is in the optimal location within the cyst cavity.

**Step 2) Deploy the first flange of the stent.** Remove the yellow safety clip that is located on the AXIOS Stent deployment hub. Unlock the stent lock and pull the stent deployment hub upward until it clicks into place at the white line just below the “up-arrow 2.” The first flange will be seen opening within the cyst cavity on the EUS image (**Figure 6**).

**Step 3) Withdraw the first flange of the stent into position apposing the inner cyst wall.** Unlock the catheter lock and pull the catheter hub (labeled “up-arrow 3”) upward until the first flange is brought into position apposing the inner cyst wall under echoendoscopic guidance. EUS imaging of the first flange position is critical throughout this step and the catheter should be

withdrawn until the first flange pulls up against the cyst wall forming a “football” shape (**Figure 7**). Lock the catheter lock once the first flange is in optimal location.

**Step 4) Deploy the second flange.** Proceeding to Step 4 on the AXIOS Deployment System handle, unlock the stent lock and pull the stent deployment hub upward to “up-arrow 4” to deploy the stent from the catheter system. Using the ‘EUS-guidance only’ method of AXIOS Stent placement, the stent will be deployed from the AXIOS Stent Delivery System within the working channel of the echoendoscope at this point. While keeping the internal flange positioned against the cyst wall, the echoendoscope is slowly withdrawn 1-2 cm with the elevator in the “open” position. The stent will come into the endoscopic view (**Figure 8**) as the deployed stent drops out of the working channel of the echoendoscope, allowing the proximal gastric flange to open in proper position in the gastric lumen, thus completing stent deployment (**Figure 9**). The AXIOS inner catheter along with the delivery system is then removed from the echoendoscope.

complications. Computed tomography performed 4 weeks after stent placement showed complete resolution of the cyst and he underwent upper endoscopy with stent removal 3 days later. The stent was removed using rat-tooth forceps without complications and the cystgastrostomy site was closed down to the size of only the internal flange at the time of stent removal. The patient has done well clinically without cyst recurrence and his pre-procedure symptoms resolved following stent placement with cyst decompression.

### CONCLUSION

AXIOS Stent placement for cyst-gastrostomy creation is a safe and effective method for pancreatic pseudocyst management. It provides quick access to the pseudocyst cavity for necrosectomy and debridement, and the large stent lumen diameter allows rapid resolution of the pancreatic cyst cavity. **These features may allow patients with pancreatic pseudocysts to be managed with shorter lengths of stay in the hospital.**



# Cholangioscopically Guided Diagnosis of Cholangiocellular Carcinoma in a Patient with Primary Sclerosing Cholangitis



CASE PRESENTED BY:

ALEXANDER DECHÊNE, M.D.

Dept. of Gastroenterology and Hepatology, University Hospital Essen, GERMANY

## PATIENT HISTORY AND ASSESSMENT

A 49-year-old patient with a long standing history of primary sclerosing cholangitis (PSC) and well compensated liver cirrhosis was seen at his regular six-month surveillance visit. He complained of recently developed fatigue and mild weight loss, and lab testing revealed increased cholestasis parameters. MRI and PET-CT showed no suspicious lesions in or outside of the liver.

Upon performing endoscopic retrograde cholangiography, the cholangiogram was comparable to previously performed examinations with irregular bordering of the common bile duct (CBD), dilated left hepatic ducts and marked peripheral rarefaction in the right hepatic ducts (**Figure 1**).

We decided to use the SpyGlass™ DS System to evaluate the biliary system for evidence of neoplastic disease.

## PROCEDURE

Upon performing the cholangioscopy, we found pathologic changes to the biliary epithelium in both the CBD and all intrahepatic ducts we evaluated (**Figures 2 and 3**). While proximally to the hilum, scar formation, spotty reddening and fibrin clouds indicated inflammatory changes, we saw a short section of the extrahepatic common bile duct with many tortuous frail vessels bleeding on contact (**Figures 4 and 5**). Although the ductal segment was not strictured, we decided to take biopsies using SpyBite™ Biopsy Forceps in the conspicuous segment both by withdrawing single biopsies with the forceps and by leaving a number of samples floating in the lumen and collecting them by extraction via the suction channel.

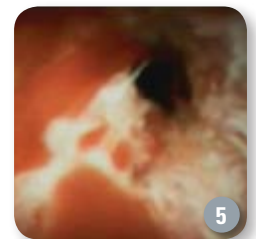
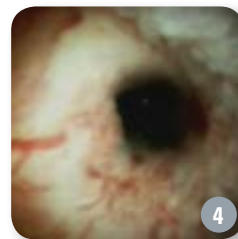
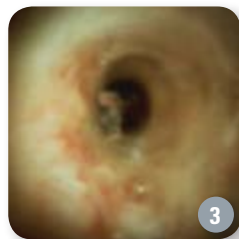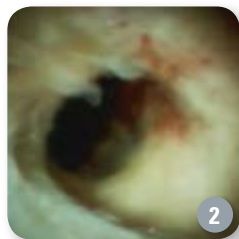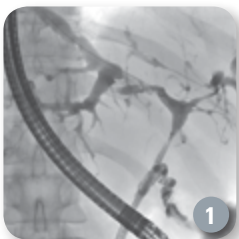## OUTCOME AND PATIENT FOLLOW-UP

Histologic examination of the retrieved tissue samples revealed adenocarcinoma, consistent with cholangiocarcinoma (CCC) arising from PSC. As the cross-sectional imaging showed no evidence of extraductal disease and liver function was stable, laparotomy was performed subsequently. Unfortunately, small peritoneal lesions indicated extraductal cancer spread and did preclude curative resection of the tumor. The patient had to be taken off the liver transplant waiting list and was offered chemotherapy as a palliative treatment.

## SUMMARY

Early diagnosis of cholangiocarcinoma in patients with PSC is a particularly challenging undertaking and there is no single or combined method with sufficient sensitivity today, most notably the widely practiced brush cytology. Cholangioscopy appears to be an attractive approach to evaluation of the larger intra- and extrahepatic bile ducts, but experiences with established systems have been disappointing because the distinction between inflammation and neoplasia is nearly impossible, and bioptic mapping of the biliary tract is usually not feasible.

**The first impressions of the visual quality of the SpyGlass DS System's image provided me with hope for an improvement in this regard and an approach to better identification of neoplastic intraductal lesions within inflammatory biliary changes, thus facilitating early diagnosis of CCC at a stage where curative resection is still an option.** The markedly improved possibility of diagnosing changes in vascular patterns with the SpyGlass DS System might be a key feature here.



## GENERAL RECOMMENDATIONS

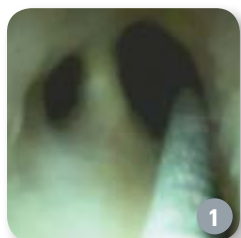- We use the SpyGlass DS System both for diagnostic purposes in patients with biliary strictures or filling defects, and for stone management. The increased visual quality — in my opinion — is the most important improvement made to the system.
- The easy and quick setup of the cholangioscope makes it possible to decide on using cholangioscopy mid-procedure without relevant delay.
- It is very possible to advance the cholangioscope deeply into intrahepatic ducts in most patients, even in diffuse biliary disease, so cholangioscopic evaluation is not limited to the central biliary ducts.
- The use of the SpyGlass DS System in the distinction between inflammatory changes and neoplastic disease has to be studied in depth but is worthwhile given the size of the problem.



# The SpyGlass DS Direct Visualization System Enabled a Definitive Diagnosis for a Patient who Had 12 Previous ERCPs



CASE PRESENTED BY:  
**RAJNISH MISHRA, M.D.**  
Gastroenterologist  
Swedish Medical Center  
Seattle, Washington, USA

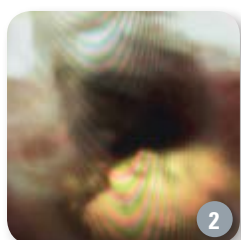


## PATIENT HISTORY AND ASSESSMENT

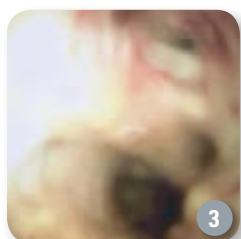The patient is a 46-year-old male with a history of PSC and a possible stricture in the left hepatic duct. At the time of referral, he had undergone 4 prior ERCPs dating from October 2014. He also had 8 ERCPs prior from a referring physician. There were no conclusive findings in 12 ERCPs.

## PROCEDURE

Cannulation was performed on the patient's papilla and a guidewire was passed into the patient's left hepatic duct. The cholangiogram looked similar to the last ERCP with a stricture just beyond the bifurcation in the left hepatic duct. A balloon sweep was conducted followed by an occlusion cholangiogram. The SpyGlass DS System's SpyScope™ was then passed over the wire and up to the bifurcation (**Figure 1**).

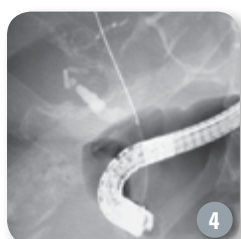

A 4mm stone was seen at the bifurcation (**Figure 2**). The stone was impacted into the duct and did not show up during cholangiogram. Suction was used on the SpyGlass DS System's Cholangioscope to attach the stone to the tip of the SpyGlass DS System and extract it from the bile duct into the duodenum. Visibility of the possible malignant stricture in the left hepatic duct became available through the SpyScope (**Figure 3**). I believed the stricture was benign but took five biopsies for confirmation. Utilizing the suctioning port on the SpyGlass DS System's Cholangioscope, the patient's risk for cholangitis was reduced by suctioning out the leftover contrast into a 60cc syringe (**Figures 4 and 5**).



## OUTCOME

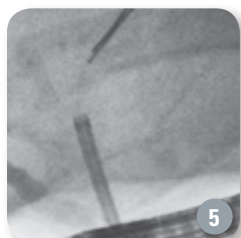
A 4mm stone was removed that had not previously been seen as the stone was impacted and had not shown under fluoroscopy. The stone was removed by suctioning it to the tip of the SpyGlass DS System and pulling the SpyScope into the small bowel. Contrast was removed from the patient's intrahepatic ducts, which decreases the risk of cholangitis. It was confirmed that the suspicious stricture was, in fact, malignant.



## CONCLUSION

Through the use of the SpyGlass DS System:

- The stricture was confirmed as being malignant, allowing me to confidently send the patient to surgery for an immediate liver transplant. Twelve previous ERCPs had not provided that information.
- A 4mm stone was removed from the patient's bile duct that he didn't realize was there.
- Leftover contrast was removed from the patient's intra-hepatic ducts, decreasing the risk for cholangitis.



# Using Direct Visualization to Help in Precise Diagnosis and Staging of Cholangiocarcinoma

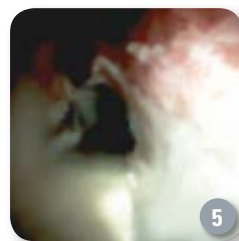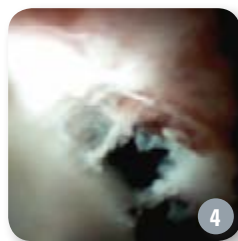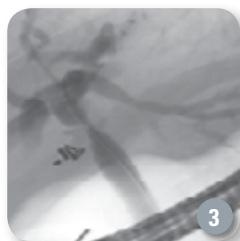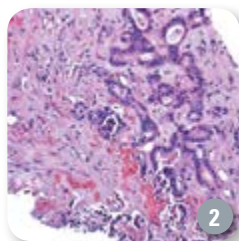


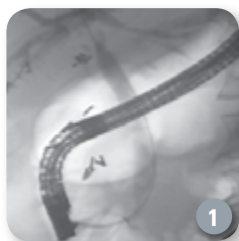CASE PRESENTED BY:

NEIL R. SHARMA, M.D., (Pictured)

Director of Advanced Interventional Endoscopy, Medical Director of GI Oncology Program, Physician Service Line Leader, Parkview Comprehensive Cancer Center, Volunteer Assistant Professor of Medicine, Indiana University, Indianapolis, Indiana, USA

SCOTT PATRICK HARRISON, 2nd Year Medical Student, Indiana University School of Medicine, Indianapolis, Indiana, USA



## PATIENT HISTORY AND ASSESSMENT

A 71-year-old male presented with one week of itching, jaundice and dark urine. He did not report having abdominal pain, but did have some mild abdominal cramping with bowel movements. His stools became light in color, but otherwise no change in his bowel movements. He did not experience weight loss, nausea, or vomiting. His mother died of liver cancer at age 63. No family history of pancreatic disease.

## PROCEDURE

The patient underwent lab work and a CT scan of his abdomen and pelvis. The CT scan revealed, "Significant intrahepatic biliary ductal dilation. The findings suggest biliary obstruction. The common duct does not appear significantly dilated. There is an ill-defined mass-like density within the right hepatic lobe extending inferiorly toward the region of the bifurcation of the right and left hepatic ducts."

He underwent conventional ERCP. Per the ERCP report, "Normal papilla with a tight stricture of the CHD obliterating the bifurcation with proximal dilation of the right and left hepatic ducts. Normal CBD distal to stricture." Brush cytology was performed, but was negative for cholangiocarcinoma (Figure 1).

He was referred to interventional radiology for percutaneous biopsy of the right liver mass. The biopsy revealed, "Well to moderately differentiated adenocarcinoma." Stains were consistent with either pancreaticobiliary or upper GI adenocarcinoma (Figure 2).

He was set up in our advanced interventional endoscopy and GI oncology program for further evaluation. I reviewed the CT scan. A PET scan was ordered as well, which revealed no additional lesions outside of the right side liver mass.

We then reviewed the case at our multidisciplinary Tumor Board. Options included palliation with biliary stent placement and chemotherapy, or an attempt at curative resection by hepatobiliary (HPB) surgery. The patient preferred aggressive treatment for a possible cure. HPB surgery felt the disease could be cured with right

hepatectomy and resection of the hilum if the disease did not involve the distal bile duct or the secondary radicals in the left biliary system. HPB surgery wanted to know if it was possible to precisely map the biliary system, and see if the disease extended up the left main hepatic duct into the secondary radicles. If we could prove no extension of the disease into the secondary radicals, he would be taken for resection. Otherwise, palliative treatment would be pursued.

Patient was set up for ERCP with an evaluation using the new SpyGlass™ DS System (Figure 3). We were able to identify the exact margins of the tumor within the bile ducts using the Spyglass DS System. We have extensive experience with the first-generation SpyGlass System, and immediately noted improvement in function and image resolution (Figure 4).

## OUTCOME

The SpyGlass DS System demonstrated an intraductal tumor extending from the right main hepatic duct down to the proximal CBD (Figure 5). The left main hepatic duct was involved, but the tumor did not extend up the left main hepatic duct into the secondary radicals. The fact that the secondary radicals were not involved allowed the patient to go for surgical resection. He was taken to surgery. He underwent right hepatectomy and the left main hepatic duct, the bifurcation, and the common hepatic ducts were resected with negative margins. Surgical margins confirmed accurate staging by the SpyGlass DS System.

## SUMMARY

Brush cytology has low sensitivity for diagnosis of cholangiocarcinoma in the setting of biliary stricture. **The SpyGlass DS System should be the gold standard for determination of intraductal margins which allow for precise staging of cholangiocarcinoma. The use of the SpyGlass DS System can change patient management when used in the preoperative workup of cholangiocarcinoma.** The use of the SpyGlass DS System can help stratify patients to appropriate surgical management and avoid it when not necessary.

# Using the SpyGlass DS Direct Visualization System for Diagnosis and Treatment of Biliary Duct Lesions

*First Report from Latin America*



CASE PRESENTED BY:

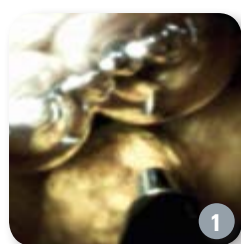**CARLOS ROBLES-MEDRANDA, M.D.**

Instituto Ecuatoriano de Enfermedades Digestivas (IECED), University Hospital OMNI, Guayaquil, ECUADOR



**ROBERTO GUGIG, M.D.**

Children's Hospital, Central California Madera, California, USA

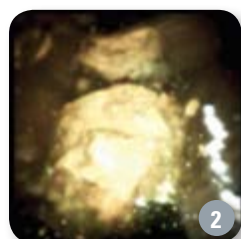


## PATIENT HISTORY

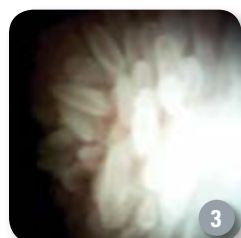In this case, we treated an 81-year-old female with a large common bile duct stone > 2 cm, who had undergone a previous endoscopic retrograde cholangiopancreatography (ERCP), with a plastic stent placement (10 Fr by 10 cm), and who returned 3 months later for electrohydraulic lithotripsy.

## PROCEDURE

In June 2015, we performed an ERCP and cholangioscopy using the new SpyGlass™ DS System for electrohydraulic lithotripsy.



After the cholangiography and removal of the plastic stent, we introduced the SpyScope™ DS over-the-wire that easily allowed direct visualization of the stone (**Figures 1 and 2**). In addition, a tissular lesion was detected, proximal to the stone that was not seen during cholangiography (**Figure 3**).



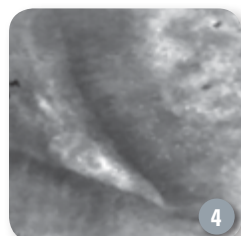
In our unit, previously cholangioscopy was performed on other patients using the first-generation, fiberoptic SpyGlass System. Comparing both systems, we observed many important advantages using the new SpyGlass DS System: **1**) the total procedure time was considerably reduced to 15 minutes. This is without a doubt associated with the way the equipment is mounted and the improved quality of the images; **2**) the quality of image allowed for better characterization of the biliary tract wall; **3**) less water irrigation; and **4**) an easier way to introduce the SpyBite™ Biopsy Forceps or other catheters as confocal laser endomicroscopy probe (p-CLE) or electrohydraulic probes when compared with the older system.

We performed confocal laser endomicroscopy of the lesion (**Figure 4**), confirming the presence of a cholangiocarcinoma, obtaining directed optical biopsies from the lesion and then performing lithotripsy for removal of the stone.

## CONCLUSION AND PATIENT OUTCOME

Large stones remain a big challenge during ERCP procedures. In these types of cases, it is not possible to remove the stones using only the standard techniques (sphincterotomy with extraction devices as baskets, or retrieval balloons).

By using the SpyGlass DS System, electrohydraulic lithotripsy can be applied directly to the surface of the stone in a simple way, preventing injury to the wall of the common bile duct.



Furthermore, this case illustrates the limitation of cholangiography in identifying small lesions within the lumen of the bile ducts, and how the use of the SpyGlass DS System changed the approach and management of this patient by detecting a small neoplastic lesion due to direct visualization and the ability to perform confocal laser endomicroscopy for optical biopsy as well as target sample tissue during the procedure. After the procedure, the patient was discharged in good condition and was referred to surgery.

**Finally, it is important to remark that this new cholangioscope showed an important technological advance with simplified use, an impact in the time and quality of the procedure, and probably an important impact for patients and medical staff, reducing the use of fluoroscopy as well as water infusion (risk of cholangitis) during the procedures.**



# Endoscopic Mucosal Resection can Help Accurately Stage and Treat Early Esophageal Cancers



CASE PRESENTED BY:

**REHAN HAIDRY, M.D., (Pictured)**

Consultant Gastroenterologist,  
University College Hospital  
London, ENGLAND

**GIDEON LIPMAN, M.D.**

Clinical Research Fellow  
University College Hospital, London, ENGLAND

## PATIENT HISTORY

A 57-year-old female was referred for assessment following a routine upper endoscopy for symptoms of GERD. A nodular area within a segment of Barrett's epithelium was found and biopsies showed high-grade dysplasia with features suggestive of invasive adenocarcinoma with moderate differentiation. A CT scan of her chest, abdomen and pelvis demonstrated no evidence of metastases. Radial EUS demonstrated no nodal disease and no deep invasion. She was otherwise fit and well with a history of successfully treated breast cancer and a cholecystectomy.

Following discussion with the patient regarding surgical and endoscopic options available to her, an endoscopic mucosal resection (EMR) was performed to remove the lesion but also to get accurate histopathological staging. Superficial tumors confined to the mucosa can be treated endoscopically with mucosal resection followed by radiofrequency ablation for the residual Barrett's. However, if the EMR tissue pathology showed submucosal invasion, it would require definitive surgery due to the risk of lymphovascular metastasis.

## PROCEDURE

A gastroscopy was performed and a tongue of columnar lined esophagus (Barrett's epithelium) was identified with a proximal nodule, a Paris 1a lesion, on the posterior wall (**Figure 1**). The mucosal pattern was abnormal with dilated and irregular blood vessels (**Figure 2**).

A submucosal saline injection raised the lesion with a KATO I lift and wide resection margins were marked with the snare tip and diathermy of the 15mm hexagonal snare included with the Captivator™ EMR Device (**Figure 3**). Two overlapping resections were performed with the ligating head of the Captivator EMR Device with no immediate complications (**Figures 4 and 5**). Both resection specimens were retrieved and sent for histological assessment.

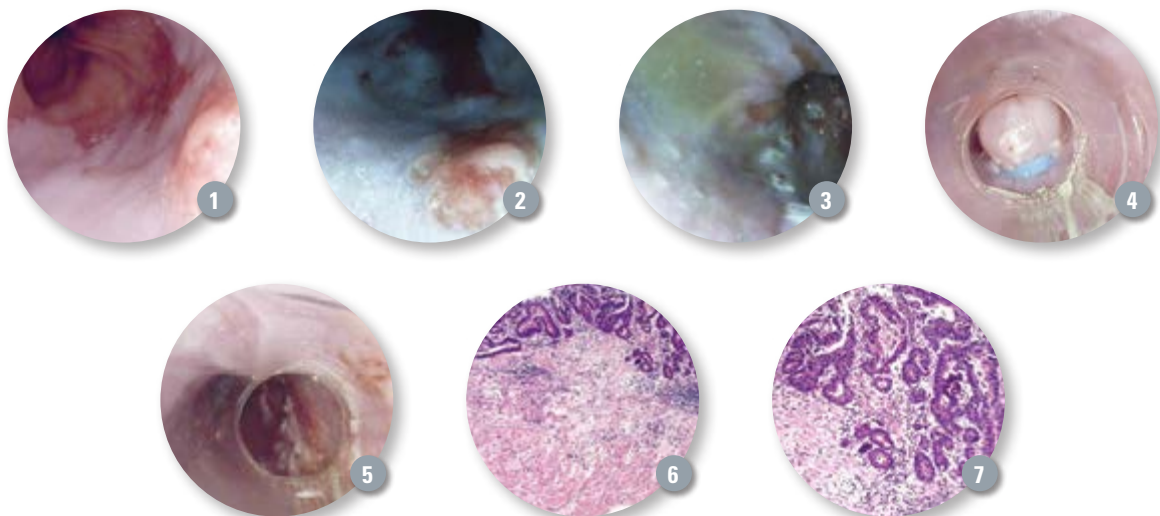
## OUTCOME / POST-PROCEDURE

Histology demonstrated a moderately differentiated adenocarcinoma (G2M2) with clear deep resection margins (R0 resection) and no lympho-vascular invasion (**Figures 6 and 7**).

The patient is due for a repeat endoscopy to assess the resection site and have the remaining Barrett's epithelium treated with radiofrequency ablation to reduce the risk of developing further lesions.

## CONCLUSION

**This case highlights how endoscopic resection with the new Captivator EMR Device can be used for tissue removal in early esophageal cancers. Endoscopic resection of these early tumors is highly desirable to avoid more invasive surgery with esophagectomy or disease progression.**



# T1a Esophageal Adenocarcinoma Within Barrett's Esophagus: Endoscopic Resection Using the Captivator EMR



CASE PRESENTED BY:

**CARLOS G. MICAMES, M.D.**

Hospital Bella Vista  
Mayagüez, PUERTO RICO

## PATIENT HISTORY

A 71-year-old male with longstanding GERD was referred for evaluation of an early esophageal adenocarcinoma identified during routine surveillance endoscopy for Barrett's esophagus. He denied dysphagia, melena or weight loss, and his GERD symptoms were well controlled with once-daily proton pump inhibitor.

## PROCEDURE

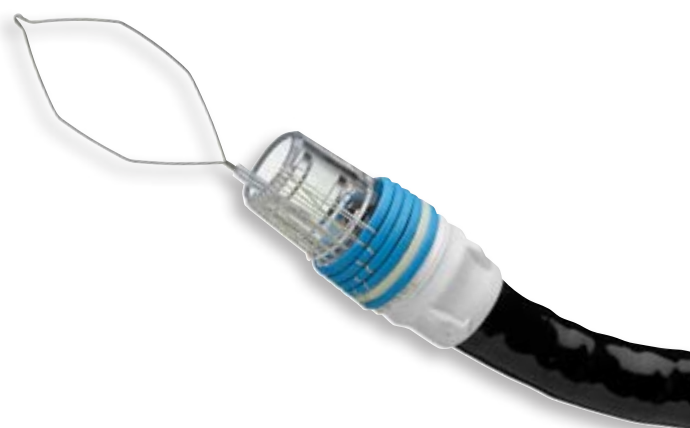
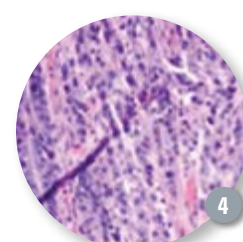
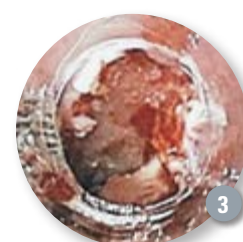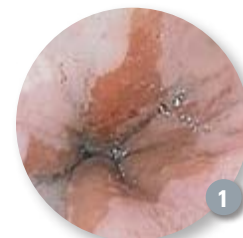Examination using a high-definition upper endoscope revealed a C1M4 segment of Barrett's esophagus. A 10 mm area of increased erythema and friability was identified (**Figure 1**). An irregular pattern was identified using narrow band imaging (**Figure 2**). Its size and location close to the GE junction favored resection via endoscopic mucosal resection (EMR). The Captivator EMR Device offered a clear view for sequential resection of the lesion, reducing the likelihood of residual neoplasia (**Figure 3**). Two resection specimens were submitted using the cassette trays included with the kit, which prevents "curling" of the tissue, facilitating assessment of the margins.

## OUTCOME / POST-PROCEDURE

Pathology revealed the presence of intramucosal adenocarcinoma and high-grade dysplasia in a background of intestinal metaplasia (**Figure 4**). Adenocarcinoma reached, but did not traverse, muscularis mucosa (T1a). Deep margins of resection were clear of neoplasia. No lymphovascular invasion was identified. No adverse events occurred associated with the EMR. The patient will undergo surveillance endoscopy in three months with the intention to ablate the remaining intestinal metaplasia with radiofrequency ablation.

## CONCLUSION

This case highlights the current approach for the management of superficial or early esophageal adenocarcinoma. Endoscopic techniques available include thermal ablation and resection. Endoscopic resection has the advantage of completely removing the neoplastic lesion with a high success rate and low risk of adverse events, and acquires tissue for accurate histologic staging. Endoscopic resection can be performed by EMR ligation or by endoscopic submucosal dissection (ESD). **EMR is effective for eradicating mucosal cancer and high-grade dysplasia in Barrett's esophagus with the advantage of having fewer complications (bleeding, perforation and strictures) and being less time-consuming than ESD.**



# EUS-FNA: Wet Suction Technique



CASE PRESENTED BY:

**BRIAN RAJCA, M.D.**

Associates in Digestive Health  
Cape Coral Hospital  
Cape Coral, Florida, USA

## BACKGROUND

Endoscopic ultrasound-guided fine-needle aspiration (EUS-FNA) has been widely utilized to diagnose a range of gastrointestinal diseases.<sup>(1,2)</sup> The literature surrounding EUS-guided FNA techniques generally involves the use of a needle, with or without suction, or a slow-pulling technique with the stylet<sup>(3,4,5)</sup>. Despite a number of articles on FNA techniques<sup>(1-5)</sup>, the optimal technique of EUS-guided sampling for pathologic diagnosis has not been clearly established in the literature.

Recently, Attam and colleagues published a study on the novel technique using wet suction (also known as a hybrid technique) versus conventional air suction when sampling solid lesions. The aim of the study was to detect an improvement in the quality of specimen obtained during FNA with the wet suction technique compared to a stylet based technique<sup>(1)</sup>. The results of this prospective, randomized study yielded statistically significant improvement not only in cellularity but also an increase in specimen adequacy from 75.2% to 85.5% ( $p=0.035$ ). Further follow-up studies have been suggested to compare the wet suction technique with different needle sizes and also to involve pathologic grading of the FNA specimen.

## CASE REPORT

We report a case of a 77-year-old patient who presented with obstructive jaundice secondary to a distal bile duct stricture. Due to the concern of a pancreatic head mass on imaging, an EUS was performed which confirmed a 2.1 cm by 1.9 cm hypoechoic mass in the head of the pancreas. A 22 gauge Expect™ Slimline was chosen for the FNA and a novel “hybrid wet suction” technique was utilized for the first time at this institution. In preparation for the FNA, the stylet was removed and 5 cc of saline was used to prime the 22 gauge FNA needle. A vacuum syringe was then set at 20cc with the lure lock in the closed position. The saline syringe was removed and the closed vacuum syringe attached to the FNA needle. Using

standard techniques, the pancreatic mass was accessed and suction was turned on. Using ultrasound guidance in an avascular plane the needle (**Figure 1**) was actuated 10 to 12 times in 2 to 3 different planes to achieve adequate fanning through the mass. Throughout the pass, clear saline could be seen collecting in the vacuum syringe suggesting adequate tissue was being obtained. When the pass was complete, suction was turned off and the needle withdrawn. This process was repeated and a total of four passes were made.

## SLIDE AND CELL BLOCK PREPARATION

To prepare the slides, a drop of aspirate was expressed onto a slide and fixed with 95% alcohol for Papanicolaou stain. The remainder of the aspirate was expressed into a formalin bottle for preparation of the cell block. Any visible core was removed from the slide using a “needle tip” and placed into formalin for the cell block.

## PATHOLOGY RESULTS

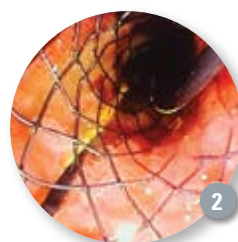
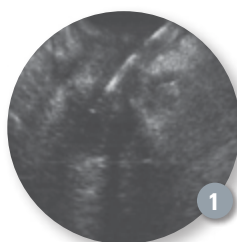

**DIAGNOSIS:** Pancreas, mass, fine needle aspiration: Positive for adenocarcinoma (see comment).

**COMMENT:** Intradepartmental consultation obtained with agreement.

**MICROSCOPIC EXAMINATION:** A microscopic examination was performed to render the above diagnosis.

## IMPLICATIONS FOR FNA SAMPLING

**The “hybrid wet suction” technique can be easily introduced as a new method for FNA in the community setting.** The technique was successful and produced a positive diagnosis of pancreatic adenocarcinoma. The patient was brought back for an ERCP and a palliative WallFlex™ Biliary Stent (**Figure 2**). Getting a quick and accurate diagnosis can expedite the management of patients with advanced biliary disease.



## References:

- <sup>1</sup>Attam, R, Arain M.A., Bloechl S.J., et al. “Wet suction technique (WEST)”: a novel way to enhance the quality of EUS-FNA aspirate. Results of a prospective, single-blind, randomized, controlled trial using a 22-gauge needle for EUS-FNA of solid lesions. *Gastrointest Endosc.* 2015; 81(6): 1401–1407.
- <sup>2</sup>Wallace, Michael B. et al. Randomized controlled trial of EUS-guided fine needle aspiration techniques for the detection of malignant lymphadenopathy. *Gastrointest Endosc.* 2001; 54(4): 441–447
- <sup>3</sup>Puri, R., Vilman, P., Saitou, A. et al. Randomized controlled trial of endoscopic ultrasound-guided fine-needle sampling with or without suction for better cytological diagnosis. *Scand J Gastroenterol.* 2009; 44: 499–504.
- <sup>4</sup>Lee, J.K., Choi, J.H., Lee, K.H. et al. A prospective, comparative trial to optimize sampling techniques in EUS-guided FNA of solid pancreatic masses. *Gastrointest Endosc.* 2013; 77: 745–751.
- <sup>5</sup>Nakai, Y., Isayama, H., Chang, K.J. et al. Slow pull versus suction in endoscopic ultrasound-guided fine-needle aspiration of pancreatic solid masses. *Dig Dis Sci.* 2014; 59: 1578–1585.

**Warning:** The safety and effectiveness of the WallFlex Biliary RX Stent for use in the vascular system has not been established.



## .018" Guidewire Used to Cannulate a Stenotic Minor Papilla Orifice



CASE PRESENTED BY:

**MARTIN L. FREEMAN, M.D., FACG, FASGE**

Professor of Medicine  
Chief, Division of Gastroenterology,  
Hepatology and Nutrition  
University of Minnesota, Minnesota, USA

### PATIENT HISTORY

A 54-year-old female was referred for recurrent episodes of epigastric/right upper quadrant pain radiating to the back since cholecystectomy, with at least one episode of acute pancreatitis. She was post biliary sphincterotomy. An MRCP with secretin showed a small ventral duct with a tight ansa loop joining to a dorsal dominant duct of Santorini with the majority of pancreatic juice drainage through the minor papilla, essentially a variant of pancreas divisum. The plan was to do a minor papillotomy and temporary dorsal pancreatic duct stenting.

### PROCEDURE

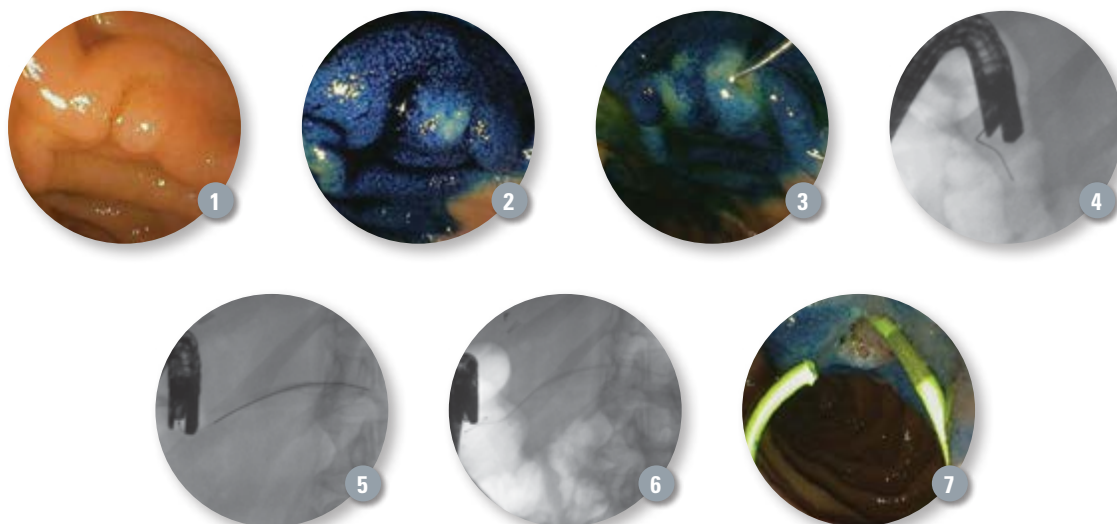
Under general anesthesia, using a high-resolution duodenoscope, the minor papilla was likely — but not definitively — identified, and no orifice visualized (**Figure 1**). Methylene blue spray outlined a very small minor papilla with a stenotic orifice (**Figure 2**). Before any contact was made with the minor papilla, an 0.018" NovaGold™ Guidewire was loaded through a Contour™ 5-4-3 Catheter pre-flushed with contrast via a side arm adaptor. Then using pure wire cannulation technique without any catheter touch, the wire was passed into the orifice of the minor papilla (**Figure 3**). Initial fluoroscopy showed the wire angling downward, likely into a side branch leading to the uncinate process rather than the main pancreatic duct (**Figure 4**). With the 5-4-3 catheter advanced over the wire just into the minor papilla orifice, a minimal amount of contrast outlined the main pancreatic duct, and the wire was redirected into the tail of the dorsal duct (**Figure 5**). A 3Fr single pigtail 11cm unflanged Advanix™ Pancreatic Stent was placed over the wire (**Figure 6**) and the NovaGold Guidewire was then removed. Due to the very small size of the duct, a limited minor papillotomy was performed using a needle knife (**Figure 7**).

### POST PROCEDURE

At 2 hours post procedure, the patient had a normal serum lipase and amylase, but was admitted overnight for observation as she had some nausea. She did not develop post-ERCP pancreatitis and was discharged from the hospital the next day.

### CONCLUSION

**The NovaGold Guidewire represents a significant contribution to guidewire technology for the pancreatobiliary system, especially small pancreatic ducts, and seems to be particularly useful for minor papilla cannulation.**



# Prophylactic Application of Resolution Clips after Gastric Polypectomy in Patient on Anticoagulation Medication



CASE PRESENTED BY:  
**PETER V. DRAGANOV, M.D.**  
 Professor of Medicine  
 University of Florida  
 Gainesville, Florida, USA

## INTRODUCTION

Benign gastric polyps can cause chronic gastrointestinal bleeding and lead to anemia. Removal of gastric polyps has been known to be associated with an increased risk of delayed post-polypectomy bleeding.

## PATIENT HISTORY

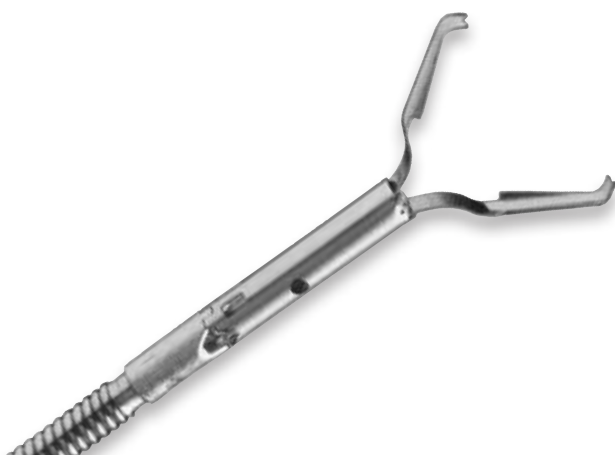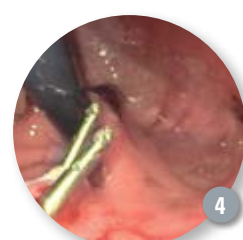
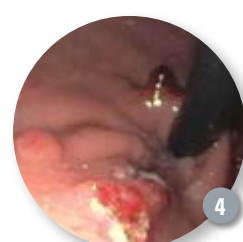
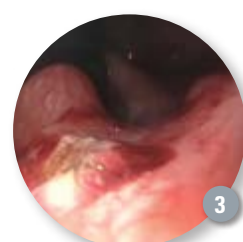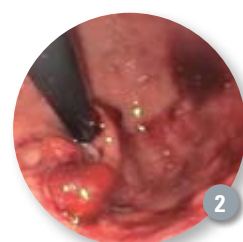
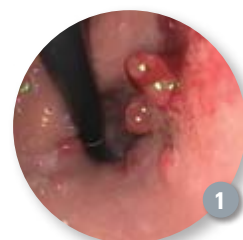This is a 64-year-old male who was found to have iron-deficiency anemia. A hemocult test was positive but there was no evidence of overt bleeding. Colonoscopy was unremarkable. The patient underwent upper endoscopy and was found to have two 6mm polyps in the cardia that were oozing blood on contact. Biopsy of the polyps showed hyperplastic changes. The patient was referred to our institution for polyp removal since he was considered a high risk for delayed post-polypectomy bleeding due to the location of the polyps and the fact that he needed ongoing anticoagulation for a coronary stent placed six months ago.

## PROCEDURE

An upper endoscopy was done with enoxaparin SQ bridge after discontinuing warfarin for five days prior to the procedure. Two 6mm polyps were noted in the cardia. The polyps were spontaneously oozing blood (**Figures 1 and 2**). A standard snare polypectomy was performed and there was no immediate bleeding after the polypectomy (**Figures 2, 3 and 4**). A prophylactic application of two Resolution™ Clips at the polypectomy site was done in retroflex endoscope position (**Figure 5**). Warfarin was restarted the evening after the procedure. No delayed post-procedure bleeding was observed.

## DISCUSSION

Gastric polyps are known to be associated with a high rate of delayed post-polypectomy bleeding. Furthermore, in this particular patient, anticoagulation was needed to be restarted immediately after the procedure due to the presence of a cardiac stent. Therefore, after performing the polypectomy we placed two Resolution Clips as a prophylactic measure to decrease the risk of delayed post-polypectomy bleeding. Placement of the clips was easily accomplished, even in what is considered a difficult location in the cardia working in the retroflex view. Warfarin was restarted the day of the procedure and the patient had no further episodes of bleeding after the procedure.



# Treatment of Suspected Neoplastic Stricture in the Right Hepatic Duct with WallFlex Biliary RX 6mm Diameter Stents



CASE PRESENTED BY:

URBAN ARNELO, M.D., PH.D.

Karolinska University Hospital  
Centre for Digestive Diseases  
Stockholm, SWEDEN

## PATIENT HISTORY

A 77-year-old man with hypertension was admitted acutely and operated on due to a ruptured abdominal aortic aneurysm. Recovery was very slow and was hampered by additional abscesses which required drainage procedures. One month later, the patient developed jaundice. CT and ERCP demonstrated a short stricture in the right hepatic duct. Neoplastic origin could not be ruled out. The stricture was dilated using a Hurricane™ Dilatation Balloon (6mm) and bridged by a 8.5F (2.83mm) Advanix™ Biliary Plastic Stent (**Figures 1a and 1b**). Brush cytology was inconclusive. Due to poor response on cholestasis, a repeat ERCP was performed two weeks later.

## DESCRIPTION OF PROCEDURE

After cannulation using a Hydratome™ RX Cannulating Sphincterotome, two Hydra Jagwire™ High Performance Guidewires were inserted in the left and right hepatic ducts respectively (**Figures 2a and 2b**). New brushings using RX Wireguided Cytology Brushes were taken and I decided to remove the Advanix Biliary Plastic Stent and replace it with two WallFlex™ Biliary RX 6mm diameter and 80mm length fully covered, self-expandable metal stents to provide drainage. The first stent was placed on the right hepatic duct (**Figures 3a and 3b**) and the second one was positioned in the left hepatic duct (**Figures 4a and 4b**). Deployment process of both stents was smooth and easy.

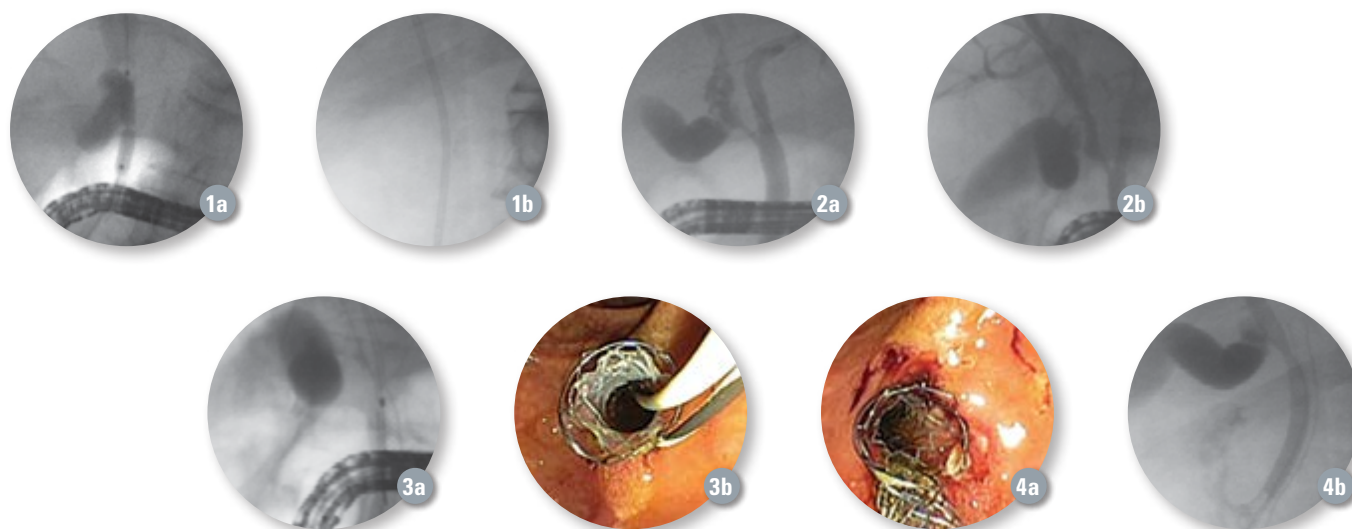
## OUTCOME

The origin of the stricture is still unclear. The brushings following the second ERCP showed atypic cells but FISH (fluorescence in situ hybridization) did not indicate aneuploidy. Bilirubin levels have been normalized. The patient is still recovering from his initial surgery.

## CONCLUSION

Due to the small diameter of the biliary duct, a WallFlex Biliary RX 6mm Stent was chosen to provide drainage.

In addition, in the European Union (and certain other regions of the world), the WallFlex Biliary RX Fully Covered Stent may be used in the treatment of benign strictures. The stent may be removed from benign strictures following indwell of up to 12 months.\*



\*Use of the stent in the treatment of benign strictures has not been cleared by the U.S. FDA. Check with your local sales representative for more information and availability.

**Warning:** The safety and effectiveness of the WallFlex Biliary RX Stent for use in the vascular system has not been established.



## News and New Devices

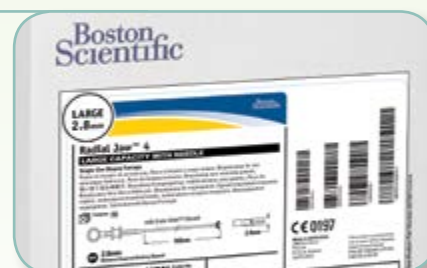- The **NovaGold™ High Performance Guidewire** offers durability and visibility in an .018" guidewire. The Triton™ Alloy Core provides a durable wire for working with accessory devices. Its stiffness makes the wire pushable yet flexible for loading and rail support through the scope to facilitate device exchange. The radiopaque guidewire tip is designed to help confirm location within the duct under fluoroscopy. Read Dr. Martin Freeman's case study on p. 19.



- Designed for comfort, the **EndoVive™ 3s Low Profile Balloon Kit** addresses the everyday issues that impact patients living with a feeding tube device. The pancake shape of the balloon helps the surface area to be flush against the gastric wall, helping improve retention and reducing the possibility of leakage of gastric contents to the skin level. It is indicated for use in both pediatric patients and active adults. A registered nurse call line is available for patients and caregivers, 24 hours a day, seven days a week.

### ➤ Boston Scientific's Endoscopy Business Completes GSI/GTIN Transition

As of August 2015, Boston Scientific's Endoscopy business completed its GS1/Global Trade Number (GTIN) transition. GS1 are the most widely used supply chain standards in the world and GTINs adhere to these standards to serve as globally unique identification numbers as an item in the supply chain moves from manufacturing through distribution and use. As GTIN is adopted and implemented within the medical device industry, a range of potential benefits could be realized, including improved inventory management, product tracking for estimating deliveries and calculating the cost of devices used per procedure. For customers who do not scan bar codes, the UPN will remain on the label for their continued use. Customers may send questions to **GS1CustomerInquiries@bsci.com**.



### Boston Scientific Receives Healthcare Supplier Award

Boston Scientific has been recognized by the Healthcare Transformation Group (HTG) for supplier excellence. The HTG award recognizes a supplier who serves as a leader in the adoption of GS1 Standards.

*Learn more about these and other endoscopy devices at [www.bostonscientific.com/gastro](http://www.bostonscientific.com/gastro).*

The paper used for this product catalog has been produced in accordance with:



ACCESS magazine was produced in cooperation with several physicians. The procedures discussed in this document are those of the physicians and do not necessarily reflect the opinions, policies or recommendations of Boston Scientific Corporation or any of its employees.

Results from case studies are not predictive of results in other cases. Results in other cases may vary.

Indications, Contraindications, Warnings and Instructions for Use can be found in the product labeling supplied with each device.

**Caution: Federal (U.S.) law restricts this device to sale by or on the order of a physician.**

**CAUTION: The law restricts these devices to sale by or on the order of a physician. Information for the use only in countries with applicable health authority product registrations. Information is not intended for distribution in France.**

All trademarks are the property of their respective owners.

The NovaGold Guidewire is distributed by Boston Scientific Corporation, Marlborough, Massachusetts; manufactured by NeoMetrics Inc., Plymouth, Minnesota.

© 2015 Boston Scientific Corporation or its affiliates. All rights reserved.

DINEND2349EA

ENDO-344312-AA October 2015

**Boston  
Scientific**