

Sponsored by Boston Scientific Corporation

Early Experience With Peripheral Rotablator Atherectomy

A Cost-Effective Solution for Calcium

BY SONYA S. NOOR, MD

Revascularization with endovascular therapy has become an accepted mainstay of treatment by most interventionalists. However, the Achilles' heel with all peripheral interventions remains long, calcified lesions both above and below the knee. The concern with these lesions is the ability to remove or displace calcium to allow luminal gain while preventing dissection, perforation, and embolization.

Atherectomy has grown in popularity because of its ability to debulk lesions without causing much barotrauma. This changes the vessel's compliance and, in some cases, enables a stent-free approach, which is very helpful in the treatment of recurrent disease. Atherectomy is now widely used both in the femoro-popliteal and below-knee vessels with varied results, and multiple devices are FDA approved and available.

A new addition to the group of approved atherectomy devices is the Peripheral Rotablator Rotational Atherectomy System (Boston Scientific Corporation, Natick, MA). We have used this device in both above-knee and below-knee cases that are described in this article. Because of the small caliber of tibial vessels and their characteristic tightly stenotic and occlusive lesions, the forward-cutting burr handles the plaque well by spinning on the wire in a concentric, controlled manner as it ablates the lesion. For this reason, as our experience grows, Peripheral Rotablator Atherectomy is becoming a first-line therapy for our patients with calcified tibials.

OVERVIEW OF THE PERIPHERAL ROTABLATOR SYSTEM

The Rotablator System has been a proven and effective tool for modifying lesion compliance in calcified lesions in the coronary circulation for more than

20 years. The air-driven system (Figure 1A) features a 5- μ m diamond-tipped burr (Figure 1B) that rotates at up to 190,000 RPM and ablates plaque into microparticles smaller in size than a red blood cell, eliminating the need for distal protection. The burr differentially sands inelastic tissue and plaque while deflecting away from normal vascular tissue, analogous to shaving with a razor. The diamond-tipped burr spins concentrically on the wire, providing confidence during ablation and a predictable lumen size. The burr engages the lesion immediately with its front cutting surface, enabling precise control and facilitating treatment of tight or occluded lesions. Peripheral RotaLink™ Plus Burrs are currently available in a range of diameters from 1.25 to 2.50 mm, offering a working length of 135 cm (Table 1). Peripheral RotaWire™ Guidewires are available in either floppy or extra support, featuring a working length of 330 cm, and RotaGlide™ Lubricant is available to reduce heat generation during rotation of the burr.

STEPS OF THE PROCEDURE

After diagnostic angiography confirms the site of the lesion, the lesion is traversed with a RotaWire Guidewire. In the case of occlusions, the occlusion is crossed in standard fashion, and the RotaWire Guidewire is placed. The RotaLink Plus Catheter is

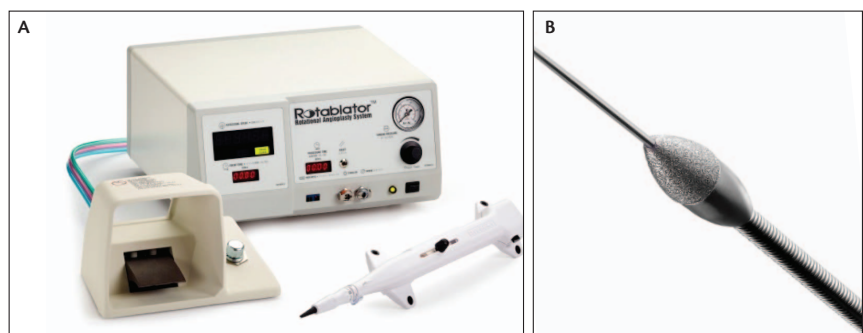


Figure 1. Rotablator Console with foot pedal and the Peripheral RotaLink Plus Burr Catheter (A). Peripheral RotaLink Plus Burr over a Peripheral RotaWire Guidewire (B).

Common Considerations for Rotablator Rotational Atherectomy System

- Limit RPM drop to under 5,000 RPM
- Limit ablation runs to 15–30 seconds
- Aim for plaque modification with adjunct PTA
- Add RotaGlide™ Lubricant, verapamil, and nitroglycerin to saline solution

then selected according to the size of the vessel to be treated. Based on coronary literature, the STRATAS study recommends a final burr-to-artery ratio of 0.70.¹ A saline solution, inclusive of RotaGlide Lubricant, verapamil, and nitroglycerin, is mixed and connected to the RotaLink Plus Catheter to reduce heat generation and vasospasm during ablation.²

The RotaLink Plus Catheter is placed over the RotaWire Guidewire, and the system is tested outside of the sheath to confirm a constant drip of saline solution, burr rotation, advancer knob movement, and wire brake activation. The free-lumen rotational speed of the burr should be about 160,000 RPM. The burr is activated by depressing the foot pedal, and the advancer knob is used to advance the burr. Ablation time is limited to approximately 30 seconds with intermittent pullback for perfusion to facilitate distal flushing of the

TABLE 1. PERIPHERAL ROTALINK™ PLUS BURR SHEATH SIZING

| Peripheral RotaLink Plus Burr (mm) | Minimum Recommended Introducer/Guide Sheath Size* |
|------------------------------------|---|
| 1.25 | 5 F |
| 1.50 | 5 F |
| 1.75 | 6 F |
| 2.00** | 6 F/7 F |
| 2.25 | 7 F |
| 2.50 | 8 F |

*For a given guide sheath or introducer sheath French size, the internal lumen and hemostasis valve will vary from manufacturer to manufacturer. When using an introducer for the first time, it should be tested with the largest Peripheral RotaLink Plus Burr intended to be used with it.

**The 2.00-mm Peripheral RotaLink Plus Burr size allows for use with a 6-F Terumo Pinnacle™ Destination™ Guide Sheath. In all other cases, a 7-F guide sheath or introducer sheath should be used with the 2.00-mm burr size.

CASE 1

A 54-year-old male presented with a superficial 3-cm, nonhealing left ankle wound after ankle surgery had been performed 6 months earlier. The patient had a past medical history of type 2 diabetes mellitus, hypertension, smoking, and was on varenicline (Chantix™; Pfizer Inc., Mission, KS). Arterial studies showed normal circulation on the right limb and an ankle-brachial index (ABI) of 0.5 on the left. MRA showed multiple severe high-grade stenoses of the superficial femoral artery (SFA), a 7-cm *de novo* occlusion with multiple collaterals reconstituting at the above-knee popliteal artery (Figure 2A), and three-vessel runoff with moderate disease of the anterior tibial artery.

A 7-F sheath was placed from a contralateral approach, and a Journey™ Guidewire (Boston Scientific Corporation) was used to negotiate the SFA stenoses successfully. The occlusion was crossed with a Glidecath™ Catheter and a Glidewire™ Guidewire (Terumo Interventional Systems, Somerset, NJ), and reentry was confirmed in the popliteal artery. A RotaWire Guidewire was exchanged through the catheter, and a 2.25-mm Peripheral RotaLink Plus Burr was used to ablate the stenotic SFA and occluded segment based on a 5-mm native SFA. Four 30-second runs were conducted for a total burr time of 2 minutes. Adjunctive PTA was performed with a 5- X 200-mm Mustang™ Balloon (Boston Scientific Corporation) to 4 ATM for 30 seconds. Final angiography showed a widely patent vessel with brisk flow (Figure 2B).

At 6-week follow-up, the patient had increased wound healing with bleeding at the wound edges, and arterial Doppler showed an ABI of 0.7.

- 12.9 minutes total fluoroscopy time
- 35 mL total contrast
- 2 minutes total burr time
- Single 2.25-mm Peripheral RotaLink Plus Burr
- 0.5 ABI improved to 0.7 at 6 weeks

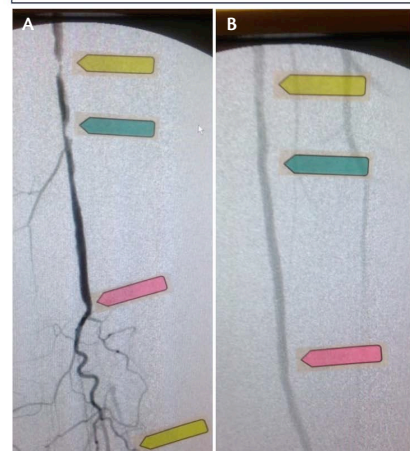


Figure 2

Sponsored by Boston Scientific Corporation

CASE 2

An 83-year-old female presented with a superficial ulceration in the first and second toe of the left foot. The patient had a past medical history significant for coronary artery disease, hypertension, diabetes, neuropathy, and chronic obstructive pulmonary disease, and was ambulatory.

Arterial Doppler showed an ABI of 0.4 on the left side with significant flattening of waveforms of the left metatarsal area. A diagnostic angiogram confirmed complete *de novo* occlusion of the tibioperoneal trunk followed by a second occlusion of the peroneal artery (Figure 3A).

Complete occlusions of the anterior tibial artery and posterior tibial artery were noted shortly after the origin, with no significant reconstitution noted at the foot.

A 70-cm, 6-F sheath was placed, and the tibioperoneal trunk and peroneal occlusions were crossed with a Rubicon™ 18 Catheter and V-18™ ControlWire™ Guidewire (Boston Scientific Corporation). A RotaWire™ Guidewire was exchanged

through the Rubicon Catheter, and a 2.0-mm Peripheral RotaLink™ Plus Burr was used to ablate the 3-mm tibioperoneal trunk and the 2.5-mm peroneal artery occlusions. The tibioperoneal trunk was opened after three 30-second runs (Figure 3B). Two additional 30-second runs were performed for a total burr time of 2.5 minutes, and low-pressure PTA was performed resulting in brisk flow all the way down to the foot (Figure 3C).

At 6-month follow-up, the patient showed wound healing, and arterial Doppler showed an ABI of 0.7 with improved pulse-volume recording waveforms.

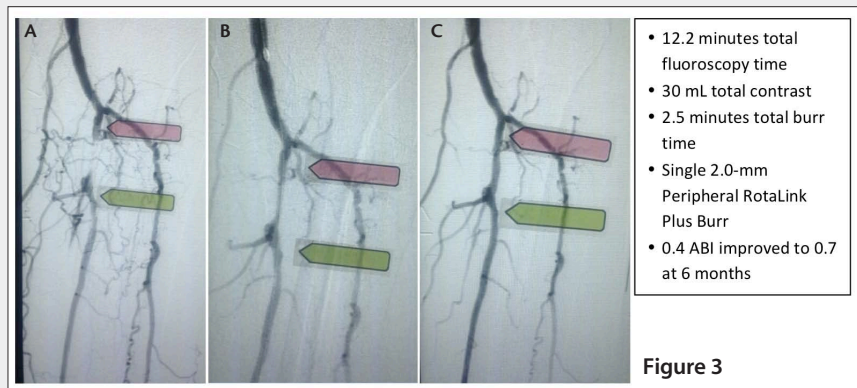


Figure 3

microparticles generated during treatment. Light pressure or gentle advancement allows controlled release of the microparticles. A drop in burr speed of 5,000 RPM or less, as well as a drop in audible pitch, indicate proper technique. Immediately after Rotablator Atherectomy, an angiogram often provides visual evidence of revascularization. In our experience, most lesions are treated adjunctively with low-pressure percutaneous transluminal angioplasty (PTA), and full profile is achieved at 3 to 4 ATM, denoting a clear change in vessel compliance.

This specific technique (see *Common Considerations*) has been shown to reduce heat accumulation, minimize slow flow/no flow, and prevent spasm and in situ thrombosis. We have followed this technique and had great clinical outcomes without experiencing any major device-related adverse events.

CONCLUSION

Treatment of peripheral artery disease remains a challenge despite multiple devices being available for treatment; often, device usage is dependent on operators and their experience with the device. In our early experience with Peripheral Rotablator Atherectomy, we have found the device to be safe, efficacious, and very cost-effective. It has been particularly effective in

treating calcified vessels, and we have found a definite niche in the tibials. Further experience is necessary to compare with the other atherectomy devices in terms of the ease of use, dissection, perforation, and clinically significant embolization. Compared with other atherectomy devices on the market, the cost advantage of the Rotablator System offers a definite competitive edge in today's cost-conscious environment. ■

Sonya S. Noor, MD, is a Clinical Associate Professor in the Department of Surgery at the University of Buffalo, Buffalo, New York. Dr. Noor has received no financial compensation for participation in this article. She has disclosed that she is a consultant for Boston Scientific Corporation. Dr. Noor may be reached at snoor@kaleida-health.org.

- Whitlow PL, Bass TA, Kipperman RM, et al. Results of the study to determine Rotablator and transluminal angioplasty strategy (STRATAS). *Am J Cardiol.* 2001;87:699-755.
- Bersin RM, Simonton CA. Board Review: Rotational and directional coronary atherectomy. *Cath Cardiovasc Interv.* 2003;58:487.

Results from case studies are not predictive of results in other cases. Results in other cases may vary. Rotablator does not have CE Mark for peripheral use. Rotablator, RotaLink, RotaWire, RotaGlide, Journey, Mustang, Rubicon, and V-18 ControlWire are registered or unregistered trademarks of Boston Scientific Corporation or its affiliates. All other trademarks are property of their respective owners. All images courtesy of Sonya S. Noor, MD.

© 2014 Boston Scientific Corporation or its affiliates. All rights reserved. PI-205705-AB JAN2014