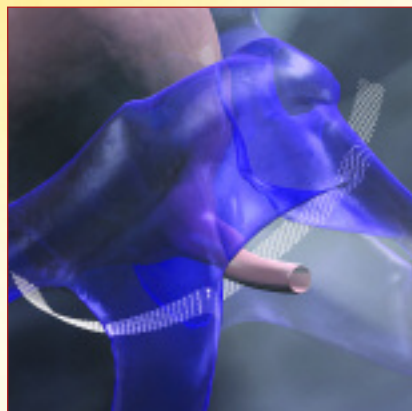




Gary E. Leach, MD

Director, Tower Urology Institute for Continence
Los Angeles, CA

TECHNIQUE SPOTLIGHT
Transobturator Mid-Urethral Sling



Obtryx[®] Sling System




**Boston
Scientific**

Obtryx®

Transobturator Mid-Urethral
Sling System

Gary E. Leach, MD

Director, Tower Urology Institute for Continence
Los Angeles, CA



POTENTIAL BENEFITS OF USING TRANSOBTURATOR APPROACH:

Various techniques of sling procedures have continued to evolve over the last 30 years. Early techniques utilizing large segments of autologous abdominal fascia or fascia lata evolved into sling procedures with shorter segments of fascia and smaller incisions with less retropubic dissection. Over the last 7 years, new types of synthetic sling materials have gained popularity (TVT) along with the concept of placing the sling in the area of the mid-urethra. Needle passage through the retropubic space was still required with the associated risks of bladder injury, injury to adjacent bowel, and bleeding in an area of difficult exposure. These risks have been minimized with the introduction of the transobturator approach, which requires no entry into the retropubic space. The combination of an improved synthetic mid-urethral sling with introduction instruments designed to allow safe passage of the sling through the obturator foramen has been a significant advance in the treatment of female stress incontinence. Following is the technique that I use when performing a transobturator sling with the Obtryx Transobturator Sling.

PATIENT SELECTION:

The author's surgical procedure of choice for female stress incontinence is the transobturator sling using the Obtryx Sling System. All candidates for this procedure must have urodynamically documented genuine stress incontinence with or without urethral hypermobility. Other options discussed with potential surgical candidates include biofeedback/ pelvic floor training and injection therapy with a bulking agent in those patients with minimal to no urethral hypermobility. Those women with the combined problem of stress incontinence with significant cystocele are offered the combination of transobturator sling with repair of the cystocele defect utilizing non-frozen cadaveric fascia lata.

PROCEDURE LOCATION:

The procedure is performed in the hospital OR either as an outpatient or inpatient procedure depending on the individual patient circumstances.

PRE-OPERATIVE PREPARATION:

Patient Preparation:

All patients are taught the technique of clean self-intermittent catheterization pre-operatively. In the event that the patient is unable to void after the transobturator sling, the patient is then re-instructed in the self-catheterization technique that she learned before the surgery. The urine is confirmed to be sterile pre-operatively and patients perform a provo-iodine douche the night before and the morning of surgery with parenteral antibiotics administered pre-operatively. When the procedure is planned as an outpatient procedure, the patient is advised to arrange transportation home after discharge.

INTRA - OPERATIVE :

Anesthesia:

The transobturator sling procedure is performed under either a general or spinal anesthetic. The choice of anesthesia type is made based upon patient preference and clinical factors considered by the anesthesiologist.

Patient Preparation and Positioning:

After anesthesia is induced, the patient's legs are placed into Allen stirrups and the adductor longus tendon is palpated on each side as a "landmark" since the needle to transfer the sling is passed just below this tendon at the level of the clitoris. For obese patients, a slightly more exaggerated lithotomy position may be required to facilitate palpation of this tendon landmark. The patient is shaved and prepared with a lower abdominal and vaginal povidiodine scrub. A Foley catheter is inserted before starting the procedure.

Technique of Sling Placement:

After the bladder neck is identified by palpation of the Foley catheter balloon, either a vertical midline incision is made from the mid-urethra to the bladder neck or an inverted "U" shaped incision is made with the apex of the "U" at the junction of the mid and distal 1/3 of the urethra. If the patient has had previous sling surgery, I prefer the inverted "U" incision to maximize exposure and allow direct control of any bleeding in the area. An anterior vaginal wall flap is then reflected to the bladder neck. Regardless of the type of incision used, the next step is sharp lateral dissection to the pubic ramus. The ramus is palpated on each side and dissection continues laterally to the medial aspect of the obturator membrane.

Utilizing the landmarks of the adductor longus tendon and the clitoris, a 22 g spinal needle is passed through the skin in the area of the groin crease towards the vaginal finger on the inside obturator membrane. This needle serves to define the direction of the larger needle used to pass the sling from the vagina out to the skin level. Once the needle is felt with the fingertip, 1% marcaine (which is optional) is injected as the needle is withdrawn. A small skin incision is then made on each side and either the Obtryx® Halo Needle or the Obtryx Curved Needle is chosen to use for the procedure. I prefer the Curved Needle, (FIGURE A), which is easier to pass in the "large" patient. The needle is passed through the skin and muscle layers directly onto the fingertip on the inside of the obturator membrane, (FIGURE B). Care is taken to pass the needle "above" the vagina with avoidance of perforation into the vagina at the junction of the anterior and lateral vaginal walls. After the needle is passed, the association loop at the end of the sling is fed over the tip of the needle and the needle is withdrawn out to the skin level, (FIGURE C). This process is repeated on the contra-lateral side with the sling being positioned in the area of the mid-urethra, (FIGURE D). The centering tab should be positioned out towards the surgeon. Should the vaginal wall be perforated and recognized after the mesh is attached and pulled through the tissue, the Obtryx Needle has a removable mesh assembly connection that can be removed from the needle, pulled back out and placed again without having to open another device. At this point, if there is any question regarding possible bladder or urethral injury, cystoscopy is performed.



FIGURE A

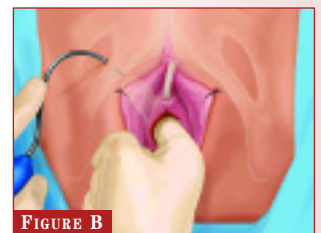


FIGURE B

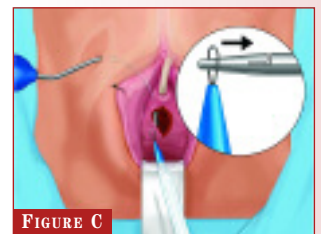


FIGURE C

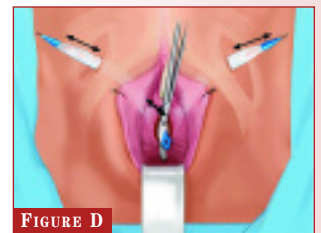


FIGURE D

Sling Tensioning/ Sleeve Removal:

After both needles have been withdrawn and the sling is seen to lay flat against the area of the mid-urethra, a Metzenbaum scissors is placed between the sling and the urethra. Both needles are equally withdrawn to bring the sling in contact with the scissors. The blue plastic tab is then cut at the midline of the sling beneath the urethra, (FIGURE E). Next, the plastic sleeves are simultaneously removed from each end of the sling leaving the synthetic sling material in contact with the scissors held up against the urethra. Given the special characteristics of the “de-tanged” suburethral segment of the Advantage® sling, (FIGURE F), the sling material assumes a very flat configuration beneath the mid-urethra. The vaginal incision is closed with a 2-0 Vicryl® suture. The excess sling material above the skin level is trimmed and the too small groin incisions are closed with 4-0 Monocryl® suture. When the procedure is performed on an outpatient basis, the patient is sent to the recovery room without a Foley catheter or vaginal packing. Should the patient be held “overnight”, the Foley catheter is inserted and placed to a sterile drainage bag. A vaginal pack may be utilized at the discretion of the surgeon.

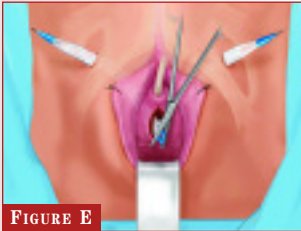


FIGURE E

tanged
edges

FIGURE F

de-tanged
edges

When the sling is performed with a cystocele repair, a single vertical incision is made from the mid-urethra to the cervix or vaginal cuff and the cystourethrocele is mobilized off the anterior vaginal wall. The sling is then placed and the cystocele repair is completed with a “patch” of cadaveric fascia tissue to repair the cystocele defect. The tension on the sling is adjusted after the cystocele repair as noted above.

POST-OPERATIVE CARE:

The post-void residual urine volume is checked after surgery. When the patient is unable to void or if the post-void residual volume is > 100cc, the patient is instructed in the technique of self-catheterization that she learned before the sling procedure. The patient is discharged on oral antibiotics for 1 week and she is instructed to limit her physical activity. Pain is usually minimal and treated with oral Tylenol®. Post-operative follow-up appointments occur at 1 and 6 weeks after surgery.

POTENTIAL POST-OPERATIVE COMPLICATIONS:

In general, complications have been rare following the Obtryx® Transobturator Sling procedure. We have seen few reports of significant bleeding, injuries to the bladder or urethra, and permanent urinary retention. In my experience, 80% of patients void immediately after surgery and the remainder usually require self-catheterization for less than one week. As of the date of this publication, we have seen no complications related to the synthetic sling material (ie. no urethral erosions, infections, or vaginal extrusions). Post operative pain has generally been minimal.

SUMMARY:

The Transobturator Sling Procedure with the Obtryx Sling System is a significant advance in the surgical treatment of female stress incontinence. The unique aspects of the Advantage® Synthetic Sling material coupled with the transobturator approach is a significant advance in the surgical treatment of female stress incontinence. Our experience thus far in over 75 cases has been very promising without significant complications.

The opinions and recommendations expressed in this Technique Spotlight are those of the author alone. Boston Scientific makes no representations or warranties as to the accuracy or completeness of the information set forth herein.

Vicryl and Monocryl are trademarks of Johnson & Johnson Corporation.

Caution: Federal Law (USA) restricts devices to sale by or on the order of a physician. Refer to Directions for Use provided with these products for complete instructions, warnings and precautions prior to using these products.

Boston Scientific

Delivering what's next.™

Boston Scientific Corporation
One Boston Scientific Place
Natick, MA 01760-1537
www.bostonscientific.com

Ordering Information
1.888.272.1001

© 2006 Boston Scientific Corporation
or it's affiliates. All rights reserved.

MVU5710 12/05-12/07