Boston Scientific
Advancing science for life™

CASE STUDY

Share Your Direxion Story

'Unmatched' Torque and Tracking for Hepatic Anatomy

Ilan Rzadkowolsky-Raoli, MD – Palmetto General Hospital, Hialeah, Florida

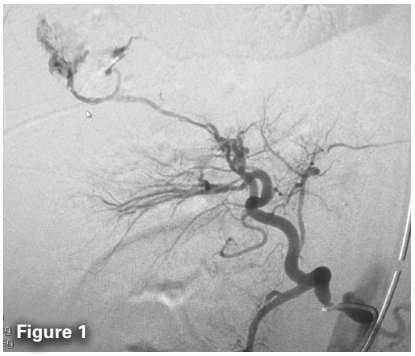
Figure 1

A 65-year-old man with large hepatocellular carcinoma (HCC) occupying segments 7 and 8 of the liver presented with rapid decompensation with hypotension, tachypnea, and a 6 g/dL drop in hemoglobin in 12 hours. A quick noncontrast CT scan showed evidence of tumor rupture with a large amount of hemoperitoneum. A celiac angiogram showed active extravasation of contrast from a posterior branch of the right hepatic artery supplying the HCC (Figure 1). There was poor perfusion to the remaining liver due to systemic low blood pressures.

> **"With its unmatched torqueability and trackability as a consequence of its unique shaft design, Direxion is rapidly becoming my first choice."**

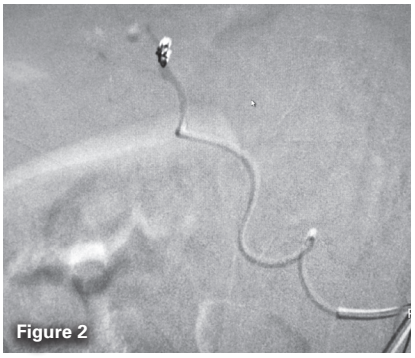
Figure 2

The first twist after the tip of the guiding catheter just before the gastroduodenal artery branch is a very acute turn, reversing almost 135° on itself. **Another microcatheter would not make this turn without kicking out the guiding catheter.** This was the first case in which I was able to use the Direxion Microcatheter.

After the tight loop was surpassed (Figure 2) while maintaining guiding catheter placement, three more turns were navigated, including another relatively sharp angulation at the branching of the offending artery. **Most other small-bore catheters would have surrendered their torqueability after the first turn.** Gaining this position was the key to successfully prosecuting the case (Figure 3).

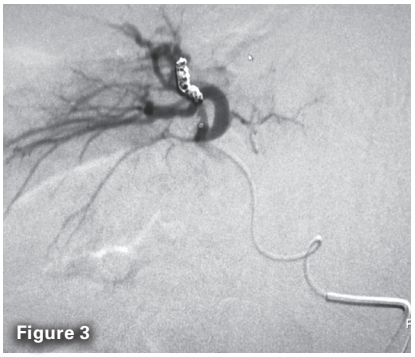
Figure 3

The case in this article illustrates the capabilities of the Direxion Microcatheter to outperform most other examples of its class. With its **unmatched torqueability and trackability as a consequence of its unique shaft design,** as well as its slick feel due to its lubricious outer coating, the Direxion is rapidly becoming my first choice for slightly challenging anatomy. Add to this mix the array of tip configurations and both high-flow and low-profile diameters, and there is no location that cancer is safe!

Boston Scientific
Advancing science for life™

DIREXION™ Torqueable Microcatheter

REPOSITION WITHOUT THE WIRE

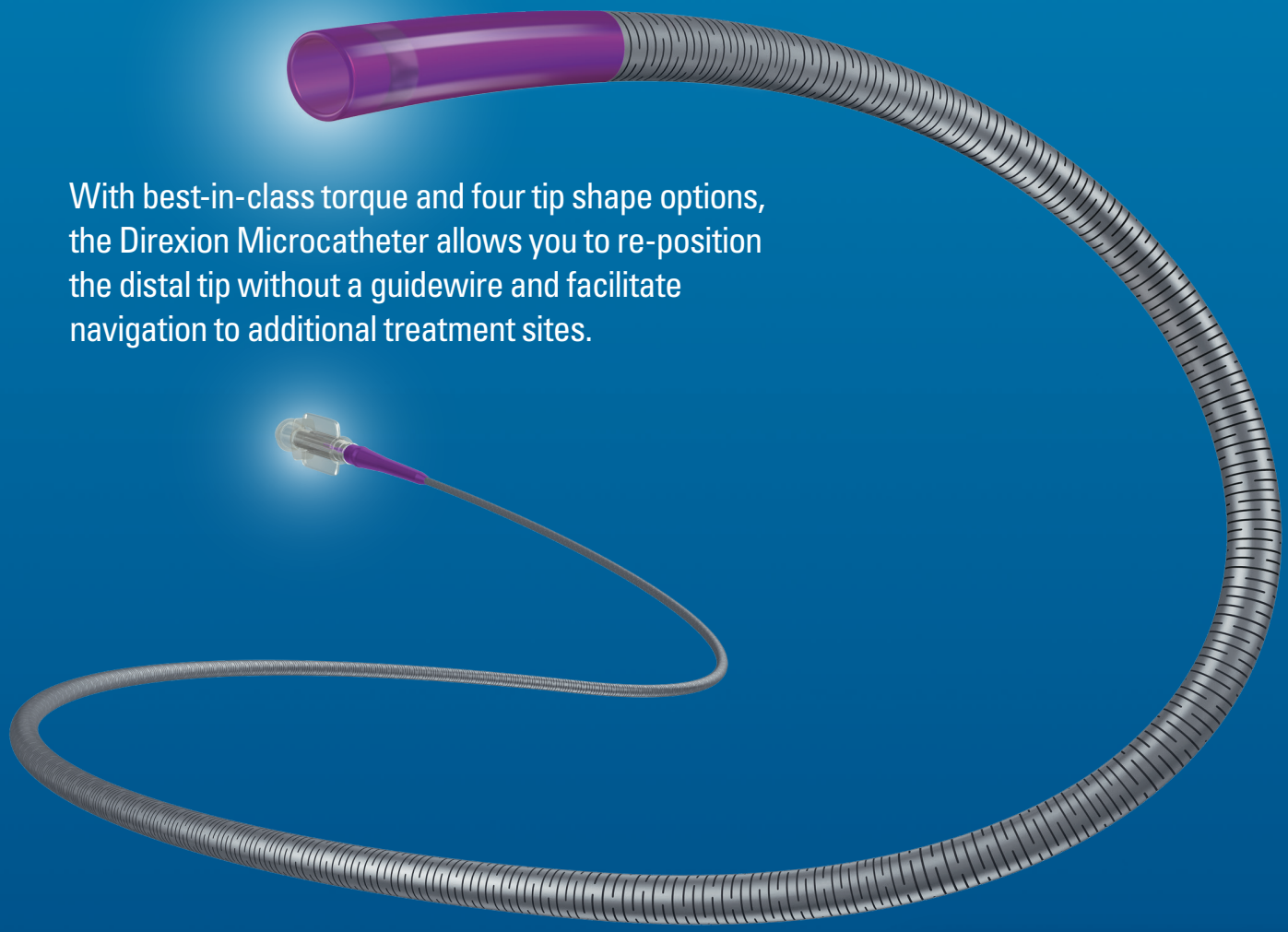

With best-in-class torque and four tip shape options, the Direxion Microcatheter allows you to re-position the distal tip without a guidewire and facilitate navigation to additional treatment sites.

Share Your Direxion Story

www.bostonscientific.com/Direxion

DIREXION™ DIREXION HI-FLO™

CAUTION: Federal law (USA) restricts this device to sale by or on the order of a physician. Rx only. Prior to use, please see the complete "Directions for Use" for more information on Indications, Contraindications, Warnings, Precautions, Adverse Events, and Operator's Instructions.

INTENDED USE/INDICATIONS FOR USE: The Direxion and Direxion HI-FLO Torqueable Microcatheters are intended for peripheral vascular use. The pre-loaded Fathom and Transend Guidewires can be used to selectively introduce and position the microcatheter in the peripheral vasculature. The microcatheter can be used for controlled and selective infusion of diagnostic, embolic, or therapeutic materials into the vessel. **CONTRAINDICATIONS:** None known. **WARNINGS:** • Never advance or withdraw an intravascular device against resistance until the cause of resistance is determined by fluoroscopy. Movement of the microcatheter or guidewire against resistance may result in damage or separation of the microcatheter or guidewire tip, or vessel perforation. • This Direxion Microcatheter family is not intended for use in the coronary vasculature or neurovasculature. • The Direxion HI-FLO Microcatheter is not designed for the delivery of embolic coils. • Use of excessive force to manipulate the microcatheter against resistance can cause a fracture in the nitinol shaft. Take care not to over-torque the microcatheter, and to relieve any tension before withdrawal by rotating the microcatheter in the opposite direction. **PRECAUTIONS:** • This device should be used only by physicians thoroughly trained in percutaneous, intravascular techniques and procedures. • Do not introduce the microcatheter without guidewire support as this may cause damage to the proximal shaft of the catheter. • Because the microcatheter may be advanced into narrow sub-selective vasculature, repeatedly assure that the microcatheter has not been advanced so far as to interfere with its removal. **ADVERSE EVENTS:** The Adverse Events include, but are not limited to: • Allergic reaction • Death • Embolism • Hemorrhage/Hematoma • Infection • Pseudoaneurysm • Stroke • Vascular thrombosis • Vessel occlusion • Vessel spasm • Vessel trauma (dissection, perforation, rupture) **REV AB**

Indications, contraindications, warnings and instructions for use can be found in the product labeling supplied with each device. Information for the use only in countries with applicable health authority product registrations. This material is not intended for use or distribution in France.

Boston Scientific
Advancing science for life™

CASE STUDY

Share Your Direxion Story

Tracking in Unfavorable Anatomy for Liver Cancer

Ilan Rzadkowolsky-Raoli, MD – Palmetto General Hospital, Hialeah, Florida


Figure 1


Figure 2

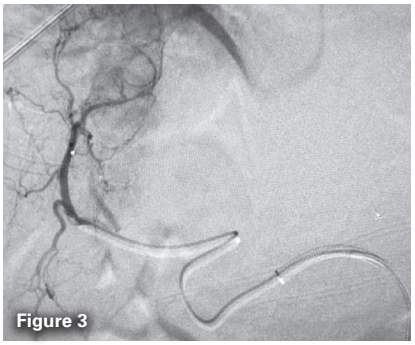
Figure 3

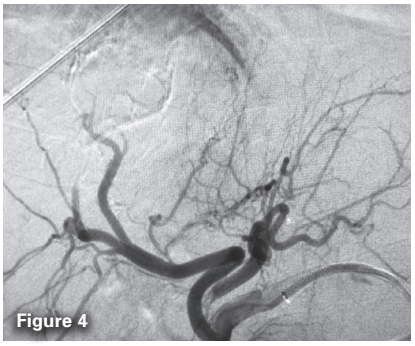
Figure 4

A 57-year-old woman with a history of primary neuroendocrine tumor of the colon was treated with hemicolectomy. A metastatic lesion straddling segments 7 and 8 of the liver had been previously treated with percutaneous thermal ablation (both radiofrequency and microwave) with partial success. The patient presented for bland embolization. A celiac angiogram showed faint tumor blush near the dome of the liver, with hepatic arterial supply derived from both the segment 7 and 8 branches (Figure 1).

There was severe bend of the proper hepatic artery after the gastroduodenal artery and near 180° angulation of the right hepatic artery distal to the left hepatic artery takeoff. **This second flexure could not be crossed with a conventional microcatheter without buckling the support catheter.** Embolization of the medial branch was performed (Figure 2).

> **“This singular tool allowed me to successfully complete therapy where other microcatheters failed.”**

This position was gained using the Direxion Microcatheter, which did not yield trackability despite the unfavorable anatomical bend of the proximal right hepatic artery. A superselective angiogram from the segment 7 hepatic artery showed tumor blush medially, and preparation was made for embolization (Figure 3).

Again, this location was attained despite power-bleeding anatomy. Embolization of the tumor-feeding arterial branches was successful, with stasis of contrast and cast of vessels (Figure 4).

The case in this article illustrates the capabilities of the Direxion Microcatheter to outperform most other examples of its class. With its **unmatched torqueability and trackability as a consequence of its unique shaft design,** as well as its slick feel due to its lubricious outer coating, the Direxion is rapidly becoming my first choice for slightly challenging anatomy. Add to this mix the array of tip configurations and both high-flow and low-profile diameters, and there is no location that cancer is safe!

Boston Scientific
Advancing science for life™

DIREXION™ Torqueable Microcatheter

REPOSITION WITHOUT THE WIRE

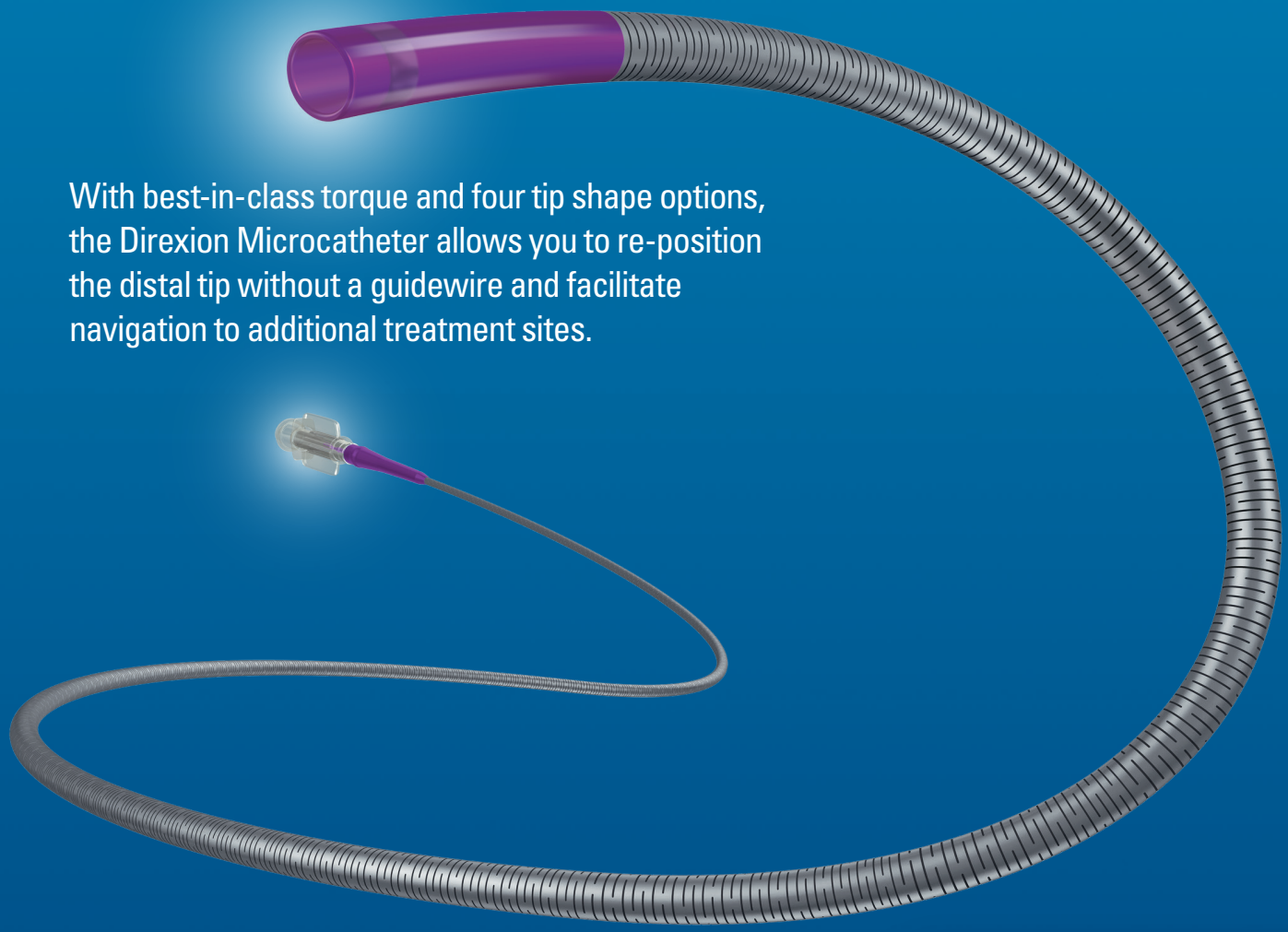

With best-in-class torque and four tip shape options, the Direxion Microcatheter allows you to re-position the distal tip without a guidewire and facilitate navigation to additional treatment sites.

Share Your Direxion Story

www.bostonscientific.com/Direxion

DIREXION™ DIREXION HI-FLO™

CAUTION: Federal law (USA) restricts this device to sale by or on the order of a physician. Rx only. Prior to use, please see the complete "Directions for Use" for more information on Indications, Contraindications, Warnings, Precautions, Adverse Events, and Operator's Instructions.

INTENDED USE/INDICATIONS FOR USE: The Direxion and Direxion HI-FLO Torqueable Microcatheters are intended for peripheral vascular use. The pre-loaded Fathom and Transend Guidewires can be used to selectively introduce and position the microcatheter in the peripheral vasculature. The microcatheter can be used for controlled and selective infusion of diagnostic, embolic, or therapeutic materials into the vessel. **CONTRAINDICATIONS:** None known. **WARNINGS:** • Never advance or withdraw an intravascular device against resistance until the cause of resistance is determined by fluoroscopy. Movement of the microcatheter or guidewire against resistance may result in damage or separation of the microcatheter or guidewire tip, or vessel perforation. • This Direxion Microcatheter family is not intended for use in the coronary vasculature or neurovasculature. • The Direxion HI-FLO Microcatheter is not designed for the delivery of embolic coils. • Use of excessive force to manipulate the microcatheter against resistance can cause a fracture in the nitinol shaft. Take care not to over-torque the microcatheter, and to relieve any tension before withdrawal by rotating the microcatheter in the opposite direction. **PRECAUTIONS:** • This device should be used only by physicians thoroughly trained in percutaneous, intravascular techniques and procedures. • Do not introduce the microcatheter without guidewire support as this may cause damage to the proximal shaft of the catheter. • Because the microcatheter may be advanced into narrow sub-selective vasculature, repeatedly assure that the microcatheter has not been advanced so far as to interfere with its removal. **ADVERSE EVENTS:** The Adverse Events include, but are not limited to: • Allergic reaction • Death • Embolism • Hemorrhage/Hematoma • Infection • Pseudoaneurysm • Stroke • Vascular thrombosis • Vessel occlusion • Vessel spasm • Vessel trauma (dissection, perforation, rupture) **REV AB**

Indications, contraindications, warnings and instructions for use can be found in the product labeling supplied with each device. Information for the use only in countries with applicable health authority product registrations. This material is not intended for use or distribution in France.

Boston Scientific
Advancing science for life™

CASE STUDY

Share Your Direxion Story

Embolization of Benign Prostatic Hyperplasia

Sandeep Bagla, MD – Inova Alexandria Hospital, Alexandria, Virginia

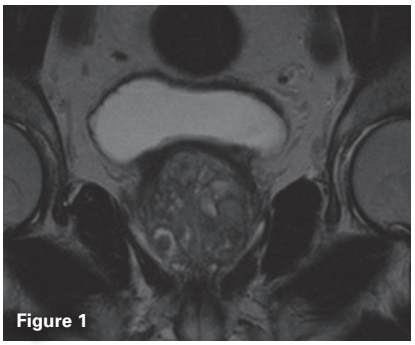
Figure 1

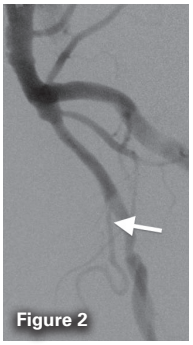
Figure 2

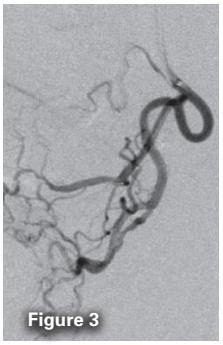
Figure 3

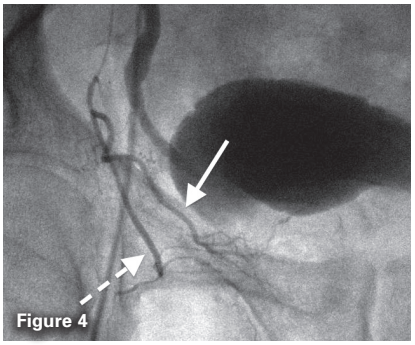
Figure 4

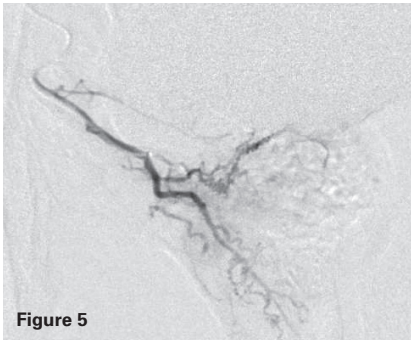
Figure 5

Benign prostatic hyperplasia (BPH) affects more than 15 million men in the United States. Patients typically present with symptoms such as frequency, nocturia, urgency, weak stream, and feeling of incomplete emptying. Although medical therapy or lifestyle modification may be suitable for most patients, those with moderate or severe symptoms will likely require surgical intervention. Currently available transurethral procedures, such as transurethral resection or photoselective vaporization, work by increasing the luminal diameter of the prostatic urethra. These come at a significant cost of complications, including incontinence, impotence, bleeding, or retrograde ejaculation. Because BPH is also hypervascular,[1,2] particularly in the central gland, interventional radiologists have used prostatic artery embolization (PAE) to reduce the size of these hypervascular nodules and improve symptoms from BPH. Results from clinical trials[3] have demonstrated a significant reduction in symptoms from BPH with a very low risk of complication. Significant technical challenges exist with PAE, including tortuous anatomy with small distal target vasculature and the need for high-quality imaging and embolic material injection.

A 62-year-old male with severe lower urinary tract symptoms from BPH was referred to the clinic for evaluation of PAE. His peak urine flow rate was severely decreased at 2 cc/sec and his prostate was enlarged to 90 cc (Figure 1). He was in good health and sexually active and wanted to avoid transurethral therapy because of the risk of sexual side effects. After discussion with the patient and consulting urologist, the patient was scheduled for the procedure.

> **"Embolization was performed through Direxion proximally and then advanced distally without a wire to allow for further embolization."**

A 6 F vascular sheath was placed in the right common femoral artery and a 6 F guiding catheter was placed in the left hypogastric artery. Digital subtraction angiography depicts a tortuous left prostatic artery (Figure 2), which is typical in appearance. A pre-shaped 2.4 F Direxion microcatheter was used to select the left prostatic artery and subselective angiography was performed (Figure 3). **Embolization was performed through the Direxion Microcatheter proximally and then advanced distally without a wire to allow for further embolization.**

Smaller size spherical particulate (100 micron) and gelfoam were utilized in the main trunk. On the right side, the prostatic artery originated from the obturator artery (Figure 4) and the pre-shaped tip was directed in to the prostatic artery to perform selective angiography and embolization (Figure 5). Embolization was performed to stasis and he was discharged without complications. He noted more than 50% reduction in his symptoms by 1 month and has continued to do well at his routine follow up.

Tortuosity and size of the prostatic artery remain the greatest challenges to PAE. In this case, **Direxion allowed for reliable torqueability of the distal pre-shaped tip.** This can be used to select the prostatic artery when originating from a distal non-target vessel as on the right side in this patient. It is also useful when the operator would like to advance within the target vessel with careful rotation.

1. Deering RE, Bigler SA, Brown M, Brawer MK. Microvascularity in benign prostatic hyperplasia. *Prostate.* 1995;26:III-I I5.
2. Stefanou D, Batsitatou A, Kamina S, et al. Expression of vascular endothelial growth factor (VEGF) and association with microvessel density in benign prostatic hyperplasia and prostate cancer. *In Vivo.* 2004;18:155-160.
3. Schreuder SM, Scholtens AE, Reekers JA, Bipat S. The role of prostatic arterial embolization in patients with benign prostatic hyperplasia: a systematic review. *Cardiovasc Intervent Radiol.* 2014;37:1198-1219.

Boston Scientific
Advancing science for life™

DIREXION™ Torqueable Microcatheter

REPOSITION WITHOUT THE WIRE

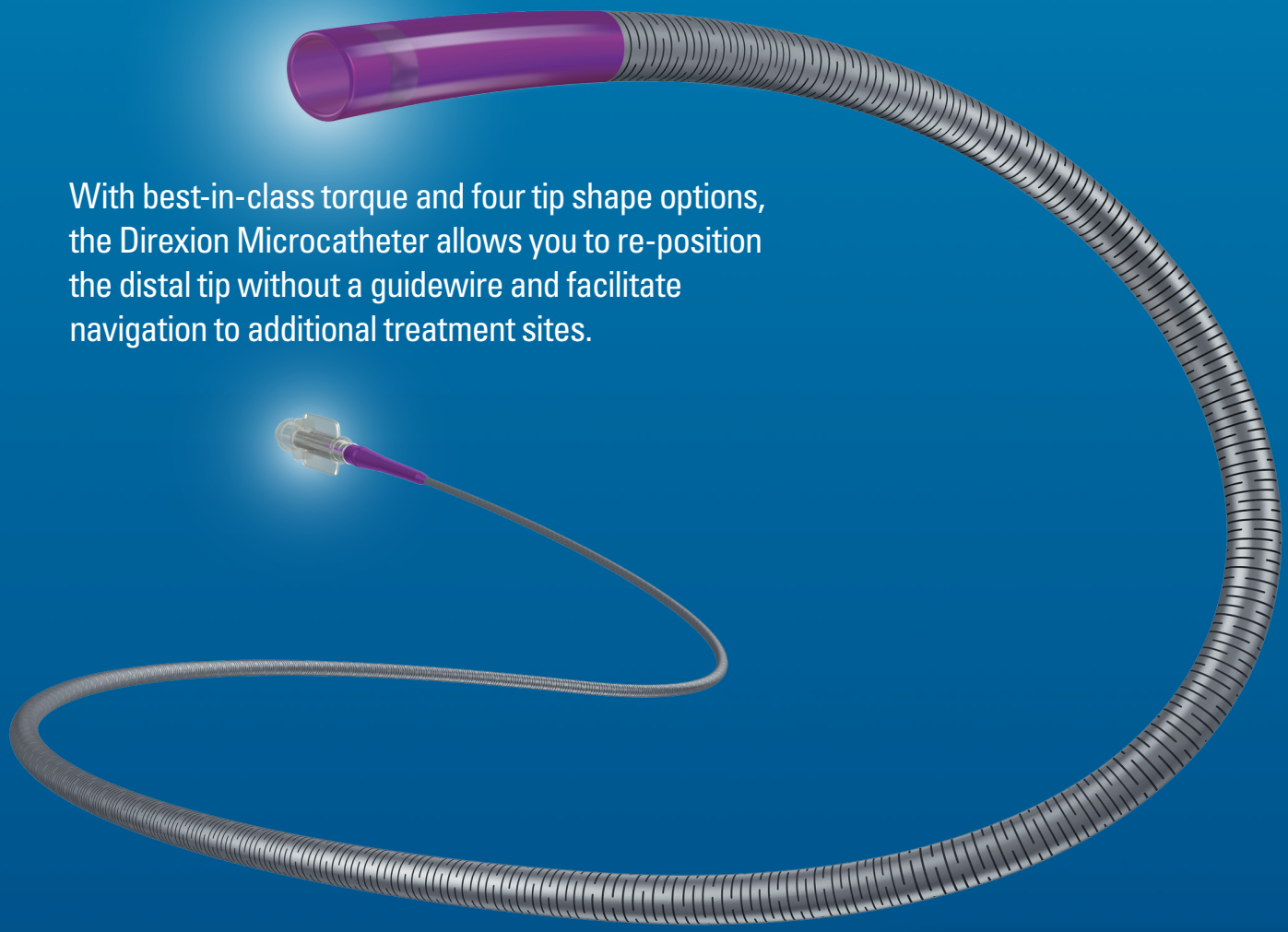

With best-in-class torque and four tip shape options, the Direxion Microcatheter allows you to re-position the distal tip without a guidewire and facilitate navigation to additional treatment sites.

Share Your Direxion Story

www.bostonscientific.com/Direxion

DIREXION™ DIREXION HI-FLO™

CAUTION: Federal law (USA) restricts this device to sale by or on the order of a physician. Rx only. Prior to use, please see the complete "Directions for Use" for more information on Indications, Contraindications, Warnings, Precautions, Adverse Events, and Operator's Instructions.

INTENDED USE/INDICATIONS FOR USE: The Direxion and Direxion HI-FLO Torqueable Microcatheters are intended for peripheral vascular use. The pre-loaded Fathom and Transend Guidewires can be used to selectively introduce and position the microcatheter in the peripheral vasculature. The microcatheter can be used for controlled and selective infusion of diagnostic, embolic, or therapeutic materials into the vessel. **CONTRAINDICATIONS:** None known. **WARNINGS:** • Never advance or withdraw an intravascular device against resistance until the cause of resistance is determined by fluoroscopy. Movement of the microcatheter or guidewire against resistance may result in damage or separation of the microcatheter or guidewire tip, or vessel perforation. • This Direxion Microcatheter family is not intended for use in the coronary vasculature or neurovasculature. • The Direxion HI-FLO Microcatheter is not designed for the delivery of embolic coils. • Use of excessive force to manipulate the microcatheter against resistance can cause a fracture in the nitinol shaft. Take care not to over-torque the microcatheter, and to relieve any tension before withdrawal by rotating the microcatheter in the opposite direction. **PRECAUTIONS:** • This device should be used only by physicians thoroughly trained in percutaneous, intravascular techniques and procedures. • Do not introduce the microcatheter without guidewire support as this may cause damage to the proximal shaft of the catheter. • Because the microcatheter may be advanced into narrow sub-selective vasculature, repeatedly assure that the microcatheter has not been advanced so far as to interfere with its removal. **ADVERSE EVENTS:** The Adverse Events include, but are not limited to: • Allergic reaction • Death • Embolism • Hemorrhage/Hematoma • Infection • Pseudoaneurysm • Stroke • Vascular thrombosis • Vessel occlusion • Vessel spasm • Vessel trauma (dissection, perforation, rupture) **REV AB**

Indications, contraindications, warnings and instructions for use can be found in the product labeling supplied with each device. Information for the use only in countries with applicable health authority product registrations. This material is not intended for use or distribution in France.

Boston Scientific
Advancing science for life™

CASE STUDY

Share Your Direxion Story

TACE for Extrahepatic Arteries Feeding HCC

Joan Falco, MD and Eva Criado, MD – University Hospital Parc Taulí, Sabadell, Spain

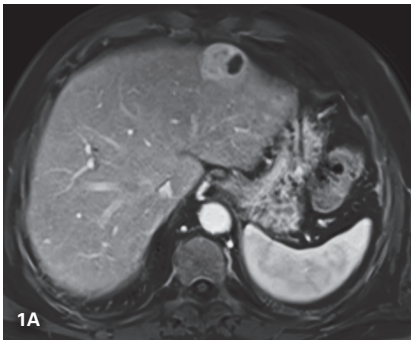

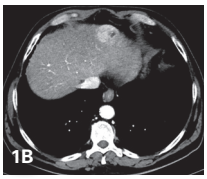

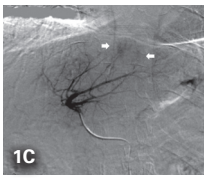

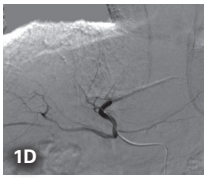

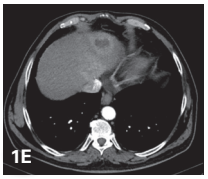

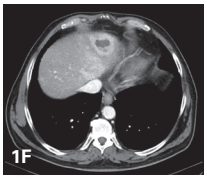

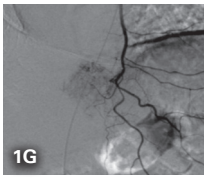

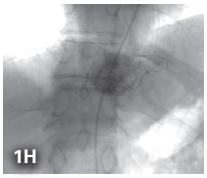

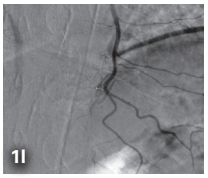

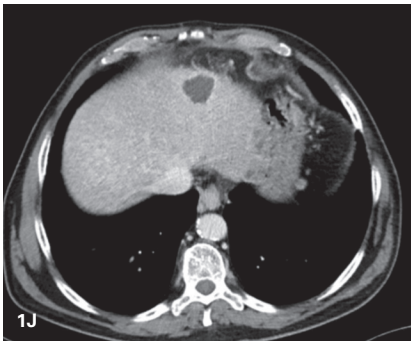

A 59-year-old man presented with a medical history of stable ischemic heart disease. He had no known liver disease. An abdominal MRI was performed (Figure 1A) and showed an incidental liver lesion of 3.8 cm in segment 2 with typical characteristics of HCC. The final diagnosis was nonalcoholic steatohepatitis cirrhosis in a patient with Barcelona Clinic Liver Cancer early-stage A, Child-Pugh A, candidate to orthotopic liver transplant. Treatment with drug-eluting bead chemoembolization was decided as a bridge to liver transplant. After MRI diagnosis and before treatment, a dynamic angio-CT scan (Figure 1B) was also obtained, which showed the described lesion with arterial enhancement.

Through a right femoral access, a celiac trunk arteriogram showed a mild enhancement in the area of segment 2 (Figure 1C). Treatment with doxorubicin-loaded, 100–300 µm beads was administered. No additional tumoral branch or suspicious foci of enhancement was detected (Figure 1D). Dynamic angio-CT scans performed 1 month later with arterial and venous phase (Figures 1E and 1F), showed partial response of the nodule, but no additional information about the pathway of new feeding arteries.

> **“The use of these more technically developed microcatheters, like Direxion, permits not only the injection of particles but also good trackability through tortuous routes.”**

A second TACE was planned. Angiography focused on extrahepatic vessels showed a left mammary artery feeding the remaining viable tumor (Figure 1G). Using a 2.4 F, 150 cm Direxion Torqueable Microcatheter, superselective catheterization of the final tumoral branch was accomplished (Figure 1H). Superficiality of the parietal branches of the mammary artery discouraged us from performing a nonsuperselective embolization with doxorubicin. The final run showed a lack of enhancement of the lesion (Figure 1I). No complications, such as pain or ulcerations, were seen. Control with angio-CT scan showed a complete response of the lesion in segment 2 (Figure 1J).

Although the majority of selective chemoembolization can be accomplished with standard 2.7 F microcatheters, suspicion of extrahepatic feeding arteries with HCC or inability to accomplish a superselective catheterization makes it crucial to use more efficient microcatheters.

Boston Scientific
Advancing science for life™

DIREXION™ Torqueable Microcatheter

CONTROL THE FLOW

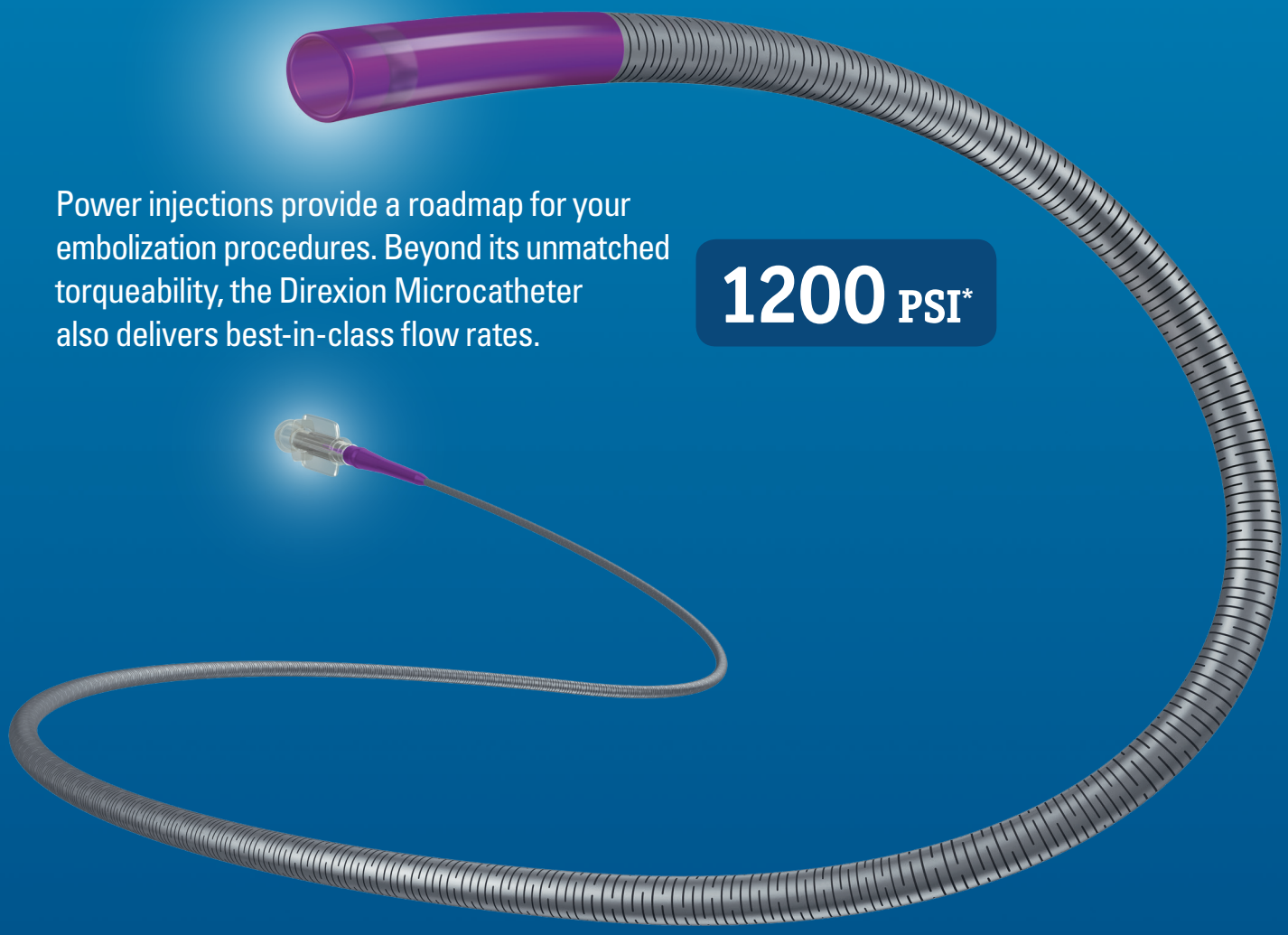

Power injections provide a roadmap for your embolization procedures. Beyond its unmatched torqueability, the Direxion Microcatheter also delivers best-in-class flow rates.

1200 PSI*

Share Your Direxion Story

www.bostonscientific.com/Direxion

*1200 psi = 8,274 kPa

DIREXION™ DIREXION HI-FLO™

CAUTION: Federal law (USA) restricts this device to sale by or on the order of a physician. Rx only. Prior to use, please see the complete "Directions for Use" for more information on Indications, Contraindications, Warnings, Precautions, Adverse Events, and Operator's Instructions.

INTENDED USE/INDICATIONS FOR USE: The Direxion and Direxion HI-FLO Torqueable Microcatheters are intended for peripheral vascular use. The pre-loaded Fathom and Transend Guidewires can be used to selectively introduce and position the microcatheter in the peripheral vasculature. The microcatheter can be used for controlled and selective infusion of diagnostic, embolic, or therapeutic materials into the vessel. **CONTRAINDICATIONS:** None known. **WARNINGS:** • Never advance or withdraw an intravascular device against resistance until the cause of resistance is determined by fluoroscopy. Movement of the microcatheter or guidewire against resistance may result in damage or separation of the microcatheter or guidewire tip, or vessel perforation. • This Direxion Microcatheter family is not intended for use in the coronary vasculature or neurovasculature. • The Direxion HI-FLO Microcatheter is not designed for the delivery of embolic coils. • Use of excessive force to manipulate the microcatheter against resistance can cause a fracture in the nitinol shaft. Take care not to over-torque the microcatheter, and to relieve any tension before withdrawal by rotating the microcatheter in the opposite direction. **PRECAUTIONS:** • This device should be used only by physicians thoroughly trained in percutaneous, intravascular techniques and procedures. • Do not introduce the microcatheter without guidewire support as this may cause damage to the proximal shaft of the catheter. • Because the microcatheter may be advanced into narrow sub-selective vasculature, repeatedly assure that the microcatheter has not been advanced so far as to interfere with its removal. **ADVERSE EVENTS:** The Adverse Events include, but are not limited to: • Allergic reaction • Death • Embolism • Hemorrhage/Hematoma • Infection • Pseudoaneurysm • Stroke • Vascular thrombosis • Vessel occlusion • Vessel spasm • Vessel trauma (dissection, perforation, rupture) **REV AB**

Indications, contraindications, warnings and instructions for use can be found in the product labeling supplied with each device. Information for the use only in countries with applicable health authority product registrations. This material is not intended for use or distribution in France.

Boston Scientific
Advancing science for life™

CASE STUDY

Share Your Direxion Story

Preablative Embolization for Solitary HCC

Brian S. Geller, MD and Hugh Davis, MD – Gainesville, Florida

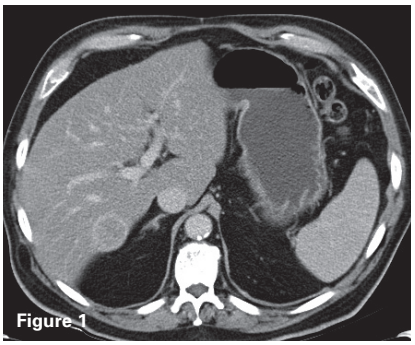
Figure 1


Figure 2

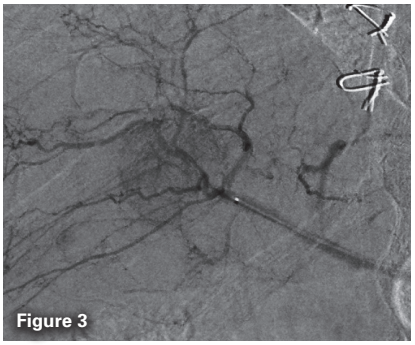
Figure 3

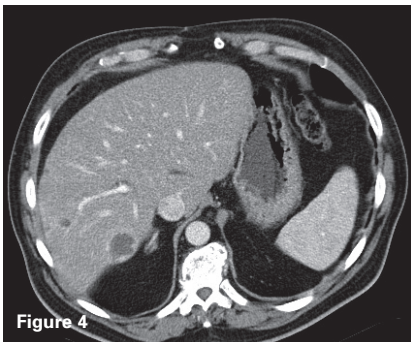
Figure 4

A 79-year-old man with a history of a solitary hepatocellular carcinoma (HCC) in segment 6 presented to the interventional radiology department for hepatic angiography and preablative embolization (Figure 1).

After using standard techniques to access the right common femoral artery, a 5 F sheath was placed. Subsequently, a selective 4 F reverse-curve catheter and a hydrophilic guidewire were used to cannulate the celiac artery. There was difficulty advancing the 4 F catheter over the wire and into the common hepatic artery, so it was decided to park the selective catheter at the celiac artery origin and use a microcatheter from there. A 0.027 inch Renegade HI-FLO Microcatheter and a Fathom 16 Steerable Guidewire were used to cannulate the right hepatic artery (Figure 2).

> **“The higher flow rates that Direxion provides completely changed this patient’s management.”**

The angiogram (contrast injector set for flow rate of 4 mL/s for total volume of 8 mL at pressure of 800 psi) showed the tumor, but there were other areas in question. **The microcatheter was exchanged for a 0.027 inch Direxion HI FLO Torqueable Microcatheter, and a repeat angiogram showed innumerable smaller tumors as well.** (Figure 3).

An intraprocedural decision was made to forego embolization and administer macroaggregated albumin to prepare for yttrium 90 treatment. **The higher flow rates and pounds per square inch that the Direxion Microcatheter provides completely changed this patient’s management.** Had he gone on to ablation, only one of his tumors would have been addressed. By changing his treatment to yttrium 90, all of his tumors were treated, and most had a near-complete treatment response (Figure 4).

Boston Scientific
Advancing science for life™

DIREXION™ Torqueable Microcatheter

CONTROL THE FLOW

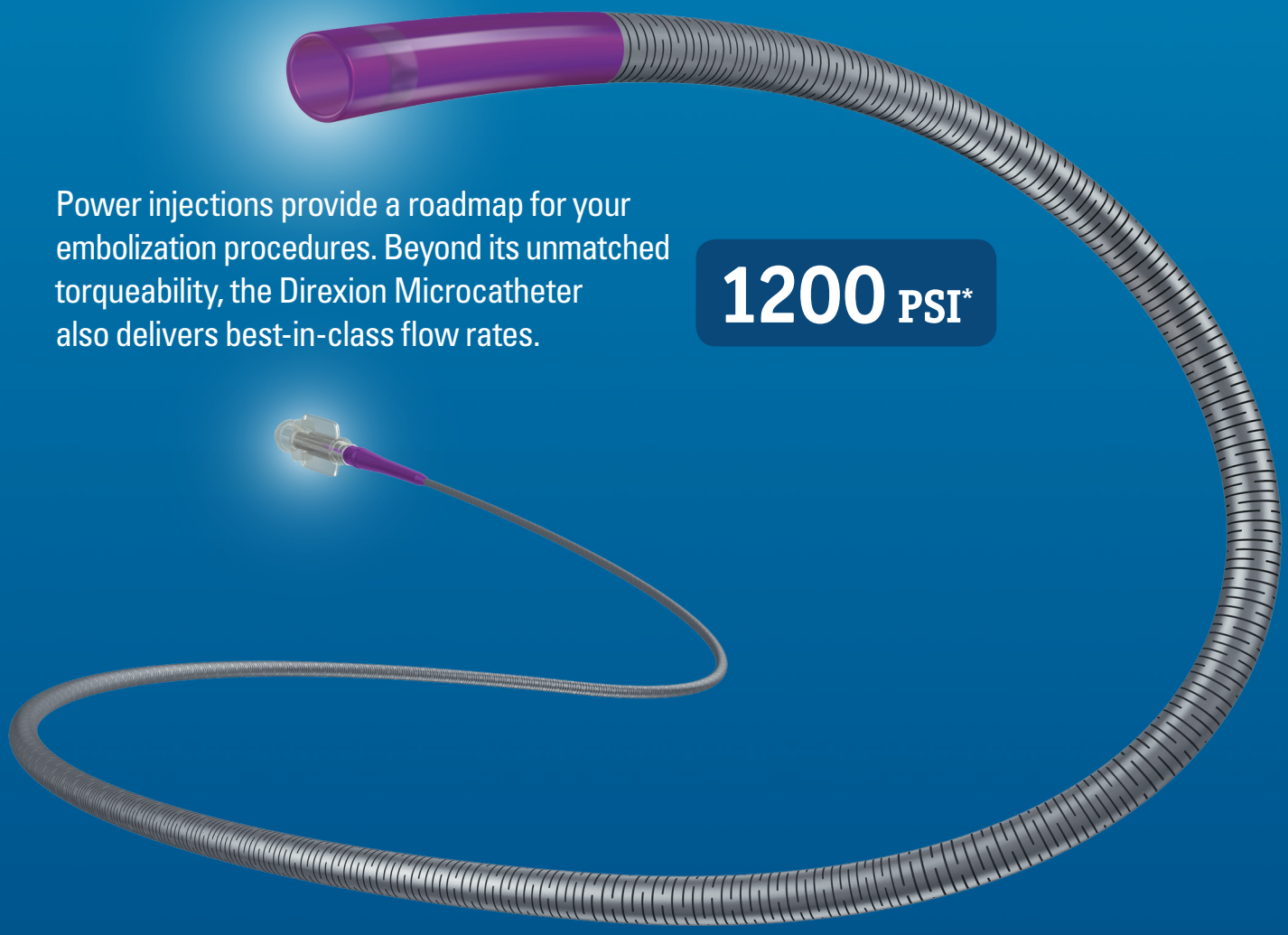

Power injections provide a roadmap for your embolization procedures. Beyond its unmatched torqueability, the Direxion Microcatheter also delivers best-in-class flow rates.

1200 PSI*

Share Your Direxion Story

www.bostonscientific.com/Direxion

*1200 psi = 8,274 kPa

DIREXION™ DIREXION HI-FLO™

CAUTION: Federal law (USA) restricts this device to sale by or on the order of a physician. Rx only. Prior to use, please see the complete "Directions for Use" for more information on Indications, Contraindications, Warnings, Precautions, Adverse Events, and Operator's Instructions.

INTENDED USE/INDICATIONS FOR USE: The Direxion and Direxion HI-FLO Torqueable Microcatheters are intended for peripheral vascular use. The pre-loaded Fathom and Transend Guidewires can be used to selectively introduce and position the microcatheter in the peripheral vasculature. The microcatheter can be used for controlled and selective infusion of diagnostic, embolic, or therapeutic materials into the vessel. **CONTRAINDICATIONS:** None known. **WARNINGS:** • Never advance or withdraw an intravascular device against resistance until the cause of resistance is determined by fluoroscopy. Movement of the microcatheter or guidewire against resistance may result in damage or separation of the microcatheter or guidewire tip, or vessel perforation. • This Direxion Microcatheter family is not intended for use in the coronary vasculature or neurovasculature. • The Direxion HI-FLO Microcatheter is not designed for the delivery of embolic coils. • Use of excessive force to manipulate the microcatheter against resistance can cause a fracture in the nitinol shaft. Take care not to over-torque the microcatheter, and to relieve any tension before withdrawal by rotating the microcatheter in the opposite direction. **PRECAUTIONS:** • This device should be used only by physicians thoroughly trained in percutaneous, intravascular techniques and procedures. • Do not introduce the microcatheter without guidewire support as this may cause damage to the proximal shaft of the catheter. • Because the microcatheter may be advanced into narrow sub-selective vasculature, repeatedly assure that the microcatheter has not been advanced so far as to interfere with its removal. **ADVERSE EVENTS:** The Adverse Events include, but are not limited to: • Allergic reaction • Death • Embolism • Hemorrhage/Hematoma • Infection • Pseudoaneurysm • Stroke • Vascular thrombosis • Vessel occlusion • Vessel spasm • Vessel trauma (dissection, perforation, rupture) **REV AB**

Indications, contraindications, warnings and instructions for use can be found in the product labeling supplied with each device. Information for the use only in countries with applicable health authority product registrations. This material is not intended for use or distribution in France.

Boston Scientific
Advancing science for life™

CASE STUDY

Share Your Direxion Story

Embolization for Chest Wall Hemorrhage

Brian S. Geller, MD and Chris Stephens, MD – Gainesville, Florida

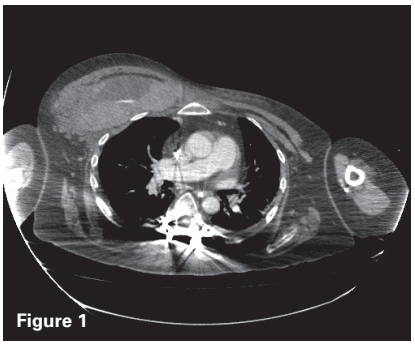
Figure 1

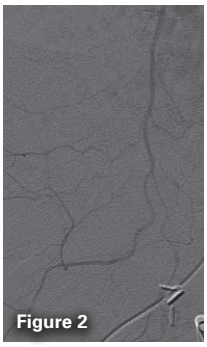
Figure 2

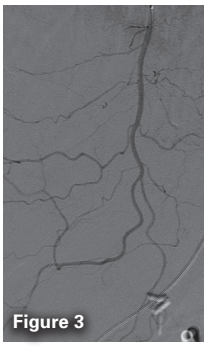
Figure 3

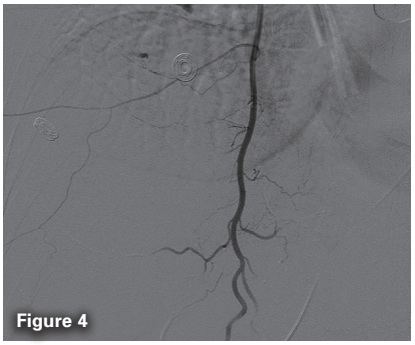
Figure 4

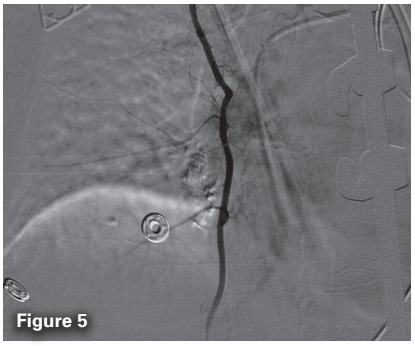
Figure 5

A 58-year-old woman was admitted to the hospital for sacral wound debridement. The patient had a history of hypercoagulability and was on anticoagulation medication before and after surgery. She presented to the interventional radiology department for treatment of a spontaneous chest wall hemorrhage several weeks after her surgery. After using standard techniques to access the right common femoral artery, a 5 F sheath was placed. Subsequently, a VERT catheter and a hydrophilic guidewire were used to cannulate the right axillary artery. An angiogram failed to show the source of bleeding (Figure 1).

The VERT catheter was retracted and, using a 0.021 inch Direxion Torqueable Microcatheter and Fathom 16 Guidewire, the thyrocervical trunk was cannulated. The following angiogram result was also negative. The VERT catheter was repositioned proximal to the internal mammary artery. The Direxion Microcatheter and Fathom-16 Guidewire were used to cannulate the right internal mammary artery. The angiogram showed a questionable blush (Figure 2).

> **“By starting with the 0.021 inch Direxion, this reduced overall procedure time and equipment cost.”**

The Direxion Microcatheter was advanced below the level of the diaphragm. The angiogram showed active hemorrhage from a perforator vessel (Figure 3). Gelfoam slurry was instilled through the Direxion Microcatheter. A follow-up angiogram showed no further hemorrhage from that artery; however, two additional vessels were bleeding (Figure 4), which also responded well to gelfoam (Figure 5).

Based on the CT scan, it was originally thought that the treatment of this hemorrhage would require coil embolization; therefore, a 0.021 inch microcatheter would be required. I also thought that we would need higher flow rates to visualize the area of hemorrhage. **Normally, this would require starting with a 0.027 inch microcatheter and then exchanging for a 0.021 inch microcatheter for coil placement. By starting with the 0.021 inch Direxion Microcatheter, this reduced overall procedure time and equipment cost.**

Boston Scientific
Advancing science for life™

DIREXION™ Torqueable Microcatheter

CONTROL THE FLOW

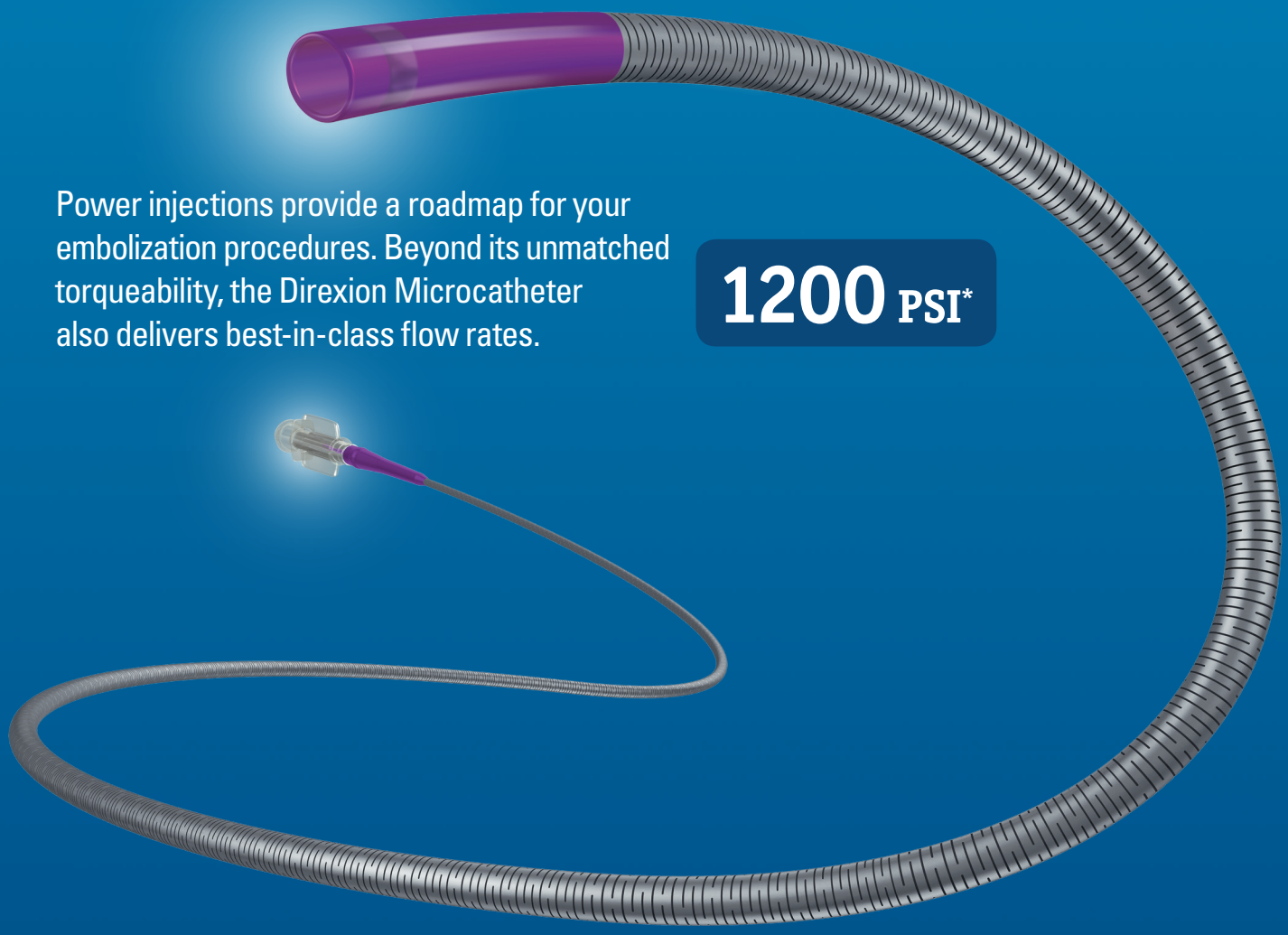

Power injections provide a roadmap for your embolization procedures. Beyond its unmatched torqueability, the Direxion Microcatheter also delivers best-in-class flow rates.

1200 PSI*

Share Your Direxion Story

www.bostonscientific.com/Direxion

*1200 psi = 8,274 kPa

DIREXION™ DIREXION HI-FLO™

CAUTION: Federal law (USA) restricts this device to sale by or on the order of a physician. Rx only. Prior to use, please see the complete "Directions for Use" for more information on Indications, Contraindications, Warnings, Precautions, Adverse Events, and Operator's Instructions.

INTENDED USE/INDICATIONS FOR USE: The Direxion and Direxion HI-FLO Torqueable Microcatheters are intended for peripheral vascular use. The pre-loaded Fathom and Transend Guidewires can be used to selectively introduce and position the microcatheter in the peripheral vasculature. The microcatheter can be used for controlled and selective infusion of diagnostic, embolic, or therapeutic materials into the vessel. **CONTRAINDICATIONS:** None known. **WARNINGS:** • Never advance or withdraw an intravascular device against resistance until the cause of resistance is determined by fluoroscopy. Movement of the microcatheter or guidewire against resistance may result in damage or separation of the microcatheter or guidewire tip, or vessel perforation. • This Direxion Microcatheter family is not intended for use in the coronary vasculature or neurovasculature. • The Direxion HI-FLO Microcatheter is not designed for the delivery of embolic coils. • Use of excessive force to manipulate the microcatheter against resistance can cause a fracture in the nitinol shaft. Take care not to over-torque the microcatheter, and to relieve any tension before withdrawal by rotating the microcatheter in the opposite direction. **PRECAUTIONS:** • This device should be used only by physicians thoroughly trained in percutaneous, intravascular techniques and procedures. • Do not introduce the microcatheter without guidewire support as this may cause damage to the proximal shaft of the catheter. • Because the microcatheter may be advanced into narrow sub-selective vasculature, repeatedly assure that the microcatheter has not been advanced so far as to interfere with its removal. **ADVERSE EVENTS:** The Adverse Events include, but are not limited to: • Allergic reaction • Death • Embolism • Hemorrhage/Hematoma • Infection • Pseudoaneurysm • Stroke • Vascular thrombosis • Vessel occlusion • Vessel spasm • Vessel trauma (dissection, perforation, rupture) **REV AB**

Indications, contraindications, warnings and instructions for use can be found in the product labeling supplied with each device. Information for the use only in countries with applicable health authority product registrations. This material is not intended for use or distribution in France.