

Outcomes of Surgical Resection after Radioembolization for Hepatocellular Carcinoma

Ahmed Gabr, MD, Nadine Abouchaleh, BA, Rehan Ali, MD, Talia Baker, MD, Juan Caicedo, MD, Nitin Katariya, MD, Michael Abecassis, MD, Ahsun Riaz, MD, Robert J. Lewandowski, MD, and Riad Salem, MD, MBA

ABSTRACT

Purpose: To longitudinally study clinical and radiologic outcomes of patients with hepatocellular carcinoma (HCC) who underwent yttrium-90 transarterial radioembolization (TARE) as a bridge to surgical resection.

Materials and Methods: TARE was performed in 31 patients with HCC before resection. Of patients, 25 underwent major hepatic resection (16 received right hepatectomy and 9 received trisegmentectomy), and 6 underwent partial hepatectomy. Clinical outcomes after TARE and after resection were recorded. Future liver remnant (FLR) was calculated before and after TARE, and actual liver remnant volume was calculated after resection. Radiologic response after TARE and pathologic necrosis were assessed. Overall and recurrence-free survivals after resection were estimated.

Results: Median time between TARE and resection was 2.9 months (interquartile range [IQR]: 2–5 months). Median FLR hypertrophy after TARE (and before resection) was 23.3% (IQR:10%–48%) for patients who had radiation lobectomy and 9% (IQR: 6%–25%) for patients who had radiation segmentectomy ($P = .037$). Median augmented hypertrophy of the liver remnant 3 months after resection was 72% (IQR:45%–88%) in patients who had radiation lobectomy and 94% (IQR: 72%–146%) in patients who had radiation segmentectomy. Complete, 50%–99%, and < 50% pathologic tumor necrosis was identified in 14 (45%), 10 (32%), and 7 (23%) tumors. Disease control was achieved in all 31 patients. Survival rates at 1 and 3 years were 96% and 86%, respectively. Median recurrence-free survival was 34.2 months (95% confidence interval,18.7–34.2).

Conclusions: TARE can serve as a safe bridge to resection providing FLR hypertrophy and disease control.

ABBREVIATIONS

CI = confidence interval, EASL = European Association for the Study of the Liver, FLR = future liver remnant, HCC = hepatocellular carcinoma, IQR = interquartile range, PVE = portal vein embolization, TARE = transarterial radioembolization

Surgical resection is considered a curative treatment for hepatocellular carcinoma (HCC). However, compromised liver function and portal hypertension may preclude resection (1). Additionally, many patients are excluded from surgery because of metastatic disease, inadequate future liver remnant (FLR), tumor characteristics (size,

number), and proximity to major vascular pedicles (2). Ideally, candidates for surgical resection present with solitary/unilobar HCC without vascular invasion, preserved hepatic function, and no evidence of portal hypertension (3). Yttrium-90 transarterial radioembolization (TARE) is an intra-arterial delivery of radioactive

From the Section of Interventional Radiology (A.G., N.A., R.A., A.R., R.J.L., R.S.), Department of Radiology, Northwestern Memorial Hospital, and Department of Medicine, Division of Hematology and Oncology (R.J.L., R.S.), Robert H. Lurie Comprehensive Cancer Center, and Comprehensive Transplant Center (T.B., J.C., N.K., M.A., R.S.), Division of Transplantation, Department of Surgery, Northwestern University Feinberg School of Medicine, 676 N. St. Clair, Suite 800, Chicago, IL 60611. Received September 1, 2017; final revision received June 1, 2018; accepted June 4, 2018. **Address correspondence to R.S.;** E-mail: r-salem@northwestern.edu; Twitter handle: [@NorthwesternIR](https://twitter.com/NorthwesternIR)

R.J.L. and R.S. are paid scientific advisors to BTG (London, United Kingdom). None of the other authors have identified a conflict of interest.

Figure E1 and Table E1 can be found by accessing the online version of this article on www.jvir.org and clicking on the Supplemental Material tab.

© SIR, 2018

J Vasc Interv Radiol 2018; ■:1–9

<https://doi.org/10.1016/j.jvir.2018.06.027>

EDITORS' RESEARCH HIGHLIGHTS

- This single-center retrospective investigation reports imaging and clinical outcomes for patients who underwent glass yttrium-90 transarterial radioembolization (TARE) of hepatocellular carcinoma (HCC) with subsequent major hepatic surgical resection. Outcomes included future liver remnant (FLR) hypertrophy, tumor radiologic and pathologic response, adverse events, and overall survival.
- Between 2011 and 2016, 31 patients (predominantly Barcelona Clinic Liver Cancer stage A/B), were treated; 25 underwent major surgical resection a median of 2.9 months after lobar ($n = 20$) or segmental ($n = 5$) TARE. In patients undergoing resection, median baseline FLR increased from 35% to 45% (23% hypertrophy) after lobar TARE and from 32% to 34% (9% hypertrophy) after segmental TARE.
- Objective tumor response rate by European Association for the Study of the Liver criteria was 58% (29% complete and 29% partial responses); 77% of tumors showed $> 50\%$ pathologic necrosis at surgical resection. Adverse events following TARE included 1 case of Common Terminology Criteria for Adverse Events v4.0 grade 3/4 bilirubin toxicity; grade IIIA or higher Clavien-Dindo adverse events occurred in 16% after surgery. Overall survival was 96%, 96%, and 86% at 1, 2, and 3 years after surgery.
- These results suggest that TARE can effectively treat HCC while resulting in contralateral lobar hypertrophy, which may enhance safe and effective major hepatic surgical resection.

microspheres to treat hepatic cancers. (4–7). In HCC, TARE has been found to effectively induce remnant liver hypertrophy, while simultaneously providing tumor control (7,8). Although still a relatively new concept compared with portal vein embolization (PVE), the standard technique for patients with small FLR, TARE has been found to achieve volumetric changes comparable to PVE, although with differing time kinetics. Treatment with TARE also concurrently has the added benefit of treating the tumor during the time interval of FLR hypertrophy. Therefore, TARE can be used in the preoperative setting to optimize patients with small FLR for surgical resection (7). There are limited data on outcomes of patients undergoing resection following TARE. This study was performed to evaluate short-term and long-term outcomes of patients with HCC who underwent surgical resection following TARE.

MATERIALS AND METHODS

Study Population

This retrospective study was compliant with the Health Insurance Portability and Accountability Act and approved by the institutional review board. The study included all patients who underwent surgical resection

after radioembolization between 2011 and 2016. After initial treatment with TARE, 31 patients with HCC successfully underwent surgical resection. Of 155 patients with HCC treated with TARE between 2011 and 2016 who displayed preserved liver function (Child-Pugh \leq B7), unilobar disease, and no portal vein thrombus or metastatic disease (potential resection candidates), 33 patients underwent transplantation, 91 patients were evaluated for transplantation (eg, unresectable bilobar disease within Milan criteria), and 30 patients underwent resection (20%). One patient displayed excellent response to TARE despite baseline vascular invasion and underwent subsequent resection; he was included in this study. **Table 1** summarizes baseline characteristics of the 31 patients with HCC.

TARE Treatment

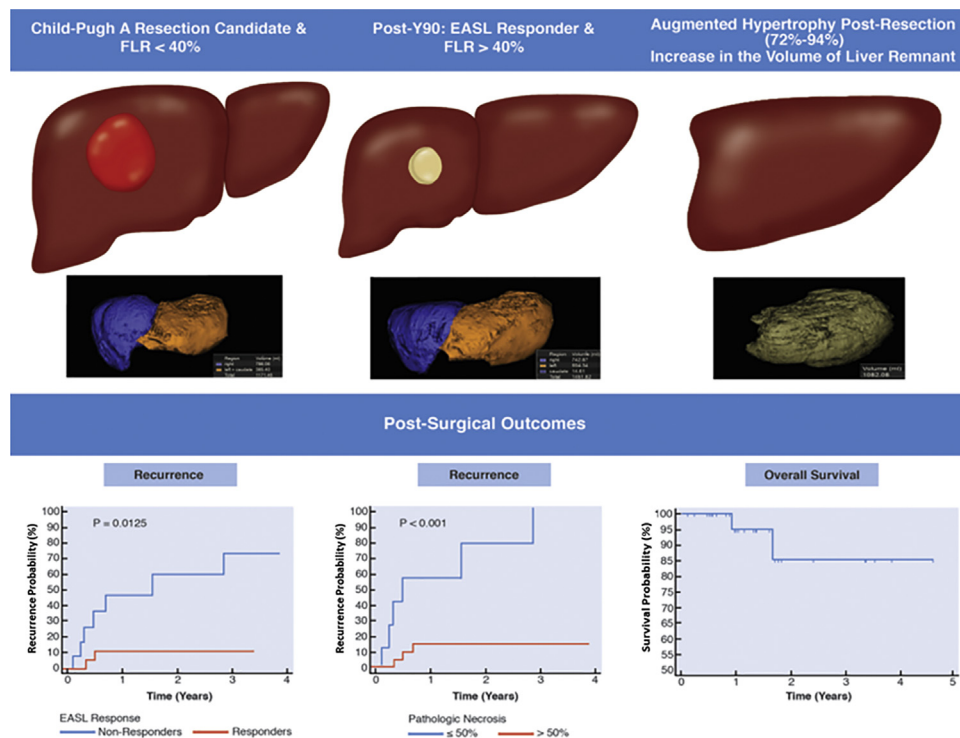
TARE was performed using glass microspheres (Thera-sphere; BTG International, London, United Kingdom) (9,10). All patients underwent angiography and technetium-99m macroaggregated albumin scan before treatment. In some cases, a same-day TARE paradigm was applied (11). Most patients received TARE to the right lobe, with some receiving additional left hepatic artery (segment 4) infusion for cross-perfusion to the right ($n = 3$). The majority received radiation lobectomy treatment to induce FLR hypertrophy, of whom 11 patients had solitary tumors and were candidates for superselective segmental treatments, but they lacked sufficient FLR. Hence, these patients received segmental treatments to at minimum achieve local tumor control (7,12). Target dose was 130–150 Gy for lobar infusions and > 190 Gy for segmental ablative treatments.

Volumetric Assessment

Volumetric assessment was conducted on patients who underwent major surgical resection (total right lobectomy or extended right lobectomy [trisegmentectomy]) using Vitrea Core Version 6.9 (Vital Images, Inc, Minnetonka, Minnesota). Magnetic resonance imaging or computed tomography was performed at baseline, 1 month after TARE, every 3 months until resection, and every 3 months after resection. Liver volume calculations were performed at baseline and at imaging following TARE based on the planned resection on patients who underwent right hepatic lobectomy or extended right lobectomy. The details of liver volume calculations have been previously described (7). Parenchymal volumes were calculated using standard anatomy as follows (13).

Volumes following TARE. FLR was defined as the ratio (in %) of the left lobe over total liver volume. %FLR hypertrophy was defined as the percentage of hypertrophy of FLR from baseline. Tumor volumes were excluded from analysis to perform a pure liver parenchymal analysis. Caudate lobe was included in the FLR calculations.

Visual Synopsis



% FLR hypertrophy =

$$\frac{\text{FLR pre Surgery} - \text{FLR pre TARE}}{\text{FLR pre TARE}} \%$$

Volumes following Resection. To study the degree of hypertrophy after resection, remnant liver volumes before and after surgery per the equation below were compared:

% Hypertrophy after resection =

$$\frac{\text{Remnant after resection} - \text{Remnant before resection}}{\text{Remnant before resection}} \%$$

Follow-up Evaluation and Imaging Response

Clinical and laboratory adverse events at 1 month after TARE were classified by Common Terminology Criteria for Adverse Events v4.0 (14). The Clavien-Dindo classification was used to assess 1-month postoperative complications (15). Response was evaluated by World Health Organization and European Association for the Study of the Liver (EASL) criteria. All imaging, including 74 magnetic resonance imaging scans and 25 computed tomography scans, was reviewed by a blinded board-certified radiologist with > 5 years of experience. Imaging after resection was performed at 3-month intervals for the first year and at 6-month intervals thereafter (16,17).

Operative Outcomes

Intraoperative and postoperative variables (resection, operative time, blood loss, postoperative complications, discharge time) were tabulated. Finally, an exploratory analysis of serum phosphorus and magnesium changes within 10 days after resection was performed.

Pathologic Evaluation

Liver explants were evaluated by pathology staff at our institution. One-centimeter sections of the entire liver were prepared. Representative samples of the tumors were stained with routine hematoxylin-eosin stains for histologic examination. The presence of coagulative necrosis was noted. All tumors were thoroughly examined for the presence of viable neoplastic tissue. Percentage necrosis of the treated tumors was tabulated using the following schema as described by the pathologist: 100% histologic necrosis (defined as absence of any viable tissue), > 50% necrosis (defined as significant necrosis but with clusters of viable tissue), or < 50% necrosis (defined as minimal necrosis). Pathologic outcome was classified as complete (100%), extensive (50%–99%), and partial necrosis (< 50%) (18).

Statistical Analysis

Descriptive statistics were used, and variables were expressed by median and interquartile range (IQR). Volumetric data of patients who had radiation lobectomy versus segmentectomy were compared using independent samples *t* test. FLR before and after TARE was compared using

Table 1. Baseline Characteristics

Characteristic	Value
Demographics	
Age, y	63 (35–76)
Male	22 (71)
Female	9 (29)
Tumor maximum dimension, cm	4.9 (1.5–21)
Method of diagnosis	
Imaging	18 (58)
Biopsy	13 (42)
ECOG performance status	
0	19 (61)
1	12 (39)
Underlying liver disease	
Alcohol	2 (7)
HCV	17 (55)
HCV and alcohol	1 (3)
HBV	6 (19)
NASH	1 (3)
Unknown	4 (13)
Child-Pugh score	
5, 6	29 (94)
7	2 (6)
BCLC	
A	24 (77)
B	4 (13)
C	3 (10)
Bilirubin, mg/dL	0.6 (0.3–1.1)
Albumin, g/dL	4.0 (2.8–4.3)
Prior liver-directed therapy	
None	28 (90)
Resection	2 (7)
Radiofrequency ablation	1 (3)
No. TARE treatments	
1	27 (87)
2	3 (10)
3	1 (3)
Imaging cirrhosis	
Present	15 (48)
Absent	16 (52)

Note—Values are presented as number (%) or median (range). BCLC = Barcelona Clinic Liver; ECOG = Eastern Cooperative Oncology Group; HBV = hepatitis B virus; HCV = hepatitis C virus; NASH = nonalcoholic steatohepatitis; TARE = trans-arterial radioembolization.

paired sample *t* test. Recurrence-free survival and overall survival were calculated using Kaplan-Meier analysis (log-rank test) from the date of resection to death or last follow-up. *P* < .05 was considered to be statistically significant. To compare recurrence of different prognostic factors, time to recurrence was calculated by Kaplan-Meier method, and log-rank test was used to compare between responders versus nonresponders, necrosis > 50% versus necrosis ≤ 50%, and baseline tumor size ≤ 5 cm versus > 5 cm. An analysis of relative risk of recurrence was

conducted using 2 × 2 table method. Analyses were performed using MedCalc Statistical Software Version 17.9.2 (MedCalc Software bvba, Ostend, Belgium).

RESULTS

Radioembolization

A single TARE treatment was administered to 27 patients to achieve target treatment tumor response as well as contralateral hypertrophy, whereas 3 patients received 2 treatments, and 1 patient received 3 treatments. Median dose was 128 Gy (IQR: 113–143 Gy) for lobar treatments and 254 Gy (IQR: 227–281 Gy) for segmental ablative treatments. Of 31 patients, 25 patients underwent major right hepatic lobe resection (lobectomy [*n* = 16] and trisegmentectomy [*n* = 9]), and 6 patients underwent minor left hepatic lobe resection (partial hepatectomy) (Fig 1).

At 1 month after TARE, 6 (19%) patients had mild (grade 1) alanine aminotransferase toxicity. Two (6%) and 2 (6%) patients had grade 1 and grade 2 aspartate aminotransferase toxicities, respectively. Ten (32%) and 2 (6%) patients had grade 1 and grade 2 alkaline phosphatase toxicity, respectively. Only 1 patient (3%) developed reversible grade 3 bilirubin toxicity, whereas 4 (13%) and 1 (3%) patients showed mild grade 1 and 2 toxicities, respectively. Nine (29%) and 2 (6%) patients had mild grade 1 and 2 toxicities, respectively. No other grade 3 or 4 toxicities were encountered by any of the patients throughout the follow-up period. None of the patients developed radiation-induced adverse events (pneumonitis, cholecystitis, cholangitis, liver disease, gastric ulcers) (Table 2) (19).

Volumetric Data and Response to TARE

Table 3 presents baseline (before TARE) and follow-up (before and after resection) volumetric data for 20 patients who had radiation lobectomy and 5 patients who had radiation segmentectomy. Baseline FLR increased from a median of 35% (IQR: 27%–42%) to a median of 45% (IQR: 40%–57%) (*P* < .001), whereas FLR in radiation segmentectomy slightly increased from a median of 32% (IQR: 25%–35%) to a median of 34% (IQR: 30%–40.5%) (*P* = .002). %FLR hypertrophy for patients who had radiation lobectomy was significantly higher compared with %FLR hypertrophy for patients who had radiation segmentectomy: median 23.3% (IQR: 10%–48%) versus 9% (IQR: 6%–25%) (*P* = .037). Augmented hypertrophy at 3 months after resection was noted in both patients who had lobectomy and patients who had segmentectomy with a median increase in liver remnant volume of 504 mL (IQR: 433–664 mL) and 423 mL (IQR: 263–925 mL) in lobectomy and segmentectomy patients, respectively (*P* = .77).

Of 20 patients who underwent radiation lobectomy to the right lobe, 12 patients had baseline FLR < 40%, of whom 8 patients had FLR > 40% after TARE and 4 patients continued to have FLR < 40%, but their left lobe volume size was considered sufficient for operation. All 5 patients who underwent segmental treatment had baseline FLR < 40%, and

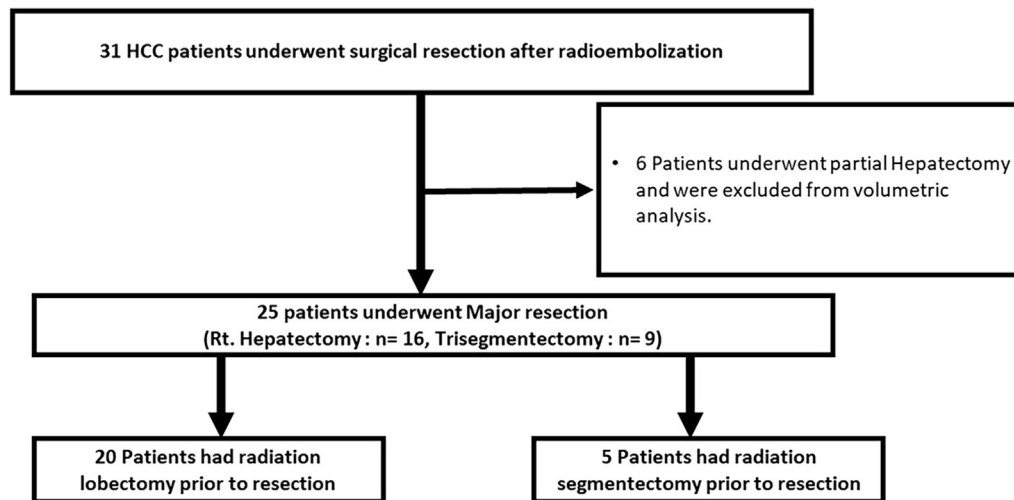


Figure 1. Patient flow chart.

Table 2. Toxicity Grades 1 Month after TARE

	No Toxicity	Grade 1	Grade 2	Grade 3	Grade 4
ALT	25 (81%)	6 (19%)	0 (0%)	0 (0%)	0 (0%)
AST	27 (88%)	2 (6%)	2 (6%)	0 (0%)	0 (0%)
ALP	19 (62%)	10 (32%)	2 (6%)	0 (0%)	0 (0%)
Albumin	20 (65%)	9 (29%)	2 (6%)	0 (0%)	0 (0%)
Bilirubin	25 (81%)	4 (13%)	1 (3%)	1 (3%)	0 (0%)

ALP = alkaline phosphatase; ALT = alanine aminotransferase; AST = aspartate aminotransferase; TARE = transarterial radioembolization.

only 1 patient achieved FLR > 40% after TARE. However, all patients had adequate liver remnant volume that deemed them operable.

By EASL response criteria, there were 13 (39%) patients with stable disease, 9 (29%) patients with partial response, and 9 (29%) patients with complete response. Median time to partial response was 1 month (95% confidence interval [CI], 0.9–1.6); median time to complete response was 3.3 months (95% CI, 1.2–5.5). By World Health Organization criteria, there were 3 (10%) patients with progressive disease, 20 (64%) patients with stable disease, and 8 (26%) patients with partial response (Table E1 [available online on the article's Supplemental Material page at www.jvir.org]). Figure 2a–c presents an example of successful lobectomy followed by curative resection.

Surgical Resection following TARE

Median time from TARE to resection was 2.9 months (IQR: 2–5 months). Of 31 patients, 16 (52%) underwent right lobectomy, 9 (29%) underwent extended right lobectomy (trisegmentectomy), and 6 (19%) underwent partial left hepatectomy (Table 4). Effects of TARE were evident in the demarcated liver between treated and untreated liver. Increased inflammation and induration were seen surrounding the liver in the TARE-treated

sectors. This prompted changes to typical surgical resection techniques, including more sharp dissection. Adhesions to adjacent structures were severed without complications; structures surrounding the liver did not sustain surgical injuries. Median operative time was 4 hours (range, 2–9.6 hours), with estimated blood loss of 500 mL (range, 20–3,000 mL). Median hospital stay after resection was 3 days (range, 2–10 days). The Pringle maneuver is not routinely used during liver transection at this center (Table 3). Postoperative laboratory values are displayed in Figure E1a–c (available online on the article's Supplemental Material page at www.jvir.org). Within the first postoperative week, there was no statistically significant change in phosphorus and magnesium levels. Bilirubin increased during the first postoperative week from 0.8 mg/dL (95% CI, 0.7–0.9) on day 0 to 1.7 mg/dL (95% CI, 1.1–2.2) on day 7 but returned to normal levels within 1 month. Grade IIIA or higher Calvien-Dindo morbidity occurred in 5 patients (16%). Four patients developed a postoperative biliary anastomotic leak requiring surgical intervention. One patient had a pleural effusion and subsequently underwent thoracentesis.

Pathologic Necrosis

Seven patients had < 50% necrosis (23%). The remaining 24 patients exhibited > 90% necrosis: 50%–99% necrosis in 10 patients (32%) and 100% necrosis in 14 patients (45%) (Table E1 [available online on the article's Supplemental Material page at www.jvir.org]) and Fig 2d, e).

Recurrence

Nine (29%) patients developed recurrence. Two patients developed metastases to the lungs and bones, and 7 patients developed new liver tumors. Median time to recurrence was 34.3 months (95% CI, 18.8–34.3 months). According to EASL criteria, 18 patients responded (partial response/complete response). Only 2 (11%) of the

Table 3. Volumetric Analysis of Patients Who Underwent Major Hepatic Resection

	Lobar (n = 20)	Segmental (n = 5)	P Value
Before TARE			
Baseline liver remnant volume, mL	583 (446–725)	329 (273–732)	.3
Baseline future liver remnant, %	35 (27–42)	32 (25–35)	.12
After TARE/before resection			
Liver remnant volume after TARE, mL	779 (660–910)	373 (310–806)	.05
Future liver remnant after TARE, %	45 (40–57)	34 (30–41)	.008
Change in liver remnant volume, mL	187 (112–315)	44 (–15 to 126)	.02
Hypertrophy in FLR, %	23 (10–48)	9 (6–25)	.037
After resection			
Liver remnant volume 3 months after resection, mL	1,276 (1,160–1,576)	718 (612–1,731)	.38
Liver remnant volume increase 3 months after resection, mL	504 (433–664)	423 (263–925)	.77
Hypertrophy of liver remnant, %	72 (45–88)	94 (72–146)	.14

Note—All values are median (interquartile range).

FLR = future liver remnant; TARE = transarterial radioembolization.

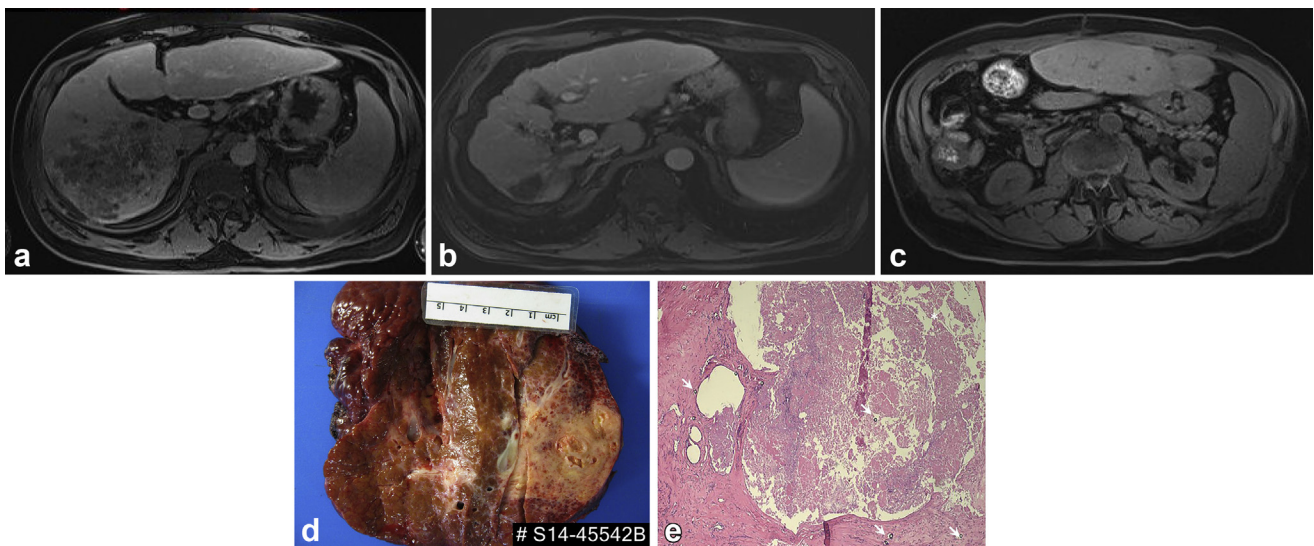


Figure 2. (a) Magnetic resonance imaging obtained before TARE in a 63-year-old man showing a 12.9 × 11.3 cm tumor in segments 5–8 with portal vein invasion. (b) Magnetic resonance imaging obtained 2 years after TARE displaying a favorable response to TARE, with tumor now measuring 2.2 × 1.9 cm deeming the patient a surgical candidate. (c) Magnetic resonance imaging obtained at 3 months after extended right lobectomy displaying hypertrophied liver remnant. (d) Explant showing tumor with pale discoloration and necrosis within a background of liver with cirrhosis. (e) Histopathologic section of liver explant necrotic debris (asterisk). Glass microspheres are visible in the background (arrows).

responders developed recurrence. The remaining 13 patients who had stable disease had 7 (54%) recurrences. The relative risk for recurrence was 4.8 (95% CI, 1.2–9.7) for EASL nonresponders versus 0.2 (95% CI, 0.05–0.8; $P = .02$) for EASL responders, with EASL response as a significant prognosticator of recurrence (hazard ratio = 0.18; 95% CI, 0.05–0.7; $P = .0125$) (Fig 3a). Regarding pathologic necrosis, 6 of 7 (86%) patients who displayed < 50% tumor necrosis developed recurrence. Conversely, only 3 (24%) of the 24 patients with 50%–99% tumor necrosis developed recurrence ($P = .004$). Pathologic necrosis

was found to be a significant prognosticator of recurrence (hazard ratio = 0.12; 95% CI, 0.02–0.6; $P < .001$) (Fig 3b).

Tumor size was also found to be related to risk of recurrence. None of the patients with a tumor ≤ 5 cm ($n = 17$) developed recurrence. Of the patients with index tumor sizes > 5 cm ($n = 14$), 9 (64%) had recurrences ($P < .001$) (Fig 3c, d).

Follow-up and Survival

Median follow-up time was 13 months (IQR, 8–22 months). Survival rates were 96% at 1 and 2 years (95% CI, 81–99)

Table 4. Surgical Resection Outcomes in Patients Treated with TARE

Surgical Resection	Value
Type of resection	
Right lobectomy	16 (52)
Trisegmentectomy	9 (29)
Partial hepatectomy	6 (19)
Time between TARE and surgical resection, months	2.9 (2–5)
Time to discharge, days	3 (2–5)
Estimated blood loss, mL	500 (150–1,000)
Operative time, h	4 (3.25–5.25)
Grade III or higher complications	5 (16)

Note—Values are presented as number (%) or median (range). TARE = transarterial radioembolization.

and 86% at 3 years (95% CI, 52–99). Median was not reached (Fig 4). Median recurrence-free survival was 34.2 months (95% CI, 18.7–34.2).

DISCUSSION

The results of this study suggest that TARE using glass yttrium-90 spheres may serve as a safe treatment to achieve tumor control while providing contralateral lobe volume hypertrophy. Five (16%) patients had postoperative grade III or higher complications after resection, a rate that improves on a prior study that reported on outcomes in patients with liver metastases (20). Moreover, perioperative outcomes (estimated blood loss, operative time, time to discharge, postoperative complication rates, and perioperative mortality) remained within the range reported for surgical resection without preoperative TARE (21).

A previous study found that radiation lobectomy produces significant FLR hypertrophy at a slower rate than PVE (22). However, in some reports, PVE has been associated with tumor progression before resection (22,23). Progression may limit resectability after PVE, and recurrence-free survival has been shown to be higher in patients who did not have PVE before resection (24). By contrast, in the present study, all patients demonstrated by EASL criteria stable disease (42%), partial response (29%), or complete response (29%). TARE provided tumor control, and all patients were able to safely proceed to surgical resection after TARE. Radioembolization can therefore serve as a neoadjuvant therapy before resection by providing tumor control and contralateral lobar hypertrophy.

A 3- to 6-month bridging period between TARE and resection may of interest for further studies. Patients who responded either by radiologic response by EASL criteria (complete response/partial response) or pathologically (> 50% pathologic necrosis) showed a significantly reduced risk for recurrence. Additionally, tumor size < 5 cm was correlated with lower recurrence rates. The time interval and

biologic test of time could be used to observe whether tumor size and a radiologic response to TARE can be used to predict future recurrence. The gap between the 2 procedures allows for patients to reach adequate %FLR hypertrophy and can be used to identify patients with better underlying biology. This is more evident in current liver transplant criteria for patients with HCC, where a 6-month progression-free waiting period is mandated before patients gain HCC exception points.

Hypophosphatemia and hypomagnesemia are observed postoperatively following hepatic resection and result from energy consumption from hypertrophy; their absence usually portends a poor outcome and liver failure (24,25). The fact that there was no significant decrease in serum phosphorus and magnesium levels following resection, without any evidence of liver failure, suggests that hypertrophy has already occurred as part of the radiation lobectomy process. The postoperative outcomes are consistent with another study that assessed outcomes of liver resection or transplantation following TARE (26). Measurement of phosphorus and magnesium following TARE would be of interest, as these may be a biomarker of hypertrophy and potentially predict safety of resection.

The low toxicity profile despite irradiation of non-tumor bearing liver parenchyma sheds light on the safety of TARE as a treatment option for bridging to liver resection as well as providing tumor control. In a recently published study, maximal contralateral liver hypertrophy was associated with a threshold radiation dose of 88 Gy to the normal liver parenchyma, based on data from first-week dosimetry (27). Depending on the intent, either of the 2 techniques could be used to induce FLR hypertrophy. Radiation segmentectomy could be used in patients with limited disease, where resection is favored given the mandatory 6-month waiting times for transplantation. Radiation lobectomy with lobar infusion could be considered a method to achieve tumor control and test of time before hepatic resection.

This study has several strengths. This is one of the largest cohorts reporting outcomes after TARE as well as post-surgical outcomes in patients with HCC. The granularity of liver/segmental volumes in a time-dependent manner provides important information given 6-month mandatory wait times for liver transplantation.

This study has limitations given its retrospective design and lack of a control arm. Immortal time bias is also a factor, as only patients who underwent resection were studied. This was unavoidable, as the study objective was to longitudinally investigate an exclusive cohort of patients with HCC from date of TARE until last follow-up after surgical resection.

In conclusion, TARE is a safe and effective neoadjuvant treatment for patients with HCC undergoing surgical resection that can facilitate tumor control, contralateral lobe hypertrophy, and recurrence-free survival following resection. TARE performed before resection did not complicate

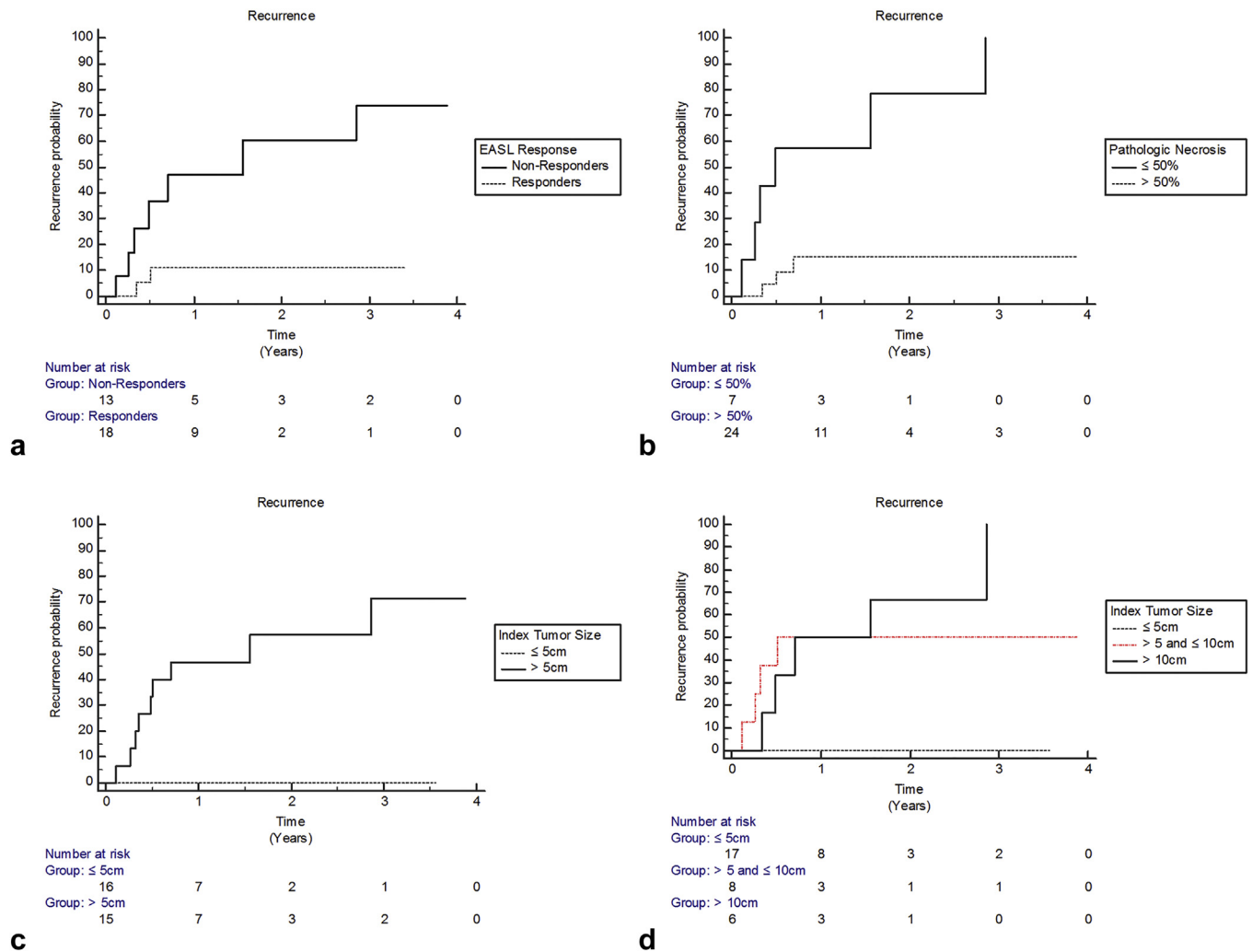


Figure 3. (a) Cumulative risk for recurrence rate in EASL responders vs nonresponders. (b) Cumulative risk for recurrence rate in patients with pathologic necrosis > 50% vs ≤ 50%. (c) Cumulative risk for recurrence rate for patients with baseline index tumor size > 5 cm vs ≤ 5 cm. (d) Cumulative risk for recurrence rate for patients with baseline index tumor size ≤ 5 cm, 5–10 cm, and > 10 cm.

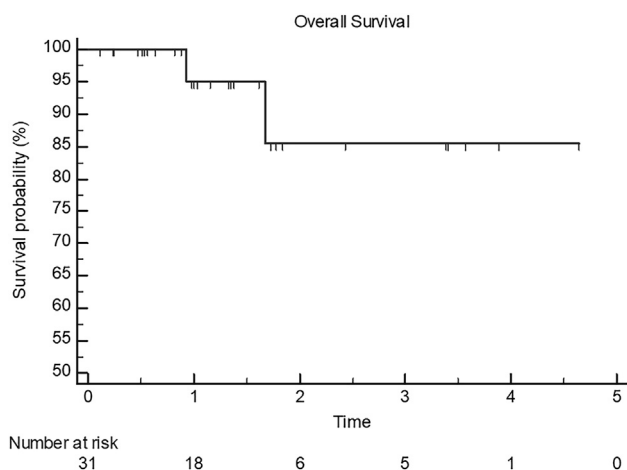


Figure 4. Kaplan-Meier overall survival curve.

the safety profile of resection when compared with an internal cohort. Patients who exhibit FLR increase following TARE and who undergo resection demonstrate augmented hypertrophy; this concept is currently being explored.

Further controlled studies are needed to confirm tumor control and recurrence-free survival compared with treatment-naïve patients undergoing surgical resection. Comparison with PVE in HCC is also of interest and should be investigated.

REFERENCES

- Schwarz RE, Smith DD. Trends in local therapy for hepatocellular carcinoma and survival outcomes in the US population. *Am J Surg* 2008; 195: 829–836.
- Farges O, Belghiti J, Kianmanesh R, et al. Portal vein embolization before right hepatectomy: prospective clinical trial. *Ann Surg* 2003; 237: 208–217.
- Torzilli G, Belghiti J, Kokudo N, et al. A snapshot of the effective indications and results of surgery for hepatocellular carcinoma in tertiary referral centers: is it adherent to the EASL/AASLD recommendations? An observational study of the HCC East-West study group. *Ann Surg* 2013; 257:929–937.
- Lewandowski RJ, Donahue L, Chocheanachaisakul A, et al. (90)Y radiation lobectomy: outcomes following surgical resection in patients with hepatic tumors and small future liver remnant volumes. *J Surg Oncol* 2016; 114:99–105.

5. Salem R, Gordon AC, Mouli S, et al. Y90 radioembolization significantly prolongs time to progression compared with chemoembolization in patients with hepatocellular carcinoma. *Gastroenterology* 2016; 151: 1155–1163.e2.
6. Kallini JR, Gabr A, Salem R, Lewandowski RJ. Transarterial radioembolization with yttrium-90 for the treatment of hepatocellular carcinoma. *Adv Ther* 2016; 33:699–714.
7. Vouche M, Lewandowski RJ, Atassi R, et al. Radiation lobectomy: time-dependent analysis of future liver remnant volume in unresectable liver cancer as a bridge to resection. *J Hepatol* 2013; 59:1029–1036.
8. Gaba RC, Lewandowski RJ, Kulik LM, et al. Radiation lobectomy: preliminary findings of hepatic volumetric response to lobar yttrium-90 radioembolization. *Ann Surg Oncol* 2009; 16:1587–1596.
9. Salem R, Thurston KG. Radioembolization with 90Yttrium microspheres: a state-of-the-art brachytherapy treatment for primary and secondary liver malignancies. Part 1: technical and methodologic considerations. *J Vasc Interv Radiol* 2006; 17:1251–1278.
10. Salem R, Lewandowski RJ, Gates VL, et al. Research reporting standards for radioembolization of hepatic malignancies. *J Vasc Interv Radiol* 2011; 22:265–278.
11. Gabr A, Kallini JR, Gates VL, et al. Same-day 90Y radioembolization: implementing a new treatment paradigm. *Eur J Nucl Med Mol Imaging* 2016; 43:2353–2359.
12. Edeline J, Lenoir L, Boudjema K, et al. Volumetric changes after 90Y radioembolization for hepatocellular carcinoma in cirrhosis: an option to portal vein embolization in a preoperative setting? *Ann Surg Oncol* 2013; 20:2518–2525.
13. Couinaud C. Errors in the topographic diagnosis of liver diseases [in French]. *Ann Chir* 2002; 127:418–430.
14. National Cancer Institute. v4.0. NCI, NIH, DHHS. May 29, 2009. NIH publication # 09-7473.
15. Dindo D, Demartines N, Clavien PA. Classification of surgical complications: a new proposal with evaluation in a cohort of 6336 patients and results of a survey. *Ann Surg* 2004; 240:205–213.
16. Kallini JR, Miller FH, Gabr A, Salem R, Lewandowski RJ. Hepatic imaging following intra-arterial embolotherapy. *Abdom Radiol (NY)* 2016; 41:600–616.
17. Bruix J, Sherman M, Llovet JM, et al. Clinical management of hepatocellular carcinoma. Conclusions of the Barcelona-2000 EASL conference. European Association for the Study of the Liver. *J Hepatol* 2001; 35:421–430.
18. Riaz A, Kulik L, Lewandowski RJ, et al. Radiologic-pathologic correlation of hepatocellular carcinoma treated with internal radiation using yttrium-90 microspheres. *Hepatology* 2009; 49:1185–1193.
19. Riaz A, Awais R, Salem R. Side effects of yttrium-90 radioembolization. *Front Oncol* 2014; 4:198.
20. Wright GP, Marsh JW, Varma MK, Doherty MG, Bartlett DL, Chung MH. Liver resection after selective internal radiation therapy with yttrium-90 is safe and feasible: a bi-institutional analysis. *Ann Surg Oncol* 2017; 24: 906–913.
21. Nguyen KT, Gamblin TC, Geller DA. World review of laparoscopic liver resection—2,804 patients. *Ann Surg* 2009; 250(5):831–841.
22. Pamecha V, Glantzounis G, Davies N, Fusai G, Sharma D, Davidson B. Long-term survival and disease recurrence following portal vein embolization prior to major hepatectomy for colorectal metastases. *Ann Surg Oncol* 2009; 16:1202–1207.
23. Hayashi S, Baba Y, Ueno K, et al. Acceleration of primary liver tumor growth rate in embolized hepatic lobe after portal vein embolization. *Acta Radiol* 2007; 48:721–727.
24. Buell JF, Berger AC, Plotkin JS, Kuo PC, Johnson LB. The clinical implications of hypophosphatemia following major hepatic resection or cryosurgery. *Arch Surg* 1998; 133:757–761.
25. Giovannini I, Chiarla C, Nuzzo G. Pathophysiologic and clinical correlates of hypophosphatemia and the relationship with sepsis and outcome in postoperative patients after hepatectomy. *Shock* 2002; 18: 111–115.
26. Pardo F, Sangro B, Lee RC, et al. The Post-SIR-Spheres Surgery Study (P4S): retrospective analysis of safety following hepatic resection or transplantation in patients previously treated with selective internal radiation therapy with yttrium-90 resin microspheres. *Ann Surg Oncol* 2017; 24:2465–2473.
27. Palard X, Edeline J, Rolland Y, et al. Dosimetric parameters predicting contralateral liver hypertrophy after unilobar radioembolization of hepatocellular carcinoma. *Eur J Nucl Med Mol Imaging* 2018; 45: 392–401.

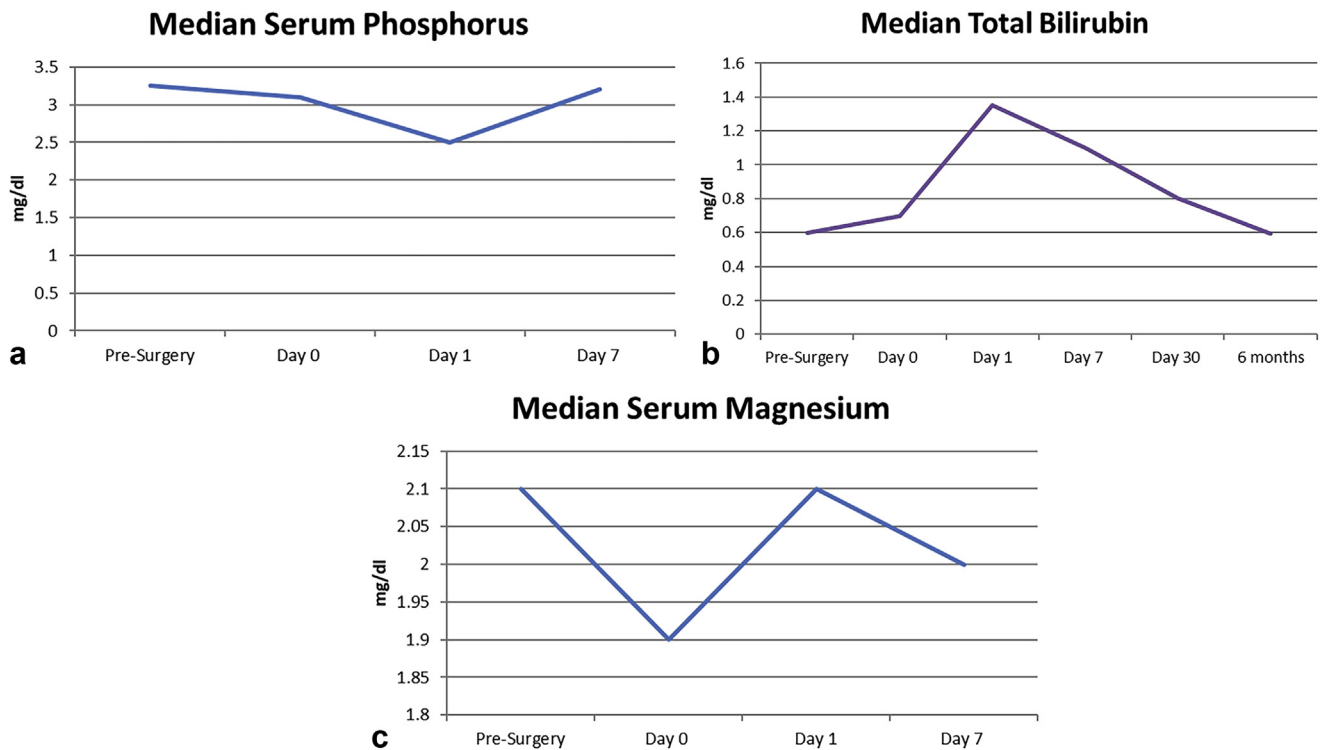


Figure E1. (a) Trend analysis showing stable postoperative serum phosphorus. (b) Trend analysis showing stable postoperative serum total bilirubin. (c) Trend analysis showing stable postoperative serum magnesium.

Table E1. Radiologic and Pathologic Tumor Response to TARE

Tumor Response	Total (N = 31)	Radiation Lobectomy (n = 22)	Radiation Segmentectomy (n = 9)
EASL response			
Progressive disease	0 (0%)	0 (0%)	0 (0%)
Stable disease	13 (42%)	10 (45%)	3 (33%)
Partial response	9 (29%)	5 (23%)	4 (45%)
Complete response	9 (29%)	7 (32%)	2 (22%)
WHO response			
Progressive disease	3 (10%)	2 (9%)	1 (11%)
Stable disease	20 (64%)	14 (64%)	6 (67%)
Partial response	8 (26%)	6 (27%)	2 (22%)
Pathologic necrosis			
< 50% necrosis	7 (23%)	7 (32%)	0 (0%)
50%–99% necrosis	10 (32%)	8 (36%)	5 (56%)
Complete necrosis	14 (45%)	5 (23%)	4 (44%)

EASL = European Association for the Study of the Liver; TARE = transarterial radioembolization; WHO = World Health Organization.