

A BOSTON SCIENTIFIC PUBLICATION

# access

MAY 2012 • ISSUE 1



## **Boston Scientific Takes a Global View of Education**

Helping meet the needs of clinical education and training, country by country.

## A Message From Dave Pierce

### Why Education and Training Matter When Calculating Patient Outcomes and the Total Cost of Care

During a recent trip to China, I visited the Xi Jing Hospital and had the opportunity to see how Boston Scientific support is enabling the education and training of young physicians in endoscopic procedures. Like hospitals in many other countries, Xi Jing is working to further develop physicians' skills and expand the types of procedures that may be offered to patients.



*Dave Pierce with Professor Guo xue gang, Vice Chairman of the China Endoscopy Society, during his visit to the Xi Jing Hospital.*

In India, key opinion-leader physicians are conducting sessions at our Endoscopy Gurukul, school of endoscopy, to advance the skills of physicians in the region by providing education and training in the fields of EGD, LGI, ERCP and EUS. In addition to hands-on training, physicians have the opportunity to meet with the session presenters. At the February event, more than 200 physicians participated in various meet-the-expert sessions.

Endoscopy nurses are the focus of one of our development programs in the United Kingdom (UK) designed to reinforce both clinical as well as technical knowledge. Since 2009 we have completed more than 1,500 training sessions in the UK and the program has received numerous accolades from nurses and hospital administrators.

Education and training are critical components in advancing therapeutic endoscopy and that is why we continue to support these important programs for physicians and their clinical teams around the world. In 2011, Boston Scientific trained over 24,000 healthcare professionals through Boston Scientific-led programs.



*Dave Pierce and Professor Guo observe physicians performing procedures as part of their ERCP training.*

Our programs help ensure appropriate and efficient use of endoscopic devices — critical for patient safety and positive clinical outcomes.

Whether it is through our sponsorship of the Xi Jing Hospital or through our own programs like Endoscopy Gurukul, we are investing in the future of less invasive medicine. Now more than ever, it is critical to consider the impact these value-added services have on successful patient outcomes and the total cost of care.

We will continue to look for new ways to communicate with and educate our customers around the world. Our global Endoscopy online resources — [www.bsci.com/endo-resources](http://www.bsci.com/endo-resources) — is another avenue to provide information. On the site, you will find images for use in presentations, educational videos, and product information; we are adding new content every day.

Also in this issue, you can read about something I am extremely proud of — our “green” initiatives and what we are doing to minimize our impact on the environment.

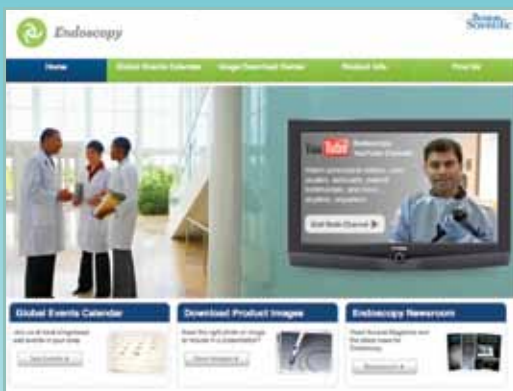A handwritten signature in black ink, appearing to read 'DAP'.

**Dave Pierce**

Senior Vice President, Boston Scientific  
President, Endoscopy Division

## New Online Global Resources

Boston Scientific's Global Endoscopy Resources On-Line provides healthcare professionals with easy access to a host of educational and product-specific information. The site includes both product and clinical images that can be downloaded for presentations; global office and distributor contact information; Access Magazine; a global events calendar; and Boston Scientific news. Recent additions include product catalogs and a video finder to help visitors search videos on the Endoscopy Channel on YouTube®.



Use your smartphone to scan this code to visit [bsci.com/endo-resources](http://bsci.com/endo-resources)

## Inside This Issue

### Articles



2 Making Green Purchasing Decisions Easier



3 Boston Scientific Taps into Experts to Create "Endoscopy Gurukul" School of Endoscopy



4 An interview with David Carr-Locke, MD



17 How Bronchial Thermoplasty Makes a Difference



18 What's New

### Case Studies



5, 14 CRE™ Wireguided Balloon Dilator



6-8 Expect™ Needle for EUS FNA



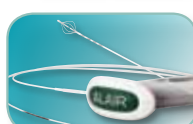9 SpyGlass® Direct Visualization System



10-11, 15 WallFlex® Stents



12-13 Resolution® Clip



16 Bronchial Thermoplasty with the Alair® System



# Making **Green** Purchasing Decisions Easier

**Increasingly, the health care industry is making efforts to deliver the best quality care and be more environmentally friendly.** Hospitals and health systems are beginning to incorporate earth-friendly measures to reduce waste and conserve energy in their operations. But the care continuum does not begin and end within an individual system. Hospitals rely on many companies outside of their own organization to provide products and services that improve the quality of patient care on a daily basis, while making eco-friendly purchasing decisions.

“As one of the leading manufacturers of medical devices, Boston Scientific is committed to providing innovative and quality products to improve patient care while remaining good stewards of the environment. Our products are produced in a way that is environmentally responsible and sustainable,” said David Pierce, President, Boston Scientific Endoscopy.

Between 2007 and 2010 Boston Scientific reduced the annual amount of solid waste generated by all of its plants by 500 tons, decreased greenhouse emissions by 24 percent and increased the amount of recycled waste or reuse from 73 to 83 percent.

“We expect corporations to be better stewards in life cycle management of the medical devices they manufacture. As health care becomes more green, companies that effectively demonstrate environmental responsibility without sacrificing patient care will meet the needs of the market now and in the future.” — **Jaime Wesolowski, President and CEO**  
Methodist Healthcare, San Antonio, Texas.



The company has taken great steps to turn its manufacturing facilities around the globe green by incorporating the Leadership in Energy and Environmental Design (LEED)

standards outlined by the U.S. Green Building Council with the construction of new buildings and the modification of existing facilities. In fact, Boston Scientific currently has five LEED certified facilities spread across North and South America, including the first ever LEED certified manufacturing facility in Costa Rica, located in Coyoil.

The Coyoil location is an ISO14001 facility — meaning that it has a certified Environmental Management System — has identified the most significant environmental aspects for the facility, and is working to improve performance related to these aspects. Overall, Coyoil is 25 percent more efficient than comparable plants thanks to innovative technological and engineering features developed by Boston Scientific. The facility obtains at least 85 percent of all electricity from renewable sources — not greenhouse-gas emitting sources. During 2011, the Coyoil plant also reduced its paper consumption by 50 percent.

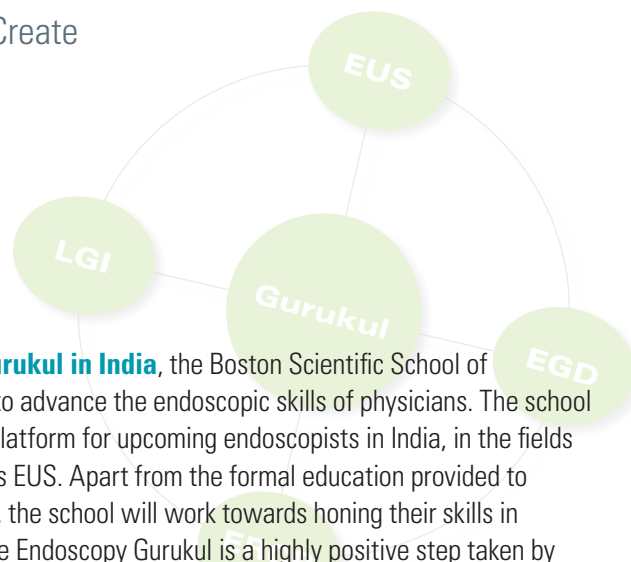
The Coyoil facility is the largest manufacturer of single-use biopsy forceps in use at hospitals around the world and also produces devices used in polypectomy and biliary procedures. Just by changing the packaging of products manufactured at this plant, total waste will be reduced by 47,000 lbs. a year. Using less packaging is a “win win”: less packaging is good for the environment and the customer has less waste to manage which means less spend on waste management.

Gurukul derived from **Sanskrit** words ‘Guru’ meaning teacher or master and ‘kul’ meaning domain, is a form of teaching in India. It is considered a school of traditional education. So Endoscopy Gurukul means a School of Endoscopy with experience from ‘Gurus’ or masters in the field of endoscopy (learning’s of past and future advancements).



Boston Scientific employees at the first Endoscopy Gurukul, School of Endoscopy, session held at the 2011 Society of Gastroenterology National Conference (Mumbai, India).

## Boston Scientific Taps Into Experts to Create “Endoscopy Gurukul” School of Endoscopy



Physicians participate in a session conducted by Dr. Amit Maydeo as part of the Endoscopy Gurukul education and training program.

Launched at the Indian Society of Gastroenterology National Conference in November 2011, the Endoscopy Gurukul brought together more than 150 physicians to watch videos from experts in the field

of endoscopy performing various endoscopic procedures. In addition, physicians had the opportunity to meet with the expert presenters, including two U.S.-based physicians, Dr. Dennis Jensen from the University of California at Los Angeles (UCLA) and VA Medical Center; Dr. Shyam Vardarajulu from the University of Alabama at Birmingham; and from India Dr. Nageshwar Reddy from the Asian Institute of Gastroenterology, Hyderabad.

In February 2012, Boston Scientific brought the Gurukul to the Advances in Hepato-Biliary Pancreatic Endoscopy (AHBPE) National Conference with an extensive program organized by Dr. Nageshwar Reddy. The program was organized in three sessions that included workstations to watch various procedural videos; a hands-on session that used EGD and ERCP models where physicians could learn and practice various techniques using Boston Scientific Endoscopy products; and a SpyGlass® Direct Visualization System demonstration to help physicians understand how this technology can be used in their everyday practice.

Conducting the meet-the-guru (expert) sessions were Dr. Amit Maydeo; Dr. Randhir Sud, Chairman Medanta Institute of Digestive and Hepatobiliary Sciences, New Delhi, India; and Dr. Horst

**Known as Endoscopy Gurukul in India**, the Boston Scientific School of Endoscopy was developed to advance the endoscopic skills of physicians. The school aims to provide a learning platform for upcoming endoscopists in India, in the fields of EGD, LGI, ERCP as well as EUS. Apart from the formal education provided to gastroenterologists in India, the school will work towards honing their skills in therapeutic endoscopy. “The Endoscopy Gurukul is a highly positive step taken by Boston Scientific to enhance endoscopy education in our country,” said Dr. Amit Maydeo, Managing Director of the Institute of Advanced Endoscopy, Mumbai, India.

Neuhaus, Head of the Department of Internal Medicine, Teaching Hospital of the University of Düsseldorf, Germany. More than 200 physicians participated in various meet-the-guru sessions, and more than 80 physicians watched procedural videos each day at the AHBPE Conference.

“Endoscopy Gurukul has evolved to be an extremely useful teaching process for young endoscopists in India. “Philosophy Gurukul” exemplifies the ancient Indian philosophy of the teacher-student-relationship. The one-to-one hands on teaching with models, high-quality teaching videos and other innovative techniques make Endoscopy Gurukul an extremely important teaching experience for endoscopists in India,” said Dr. Nageshwar Reddy.

“Endoscopy Gurukul is an excellent initiative by Boston Scientific for beginners. Meet the Gurus session on ‘Difficult CBD calculus’ by Dr. Amit Maydeo was very informative and an eye opener to common mistakes made during procedures,” said Dr. Yogesh Harwani, Department of Gastroenterology, Nizams Institute of Medical Science, Hyderabad, India.

### EXPANDING THE PROGRAM

Working with key opinion-leader physicians, Boston Scientific plans to make Endoscopy Gurukul a part of other major conferences in India. In addition, plans are underway to make live sessions available via a web portal with class levels geared toward experts as well as beginners.

## Boston Scientific Provided Training to Over 24,000 GI Health Care Providers in 2011

Through a variety of Boston Scientific-led education and training programs, the company works to increase the awareness of potential treatment modalities available to gastroenterology health care providers (HCP) worldwide.

In 2011 Boston Scientific issued more than 18,000 continuing education credits to nurses and trained more than 5,000 physicians. Education and training is made available through local physician peer-to-peer lecture programs, as well as regional, preceptorship and proctorship programs that feature live-case observation.



## **AN INTERVIEW WITH** *David Carr-Locke, MD, Beth Israel Medical Center, New York, New York, on cannulation techniques during endoscopic retrograde cholangiopancreatography (ERCP) and the importance of sphincterotomes to these procedures.*

### **Q** How do you deal with some of the procedural challenges often associated with anatomy during ERCP?

An essential element of cannulation is the need to lift the papilla that one sees endoscopically to overlap the access to the bile duct. That important lifting or shortening of the intramural segment of the bile duct is the key to successful cannulation. Catheters, guidewires, sphincterotomes and other devices that have been produced for cannulation are designed to overcome that part of the bile duct in normal anatomy. When there are anatomical challenges caused by surgical alteration, we often use an end-viewing endoscope. Therefore, normal accessories do not work very well so you may want those accessories to do different things like rotate or work upside down.

### **Q** When do you use sphincterotomes in your practice and how often do you use them?

The place of sphincterotomes in ERCP has changed considerably over the last 20 years; initially they were used purely for sphincterotomy. Today, they have become essential tools for cannulation as well as sphincterotomy. We also occasionally use the deflection capabilities of a sphincterotome within the bile duct to direct guidewires.

### **Q** What is important to you in a sphincterotome? Why is sphincterotome performance important in your procedure?

A sphincterotome has to orientate correctly; it has to be strong enough in the axial direction so that it has adequate pushability; it has to be atraumatic at the tip; and it has to bow reliably for sphincterotomy. When a sphincterotome orientates correctly, it facilitates an efficient procedure and makes the procedure much more likely to be successful. This will benefit the patient.

### **Q** Would a sphincterotome that rotated be a benefit? How could rotation make a procedure more efficient or successful?

In the past sphincterotomes were static, they could not be rotated unless we made them rotate ourselves. But for a sphincterotome to have good one-to-one rotation ability may be an advantage in certain situations, for biliary cannulation, sphincterotomy, and for selective intrahepatic duct access. The ability to rotate a device is an advantage. Having a reliable sphincterotome is critical to a successful procedure and that helps patient care by reducing the risk of complications.

### **Q** When a company is investing in both improving their legacy or core devices as well as developing new devices, what does this mean to you and is it something that matters to you?

The interaction between clinicians and industry is essential for the development of new devices and also the improvement of existing devices. The Ultratome™ XL Sphincterotome is a good example of that. Over a period of time many of us have contributed ideas and have tested new versions of the sphincterotome for cannulation and for sphincterotomy to help improve its ability to do all of the things that we want it to do. This sort of interaction that takes place between the engineers on the industry side and us as clinicians, the end user, helps to make that happen. If that interaction did not occur, either certain devices would never get developed or it would take a lot longer. It is a partnership that allows optimal products to be developed that meet clinicians' needs.

## Quality Initiative Leads to Improvements

In 2011 Boston Scientific completed a **Quality initiative** focused on improving the performance its **RX line of sphincterotomes** (Hydratome®, Jagtome®, and Dreamtome® Sphincterotomes). With customer input and a focus on continuous improvement, several significant projects were implemented that resulted in changes to the manufacturing processes and the automation of specific tasks for improved precision and consistency.

Sphincterotome orientation has been improved to provide enhanced and more consistent performance; tip rotation now provides more precise rotational control; and bowing strength has been increased. \* Today, the complete line of Boston Scientific sphincterotomes offer improved performance. Boston Scientific Quality Manager, Tony Foldenauer, who worked on the improvement initiative since its start, said, *"It got us thinking about Quality in a new way and with an added focus on manufacturing processes. By listening to the customer and applying a Quality perspective you can make a better product and ultimately help impact patient care."*

\*Test data applies to the Autotome™ RX family of sphincterotomes. Data on file.

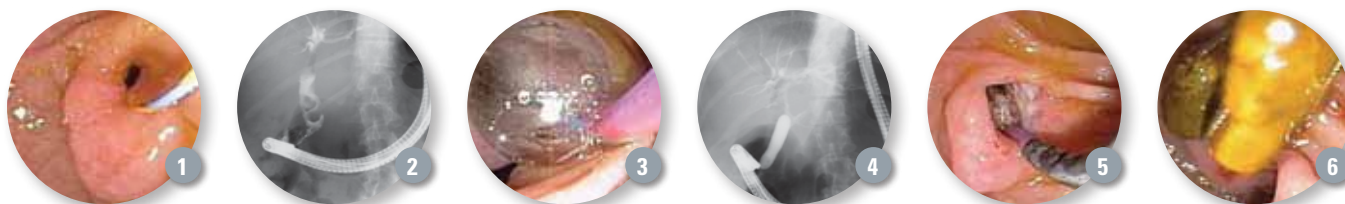


# Dilation Assisted Stone Extraction for Removal of Large Bile Duct Stones Using the CRE Wireguided Balloon



CASE PRESENTED BY:  
**STUART SHERMAN, MD**

Professor of Medicine and Radiology  
Indiana University Medical Center  
Indianapolis, Indiana, USA



## PATIENT HISTORY

A 53-year-old woman underwent cholecystectomy three years ago for symptomatic cholelithiasis. During the past year she has had intermittent episodes of right upper quadrant pain. She presented to her local hospital with a severe episode of right upper quadrant pain radiating to the back with associated jaundice. Laboratory tests revealed a total bilirubin of 7.3, alkaline phosphatase 420 (normal <125); AST/ALT 125/142 (normal <41/45). Abdominal ultrasound showed a dilated biliary tree and suggested a stone in the distal bile duct. MRCP showed two stones in the common bile duct with a dilated biliary tree. An ERCP was done by the local gastroenterologist. The cholangiogram showed two bile duct stones. A sphincterotomy was done but the stones could not be removed using a stone retrieval balloon and a basket. A 10-Fr stent was placed. The patient was referred to our institution for reattempt at stone removal three weeks later.

## PROCEDURE

Screening endoscopic views of the papilla showed the biliary stent in place. Following stent removal, a patent sphincterotomy was identified (Figure 1). The cholangiogram showed a dilated biliary tree with two stones measuring a maximum of 14 mm. The terminal 15 mm of bile duct was narrowed (Figure 2), preventing stone removal with a stone retrieval balloon or basket.

Therefore, a decision was made to proceed with Dilation Assisted Stone Extraction (DASE) using a wireguided hydrostatic balloon. A CRE™ Wireguided Balloon was advanced under endoscopic and fluoroscopic guidance

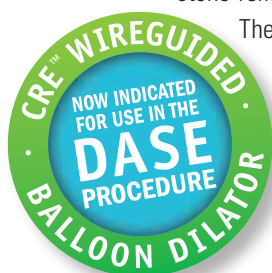
and positioned across the papillary orifice. Incremental dilation was performed using a 12-13.5-15mm CRE Balloon. The balloon was maintained inflated until the waistline disappeared (Figures 3 and 4). Following deflation of the balloon, the biliary orifice was now gaping (Figure 5). Following dilation, extraction of the stones was easily performed using a standard stone retrieval basket (Figure 6). A final cholangiogram showed no residual stones and no evidence of perforation.

## POST PROCEDURE

The patient was observed in our outpatient recovery unit for four hours. She had no post-procedure pain and was discharged. Telephone follow-up was done seven days later. The patient was totally asymptomatic.

## DISCUSSION

There are a variety of therapy options that can be considered for the management of large bile duct stones that cannot be removed with standard stone retrieval balloons and baskets following endoscopic sphincterotomy. Traditionally, mechanical lithotripsy has been the most widely utilized technique to manage these stones. However, this technique requires stone capture. Thus, impacted stones and stones located in the intrahepatic ducts may be impossible to remove using mechanical lithotripsy. Moreover, very hard stones may be resistant to stone fragmentation. DASE has clearly altered our approach to the management of large bile duct stones and is being adopted by many endoscopic centers throughout the world.



## The Pancreatic Metastasis of Clear Renal Cell Carcinoma Confirmed by EUS-FNA



CASE PRESENTED BY:

**JOSÉ CELSO ARDENGH, MD, PhD**

Professor of Ribeirão Preto Medical School  
São Paulo University  
São Paulo, BRAZIL

### PATIENT HISTORY

An asymptomatic man, 58-year-old was treated for clear renal cell cancer six years ago. Control CT showed the hyper-vascularized solid nodule (2.1x1.9cm) in the head of the pancreas. Endoscopic Ultrasound-Fine Needle Aspiration (EUS-FNA) was indicated for diagnosis.

### PROCEDURE

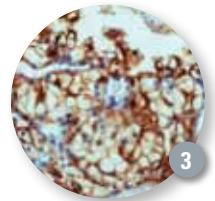
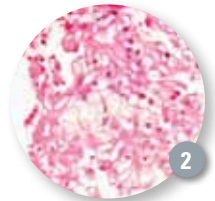
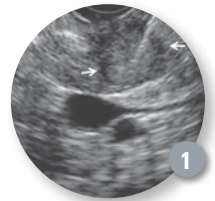
The EUS showed a hypoechoic and homogeneous nodule within precise limits, located in the uncinate process. The lesion measured 2.2x1.8cm in length. The Doppler signal was negative. The lesion was distant from the main pancreatic duct and the common bile duct. The FNA was performed with the Expect™ Needle (22G) with a large amount of material that was sent to microhistology (Figure 1).

### PATIENT OUTCOME

The diagnosis was clear renal cell carcinoma [HE (Figure 2)] with immunohistochemistry (Figure 3)]. The patient was submitted to duodenopancreatectomy. The follow-up after six months showed good results of the treatment.

### DISCUSSION

Performing trans-duodenal EUS-FNA in tumors in the uncinate process can be technically challenging. In this case, there was no technical difficulty either with trans-duodenal needle deployment or with the Expect Needle. It appears that Cobalt Chromium, a feature in the construction of the Expect Needle, may contribute to its better maneuverability and low-needle memory.



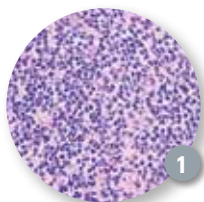## Histological Sampling Using the Expect 19ga Flex Needle



CASE PRESENTED BY:

**ICHIRO YASUDA, MD, PhD**

Associate Professor  
First Department of Internal Medicine  
Gifu University  
Gifu, JAPAN



### PATIENT HISTORY

A 60-year-old man was referred to us because his abdominal CT findings showed several swollen mesenteric lymph nodes. He had been diagnosed with follicular lymphoma

five years earlier, and complete remission had been achieved by chemotherapy. Lymphoma recurrence was suspected, and EUS-FNA was performed for confirming diagnosis. We used a newly launched needle — the Expect™ 19ga Flex Needle — and transgastric needle puncture was performed three times. Sufficient material was successfully obtained, and the patient was diagnosed with follicular lymphoma recurrence on the basis of histopathological findings (Figure 1).

This needle has several advantages over previous 19-gauge needles. The needle shaft is more flexible than previous 19-gauge needles. Therefore, it is much easier to angulate the needle tip, which makes

puncture easier. Furthermore, the needle tip is clearly visible on EUS images, and even the needle wall is visible as two hyper-echoic strands (Figure 2). Thus, the Expect 19ga Flex Needle is useful for sampling.

### DISCUSSION

Histological assessment is often essential, and diagnosing certain conditions, e.g., lymphoma, solely on the basis of cytological assessment is difficult. Moreover, histopathological assessment and sub-classification are essential for choosing treatment strategies and predicting prognosis.

Therefore, in suspected lymphoma cases, we often use 19-gauge needles to obtain material for histological assessment. We previously found that lymphoma sub-classification is possible in patients when EUS-FNA samples are obtained using a 19-gauge needle (Endoscopy 2006, AJG 2012).



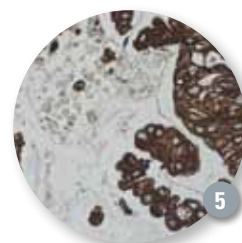
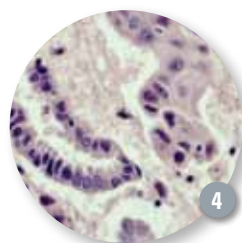
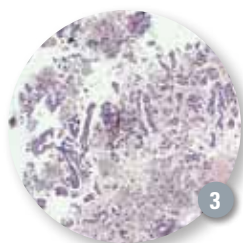
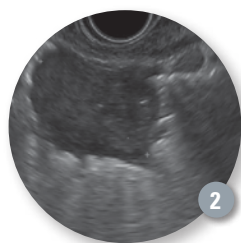
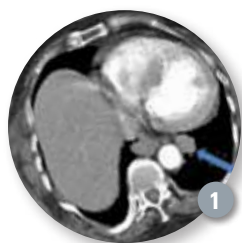# Expect 19ga Flex Needle for Diagnosis of a Lung Tumor



CASE PRESENTED BY:

**PIERRE H. DEPREZ, MD**

Head of Hepatogastroenterology Department  
Cliniques Universitaires Saint-Luc  
Bruxelles, BELGIUM



## PATIENT HISTORY

This is an 84-year-old patient with abdominal pain and incidental finding of a lung tumor close to the posterior mediastinum (size 25x15, **Figure 1**). A positron emission tomography-computed tomography (PET-CT) was highly positive and suggestive of malignancy. Endobronchial ultrasound (EBUS) and fibroscopy plus lavage revealed benign cytology but the nodule could not be accessed.

## PROCEDURE

The lesion was easily seen through the esophageal wall (**Figure 2**) and a puncture was performed with the new Expect™ 19ga Flex Needle to obtain both cytology and histology specimens to provide immunochemistry evaluation. The sharpness and flexibility of the Expect Needle allowed smooth access to the tumor. The actuation and precision of the puncture allowed us to provide adequate sampling in a single pass. The technique used is our usual technique: the stylet is slightly retracted before puncture and then pushed when the tip of the needle is in the middle of the lesion (this pushes out a bubble of air confirming the tip position), then fully removed and suction applied with the 20cc syringe provided with the needle, until blood can be seen in the syringe. The full specimen is rinsed in a vial containing a fixative, and the monolayer technique is used in the following way: after cytocentrifugation a maximum volume of 4ml of the vial content is used to prepare one slide, and the remaining specimen is fixed in 10% formalin and embedded in paraffin.

The procedure was perfectly tolerated without any pain or complications. Pathological analysis confirmed a malignant adenocarcinoma. **Figures (3-5)** show how adequate the specimen can be with histological needles and the monolayer technique. The lesion was compatible with lung cancer expressing CK7, TTF-1. There was no p63 expression and EGFR were present in 80% of cells.

## CONCLUSION

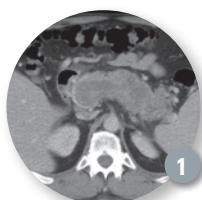
The case report nicely illustrates the precision and efficacy of the Expect 19ga Flex Needle, allowing safe and precise puncture in risky areas (mediastinum and lung) with excellent histology specimens.



## Acinar Cell Carcinoma Diagnosis With Expect 19ga Flex Needle

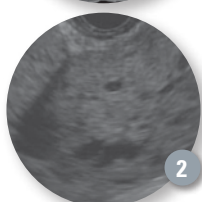


CASE PRESENTED BY:  
**PETER DRAGANOV, MD**  
 Professor of Medicine  
 Director of Endoscopy  
 University of Florida  
 Gainesville, Florida, USA



### PATIENT HISTORY

A 58-year-old male presented with massive upper gastrointestinal bleeding to an outlying institution. A computed tomography (CT) scan of the abdomen showed a large pancreatic mass, occupying most of the pancreas (**Figure 1**). Endoscopic Ultrasound (EUS) with Fine Needle Aspiration (FNA) using a 22ga needle was done. Sample cellularity was deemed adequate and a few acinar cells were seen but a final diagnosis could not be established based on the provided specimen because there were not enough cells present to perform special stains.



### PROCEDURE

The patient was transferred to our institution for further evaluation. In order to obtain a better sample from the pancreatic mass we performed EUS-FNA with the Expect™ 19ga Flex Needle. At EUS a hypochoic, heterogeneous pancreatic mass was identified (**Figure 2**). One pass was made with the Expect 19ga Flex Needle. 10ml of

suction was applied and the needle was moved back and forth for 30 seconds. A touch prep slide was prepared for immediate cytologic evaluation and the remainder of the specimen was collected in Cytolite for cell block. Cytologic evaluation at the bed side showed abundant cellularity; therefore, no further sampling attempts were undertaken.

Final evaluation revealed multiple acinar-like cells. Adequate cellularity was seen on the cell block and sufficient material was present to perform chromogranin, synaptophysin, and chymotrypsin stains — all of which were negative. These cytologic findings were interpreted as consistent with acinar-cell carcinoma, which is a very rare tumor of the pancreas. The patient underwent subtotal pancreatectomy with splenectomy, tolerated the surgery well and was discharged home.

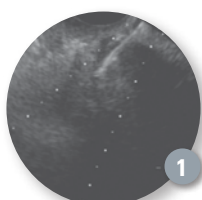
### CONCLUSION

In this case of pancreatic EUS-FNA, adequate specimen to perform multiple special stains was obtained using a single pass with the Expect 19ga Flex Needle. As a result, we were able to establish a definitive diagnosis of a very rare pancreatic neoplasm and recommend specific therapy.

## EUS-Guided Fine Needle Aspiration in a Patient with Pancreatic Carcinoma by Using an Expect 19ga Flex Needle



CASE PRESENTED BY:  
**ZHENDONG JIN, MD**  
**DONG WANG, MD**  
**ZHAOSHEN LI, MD**  
 Department of Gastroenterology  
 Changhai Hospital  
 Second Military Medical University  
 Shanghai, CHINA



### PATIENT HISTORY

A 43-year-old female patient presented with abdominal pain and suspected pancreatic cancer because of a pancreatic body mass and narrowing of the main pancreatic duct (MPD) on CT imaging.

### PROCEDURE

Standard Endoscopic Ultrasound (EUS) was performed by using a curvilinear echoendoscope. The EUS showed a 2.3cm lesion, with a hypochoic, inhomogeneous echoic structure and distinct margins in the body of the pancreas. The procedure was performed with the new Expect™ EUS Aspiration 19ga Flex Needle. The needle tip punctured the stomach wall and entered the lesion under EUS guidance. The puncture process was repeated three times, samples

were prepared by the nursing staff trained by cytology technicians and the contents of the needle were air flushed into a tube with a preservative cell solution.

### CONCLUSION

An adequate cytological tissue sample was obtained. Cytological examinations were performed by a cytopathologist. The EUS-FNA cytological specimens and tissues were interpreted as adenocarcinoma.

The sharpness of the new Expect Needle was particularly helpful, allowing for multiple punctures even in difficult scope positions and in hard strictures. The needle was particularly echogenic, even in distant and small lesions (**Figure 1**).

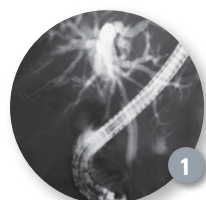## From Uncertainty to Certainty: How the SpyGlass System Cholangioscopy Established the Diagnosis of a Biliary Stricture



CASE PRESENTED BY:

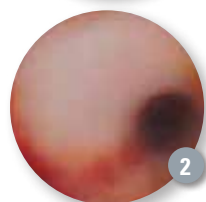**GURPAL SANDHA, MBBS, FRCP**

Associate Professor of Medicine  
Director of Endoscopy  
University of Alberta Hospital,  
Edmonton, Alberta, CANADA



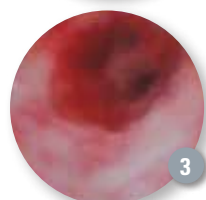
### PATIENT HISTORY

A 68-year-old female presented to her local hospital with painless jaundice. An ERCP documented a proximal biliary stricture (**Figure 1**). Brushings from the stricture were inconclusive. A metal stent was inserted without a clear diagnosis and she was referred to our institution for a hepatobiliary surgery consultation.



### PROCEDURE

The surgical consultation resulted in a referral for endoscopic ultrasound, which had some limitation considering the presence of the metal stent. We, therefore, decided to perform an ERCP and cholangioscopy using the SpyGlass® single-operator Direct Visualization System. The metal stent was removed and cholangioscopy revealed normal bile ducts (**Figure 2**) above the stricture and an apple-core lesion at the stricture site (**Figure 3**).



Biopsies using SpyBite® Biopsy Forceps confirmed our suspicion of adenocarcinoma.

### DISCUSSION

The SpyGlass System was the ideal diagnostic intervention in this case. Not only did it provide a direct visual of the malignant exophytic lesion but also enabled tissue diagnosis with forceps biopsies. Our patient underwent successful surgery and had negative resection margins. Failure of diagnosis in such challenging biliary cases can lead to a delay in treatment or unnecessary surgical intervention. The SpyGlass System has added another dimension in the diagnostic work up of biliary disease. The SpyGlass System has found its place in therapeutic ERCP and we will continue to see its clinical utility expand in the years to come.

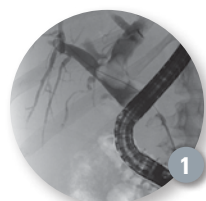
## Combination Therapy for Large Stone Extraction Using the SpyGlass Direct Visualization System



CASE PRESENTED BY:

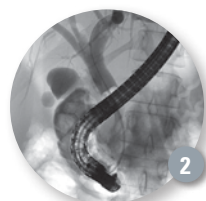
**RICHARD STURGESS, FRCP**

Clinical Director of Digestive Disease  
Emergency and General Surgery  
University Hospital Aintree  
Liverpool, UK



### PATIENT HISTORY

The patient, a 34-year-old female, presented with obstructive jaundice and cholangitis two months previously at another hospital. An ERCP demonstrated large stones filling the common duct with a 2.5cm stone impacted at the hilum.



### PROCEDURE

An ERCP was undertaken under general anaesthesia, using the SpyGlass® System single operator cholangioscopy (SOC) and Electro Hydraulic Lithotripsy (EHL). Initial

cholangiography demonstrated the lower common bile duct (CBD) to be jammed with stones with a larger stone at the hilum (**Figure 1**). Some of the smaller, very distal stones were removed by balloon extraction through the previous sphincterotomy. After some "room" had been created in the distal CBD, a large volume balloon dilatation

of the sphincter was carried out to 16mm, using a 15-18mm, CRE™ Wireguided Balloon. Following this SOC with EHL was used to progressively break up the larger mid-CBD stones which were then extracted using a Trapezoid® Wireguided Retrieval Basket which also allowed mechanical lithotripsy to aid their extraction. Clearance of the lower and mid CBD allowed access to the larger stone at the hilum which was broken up with more SOC and EHL. The duct was then cleared completely with balloon trawling using a 15mm Extractor™ Pro Retrieval Balloon Catheter (**Figure 2**). In this last cholangiogram the stone fragments can be seen lying within contrast in the duodenum.

### CONCLUSION

This study illustrates the use of cholangioscopy together with electro-hydraulic lithotripsy to treat complex choledocholithiasis. It emphasizes the fact that in most cases of complex bile duct stones multiple techniques need to be used within one procedure to obtain successful duct clearance.



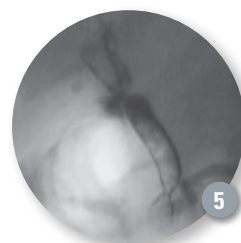
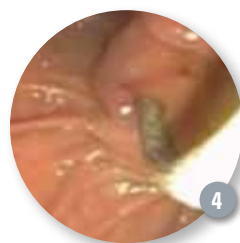
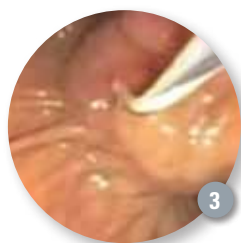
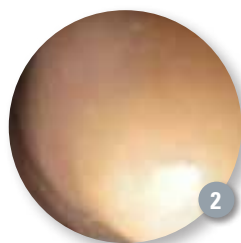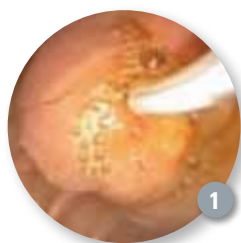## Using WallFlex Biliary RX Stents to Manage Post Liver Transplant Anastomotic Stricture



CASE PRESENTED BY:

**ANGELO FERRARI, MD**

Hospital Albert Einstein  
São Paulo, SP, BRAZIL



### PATIENT HISTORY

A 65-year-old man was admitted because of jaundice for the last 30 days with some itching in the last week. His total bilirubin was 15.5mg/dl with 12mg/dl of bilirubin direct. Alkaline phosphatase and gamma glutamyl transpeptidase were 2-3 times above the normal limit. Platelets were low (53,000/mm<sup>3</sup>). An abdominal ultrasound showed dilated intrahepatic ducts up to the hepatic hilum.

### PROCEDURE

An endoscopic retrograde cholangiopancreatography (ERCP) was performed for biliary drainage. During the procedure there was a tight stricture in an anastomotic area that could not be bypassed by a guidewire (**Figures 1 and 2**). Percutaneous drainage was considered, but we crossed the stricture using a needleknife under radiologic control (**Figure 3**), as the intrahepatic biliary tree was very dilated. After passing cutting current through the needleknife we were able to reach the dilated intrahepatic biliary tree and a Jagwire® 0.035" Guidewire was passed to ensure access. A fully covered 80mm x 10mm WallFlex® Biliary RX Stent was deployed without sphincterotomy (**Figure 4**) or dilatation because of the low platelet count. Deployment was successful with immediate drainage of bile and contrast. Due to the very fibrotic nature of the stricture a waist was clearly noticed after stent deployment (**Figure 5**). The patient recovered uneventfully from the procedure.

### PATIENT OUTCOME

Patient was discharged one day after the procedure and his bilirubin levels were down to 5mg/dl. He is now two months after the index procedure without jaundice or itching and normal liver function tests. A new ERCP will be performed in 5-6 months after the index procedure to remove the WallFlex Biliary RX Stent and evaluate for the need of any further treatment.

### DISCUSSION

Biliary complications occur in up to 40% of patients after liver transplantation (orthotopic liver transplant) and are currently managed with multiple plastic stents. Self-expanding metal stents have recently shown encouraging results. There is no study comparing both treatment modalities. Our group experience with partially covered metal stents in 10 patients also showed encouraging results. There was immediate stricture resolution in all patients, with one recurrence after a median follow up of 180 days. We are now performing a randomized controlled trial of multiple plastic stents versus fully covered metallic stents in anastomotic post liver transplantation. Because there is no need for sphincterotomy or dilatation or repeated procedures, even with a higher initial cost in the metal stent groups we think that full treatment cost may be lower than in the plastic group.

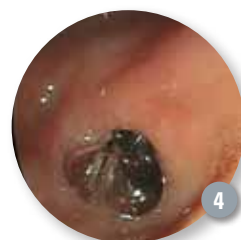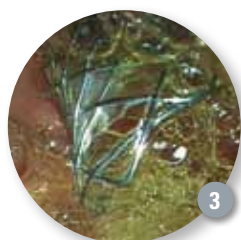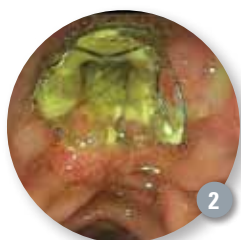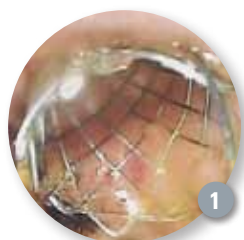**NOTE:** Use of the WallFlex Biliary RX Fully Covered Stent for the treatment of benign strictures or stenoses has not been cleared for use in the United States.

**WARNING:** The safety and effectiveness of the WallFlex Biliary Stent for use in the vascular system has not been established.

# Management of Sump Syndrome Using WallFlex RX Fully Covered Biliary Stents



CASE PRESENTED BY:  
**FRANCISCO GALLEGO ROJO, MD**  
Hospital de poniente, Elejido (Almeria)  
Elejido (Almeria), SPAIN



## PATIENT HISTORY

A 77-year-old woman with a past medical history of choledochoduodenostomy (**Figure 1**) and recurrent cholangitis secondary to sump syndrome was admitted to our hospital with fever, jaundice and abdominal pain. After undergoing empiric antibiotic therapy, the patient was scheduled for an ERCP.

## PROCEDURE


After cannulation of the papilla with a 0.035" Hydra Jagwire® Guidewire, a cholangiogram revealed a short stenosis of the lower common bile duct, enlarged intra- and extrahepatic ducts and filling defects. A sphincterotomy was performed. Several stones and food debris were removed using an Extractor™ Balloon Catheter. Once the bile duct was cleared, a 10x60mm WallFlex® Biliary RX Fully Covered Stent (**Figure 2**) was successfully deployed below the confluence of intrahepatic ducts.

## POST PROCEDURE

The patient was asymptomatic during a 12-month follow-up period and a WallFlex Fully Covered Stent replacement was placed (**Figures 3 and 4**).

## DISCUSSION

Sump syndrome is an uncommon complication (0-9.6%) after side-to-side choledochoduodenostomy. When debris or stones accumulate in the sump, recurrent cholangitis may develop. Endoscopic sphincterotomy is regarded as the treatment choice for sump syndrome, but restenosis of the sphincterotomy was observed in 19% of patients and was treated successfully and safely with a new papillotomy. The placement of a fully covered metal stent achieves sealing of the anastomosis and dilates the stricture.



**NOTE:** Use of the WallFlex Biliary RX Fully Covered Stent for the treatment of benign strictures or stenoses has not been cleared for use in the United States.

**WARNING:** The safety and effectiveness of the WallFlex Biliary Stent for use in the vascular system has not been established.

# Endoscopic Hemostasis of Sigmoid TIC With Pulsatile Non-Bleeding Visible Vessel



CASE PRESENTED BY:

**DENNIS M. JENSEN, MD, CURE DDRC**

UCLA and VA Medical Centers, and David Geffen School of Medicine at UCLA Los Angeles, California, USA

## PATIENT HISTORY

A 73-year-old female with polymyositis (on steroids), diabetes mellitus, obesity, and arthritis was admitted by her rheumatologist with painless hematochezia. Her hemoglobin (Hgb) fell from 13.5 to 10 with IV fluids and she had normal coagulation tests. There was no hypotension, melena or abdominal pain.

A nasogastric (NG) tube was placed and removed after bile was suctioned. A private GI saw the patient and ordered a colon prep of 4L of Golytely. Later that afternoon, he performed a colonoscopy which showed clots, blood and fluid throughout the colon and rectum, extensive diverticulosis without stigmata and large internal hemorrhoids.

That night, the hematochezia recurred and the Hgb dropped below 9.0. The GI hemostasis team was called to see the patient as a second opinion. The patient received 2 units of packed red blood cells (RBCs). She had an NG tube placed and received 7L of Golytely until the rectal effluent was clear of all clots and blood. An urgent colonoscopy was performed.

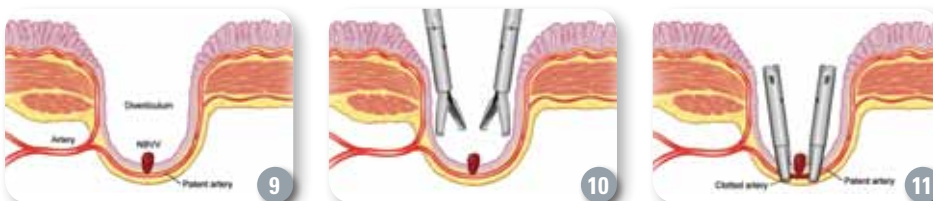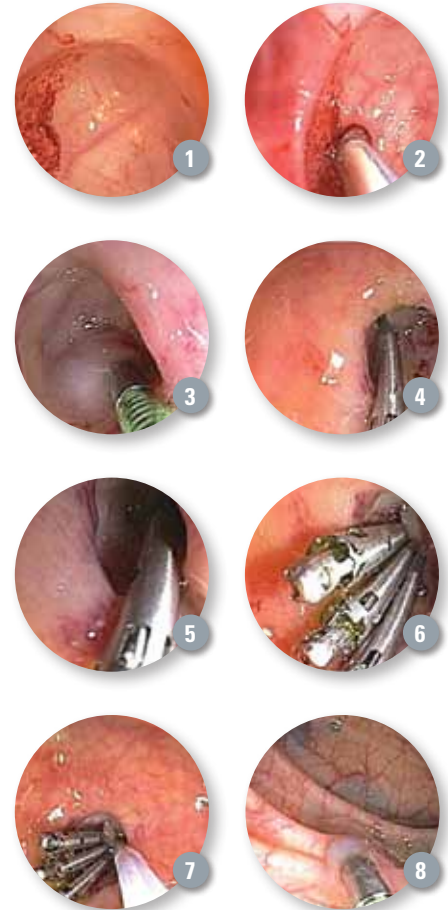
## PROCEDURE

In about 50 percent of definitive diverticular hemorrhage cases (i.e. when major stigmata are found on urgent colonoscopy), the stigma is in the base of the diverticulum. In this case, a pulsative non-bleeding visible vessel (NBVV) was found (**Figure 1**) along the course of the artery in the base of the diverticulum. It was interrogated with a Doppler ultrasound probe (DUP) (**Figure 2**) and arterial blood flow just underneath the NBVV and adjacent to it (for 3-4 mm on each side along the artery) was detected. The colonoscope shaft and the diverticulum with the NBVV were then rotated 90 degrees counterclockwise so that the artery in the base of the diverticulum was in the vertical position (oriented 12 o'clock to 6 o'clock) to facilitate treatment with accessories that come out in the 5 o'clock position through the Olympus colonoscope suction channel. Then, two 1 cc epinephrine injections (1:20,000 in saline) were used around the NBVV in the base of the diverticulum and 3-4 mm along the artery on either side of the NBVV (**Figure 3**). These formed a bleb which raised up the base (**Figures 2 and 3**). Then the first hemoclip (Resolution® Clip) was placed on the NBVV (**Figure 4**). The vasoconstrictive effects (purplish) are noted (**Figures 3 and 4**).

Subsequently two other hemoclips (HC) were placed in the base of the diverticulum, one on either side of the NBVV along the artery (**Figures 5 and 6**). Upon repeat DUP, no blood flow was detected (**Figure 7**). India ink (Spot) tattooing was used in three adjacent areas around the diverticulum to mark it, in case of rebleeding or the need for surgical resection (**Figure 8**).

## PATIENT OUTCOME

The patient resumed a full liquid diet and her regular medications. She started her regular diet and activities within 24 hours and daily fiber. She has had no bleeding or complications and has been followed for three years, without recurrence of diverticular bleeding.



## Q & A with Dr. Jensen

### Why did you use two modalities?

**A:** Combination treatment with epinephrine injection (1:20,000) [x 2, injections of 1cc each] and hemoclips (HC) was used. The epi injection prevents bleeding induced from the HC touching the NBVV, which was pulsatile and had underlying arterial flow documented.

### Why was it important to clip?

**A:** Injection and HC [or multipolar electrocoagulation (MPEC)] are necessary for coaptive coagulation of the underlying artery and prevention of short and long term diverticular rebleeding. Epi alone does not cause definitive hemostasis of definitive diverticular hemorrhage (**Figure 5**).



# Hemoclipping of a Mallory-Weiss Tear



CASE PRESENTED BY:

**MATHEW SERICATI, MD**

Idaho Gastroenterology Associates  
and St. Luke's Regional Medical Center  
Boise, Idaho, USA

## PATIENT HISTORY

A 67-year-old man presented to the emergency room via ambulance with melanic stools and hematemesis. He was on a flight from Seattle to Denver when his flight was diverted to Boise after multiple bouts of hematemesis and a syncopal episode. Three days prior to the flight he reported melanic stools but was otherwise doing well. He became light-headed and was brought to his gate by wheelchair, but progressed to multiple episodes of hematemesis and a syncopal episode in the air. Past medical history was significant for osteoarthritis and gout for which he was taking indocin and allopurinol. Upon presentation to the emergency room, his blood pressure was 80/40 with a pulse in the 120s. His hemoglobin was 9.9, platelets 243, and INR was 1.0. After his blood pressure was stabilized with IVFs and blood transfusions, the patient underwent urgent EGD.

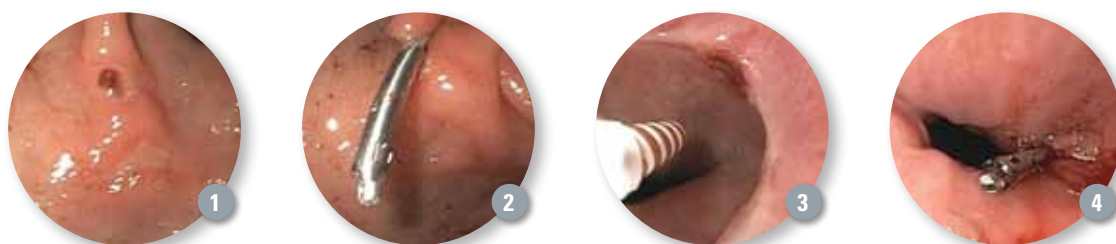
## PROCEDURE

Multiple superficial ulcers were noted throughout the stomach. A 1cm ulcer with a visible vessel was present in

the antrum of the stomach. The visible vessel (**Figure 1**) measured approximately 1.5mm and had evidence of recent bleeding. An injection of 3cc of 1:10,000 epinephrine into the visible vessel was performed. A Resolution® Clip was placed on the visible vessel with excellent hemostasis (**Figure 2**). A 1cm Mallory-Weiss Tear was also noted at the GE junction with evidence of recent bleeding (felt to be the secondary bleeding site from wrenching). This was treated with bipolar electrocoagulation from a 7Fr Gold Probe (**Figure 3**). After use of the Gold Probe, a Resolution Clip was placed to approximate the margins and provide good hemostasis (**Figure 4**).

## POST PROCEDURE

The patient was admitted to the intensive care unit overnight and placed on a PPI drip. He clinically remained stable, had no further evidence of GI bleeding and did not require additional blood transfusions. He was discharged shortly after. Since being discharged from the hospital, he has not had any further bleeding and has not yet undergone his eight week follow up EGD.



### How did you determine where to place the first clip and the last clip?

**A:** The first HC was placed on the stigmata – the NBVV. Because of a positive (+) DUP (for blood flow) underneath and on either side of the NBVV at about 3-4 mm, 2 additional HC were placed (**Figure 6**).

### Were the clips successful and how did you measure success?

**A:** 1.) NBVV clipped; 2.) Artery in base of HC with + DUP (and superficial blood flow) clipped; 3.) DUP – (negative) after treatment (**Figure 7**); 4.) No rebleeding either within 30 days, or in this case for three years, without recurrence of diverticular bleeding.

### Why do you prefer hemoclipping in the base of a diverticulum for a stigmata rather than using thermal coagulation which is faster?

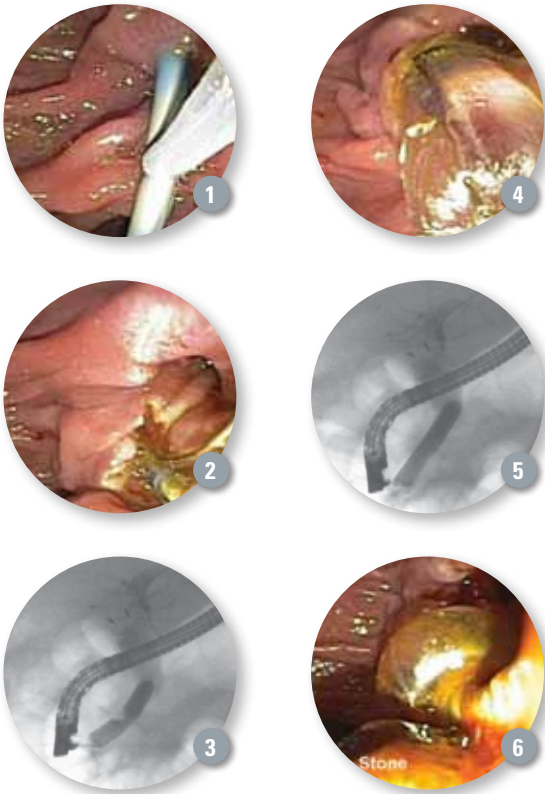
**A:** This diagram of a colon diverticulum shows the penetrating vessels in the anatomy of the diverticulum including the base with a NBVV (**Figure 9**). The base has a thin mucosa, sub-mucosa with an artery and the serosa but no muscle there. The potential risks of thermal cautery are transmural injury, post-coagulation syndrome, and perforation often delayed. However, epi and clipping have not been associated with such injury. Hemoclipping is an important advance as approximately half of the stigmata of diverticular hemorrhage are

found at the base of the diverticulum and can now be safely treated (**Figures 10 and 11**). The other half are found at the neck of the diverticulum and it is safe to use either thermal coagulation or hemoclipping for those.

## Dilation Assisted Stone Extraction — Gaining Popularity for Removal of Common Bile Duct Stones



CASE PRESENTED BY:  
**GURPAL SANDHA, MBBS, FRCP**  
 Associate Professor of Medicine  
 Director of Endoscopy  
 University of Alberta Hospital  
 Edmonton, Alberta, CANADA



### PATIENT HISTORY

A 71-year-old female presented to our hospital with a two-day history of biliary colic. She previously underwent a cholecystectomy many years ago. Her liver enzymes were elevated upon initial presentation but there was a downward trend seen ten hours later. An endoscopic ultrasound was performed which revealed a 1.3cm stone in the bile duct. Because of concurrent treatment with clopidogrel, a sphincterotomy could not be performed so an Advanix® Biliary 7Fr plastic Stent was inserted and she was brought back a week later for ERCP and sphincterotomy with stone extraction.


### PROCEDURE

At ERCP, the stent was initially removed (**Figure 1**). A juxta-ampullary diverticulum was seen so care was taken not to perform a large sphincterotomy (**Figure 2**). Considering the size of the stone and the limitation in sphincterotomy size, we decided to proceed with a balloon dilation of the sphincter. This was performed using a CRE™ Balloon Dilator, the size of which was determined by the caliber of the bile duct and size of the stone. A waist in the balloon at the site of the sphincter was noticed (**Figure 3**). Dilation was performed to 13.5mm (**Figure 4**) when the waist was seen to completely efface (**Figure 5**). An Extractor™ Retrieval Balloon Catheter was then introduced into the bile duct and with a single sweep the stone was extracted (**Figures 6**).

We used Dilation Assisted Stone Extraction (DASE) in this case as we felt that this particular stone may not be easily removable considering its size and the limited sphincterotomy. Our patient tolerated the procedure well and there were no complications.

### DISCUSSION

Dilation Assisted Stone Extraction is a modality that can be employed to remove particularly large stones especially when there may be a limitation in the size of the sphincterotomy. In our practice we always perform a sphincterotomy prior to dilation and the CRE Balloon size should be customized to the calibre of the bile duct and the size of the stone. In order to reduce the risk of complications, our practice is to observe obliteration of the waist fluoroscopically as an end point for optimal balloon dilation of the sphincter.



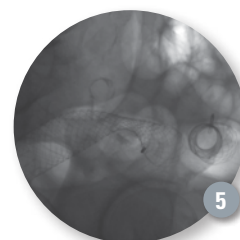
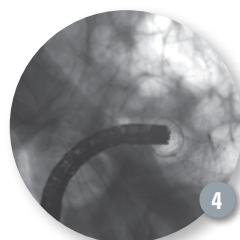
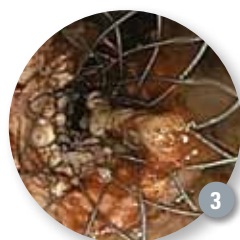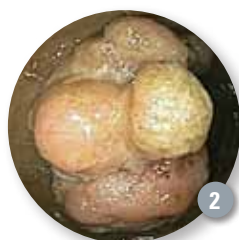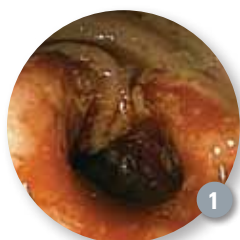# Placement of Dual WallFlex Colonic Stents for Obstructing Synchronous Colorectal Cancer



CASE PRESENTED BY:

**N. JEWEL SAMADDER, MD, MSc, FRCP**

Assistant Professor of Medicine  
Division of Gastroenterology, University of Utah  
GI Cancers Program, Huntsman Cancer Institute  
Salt Lake City, Utah, USA



## PATIENT HISTORY AND CASE ASSESSMENT

A 65-year-old male presented to his local primary care physician with anemia and fatigue. Over the next two months he developed abdominal cramping, rectal bleeding and diarrhea. Prior to this, his bowel movements were well formed with regular frequency. A CT scan of the abdomen and pelvis showed thickening in the sigmoid and transverse colon and two large masses in the liver, concerning for synchronous colorectal cancer with hepatic metastasis. There was concern for colonic obstruction leading to overflow diarrhea. Surgical consultation recommended neoadjuvant chemotherapy and restaging prior to consideration of surgical resection. It was decided to proceed with a colonoscopy to obtain tissue to confirm a diagnosis of colorectal adenocarcinoma and stent placement to relieve obstruction.

## PROCEDURE

A frond like, villous, fungating, infiltrative, nearly obstructing large mass was found in the recto-sigmoid colon. The mass was circumferential and measured 8cm in length (**Figure 1**). Because of the concern for a synchronous lesion, we elected to use a CRE™ Wireguided 15-16.5-18 mm Colonic Balloon Dilator to facilitate passage of the scope through the distal tumor. A second partially obstructing tumor was found in the descending colon. It was again circumferential and measured 3cm in length (**Figure 2**). The proximal mass was traversed using a .035" guidewire under fluoroscopic guidance and a 25mm x 60mm WallFlex® Colonic Stent was passed through the scope, traversed the stricture and deployed under both fluoroscopic and endoscopic guidance (**Figures 3 and 4**). On withdraw of the colonoscope, the .035" guidewire was left in position in the descending colon and a second 25mm x 120mm WallFlex® Colonic Stent was deployed relieving obstruction from the recto-sigmoid tumor (**Figure 5**). Immediate relief of obstruction was noted.

## OUTCOME

During the procedure, immediate decompression was seen as the stent was deployed. Biopsies of the mass confirmed adenocarcinoma. The patient did very well post procedure and was discharged the same day. One month later in oncology clinic follow up he denied any abdominal pain, and was passing bowel movements regularly without difficulty.

## DISCUSSION

In this case the patient was not an immediate candidate for surgical resection due to his liver metastasis. Neoadjuvant chemotherapy for tumor shrinkage and restaging would defer possible surgical therapy for at least three months. Relief of colonic obstruction would allow bridge to surgery at three months or act as a palliative measure. Colonic stenting is less invasive and preferred by most patients than passing stool into a colostomy bag. This case illustrates the unique situation of synchronous obstructing colon cancers in the sigmoid and descending colon that were stented simultaneously after balloon dilation of the first tumor to allow passage of the colonoscope into the proximal colon.



## Bronchial Thermoplasty — Endoscopic Asthma Therapy



CASE PRESENTED BY:

**FELIX JF HERTH, MD**

Head of the Department of Pulmonary and  
Respiratory Critical Care Medicine  
Thoraxklinik Heidelberg  
Heidelberg, GERMANY

*Prof. Dr. Felix Herth is the head of the Department of Pulmonary and Respiratory Critical Care Medicine at the Thoraxklinik Heidelberg. He is an active member of several international associations such as the European Association of Bronchology and Interventional Pulmonology, the World Association of Bronchology and the American Association of Chest Physicians. He has started to treat asthma patients with Bronchial Thermoplasty (BT) at the end of 2011.*

### PATIENT HISTORY

This patient is a 48-year-old female with a 20-year history of severe asthma. For more than ten years she has used all kinds of inhalers to deliver corticosteroids and long acting beta-agonists to control her asthma symptoms. In addition, she has required periodic bursts of oral corticosteroids (prednisone), but her clinical situation remains uncontrolled. She complains of repeated coughing, awakening from sleep about once a week and also the need to seek emergency care for her condition. Her Asthma Related Quality of Life Questionnaire (AQLQ) scores showed the severe limitations due to the disease.

### PROCEDURE

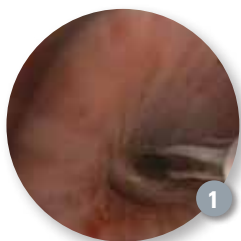
The patient was referred for Bronchial Thermoplasty and between December 2011 and February 2012, the patient underwent BT during three separate procedures to deliver the full treatment. Bronchial Thermoplasty was performed during bronchoscopy with general anesthesia. The airways were treated under bronchoscopic vision

using adjacent activations of the device, moving from distal to proximal (**Figures 1 and 2**). All airways beyond the lobar bronchi, accessible with a bronchoscope, larger than 3mm and up to 10mm in diameter were treated (**Figure 3**).

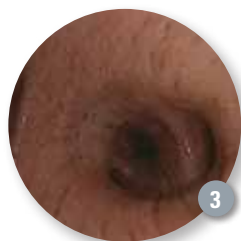### CONCLUSION

All procedures were performed without any complications. The patient left the hospital the day after each procedure. Within three weeks after the first procedure, the patient was less bothered by her asthma symptoms and this improvement continued after each of the following procedures. Her severe asthma exacerbations, which would need rescue medication or oral corticosteroids to manage, were dramatically reduced. The patient demonstrated an increase in her Asthma Quality of Life Questionnaire (AQLQ) scores (demonstrating better quality of life).

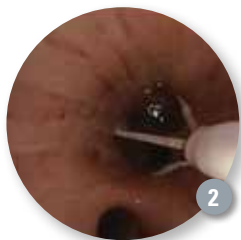This article displays the results/experience of Prof. Herth relating to one case study with the BT therapy.



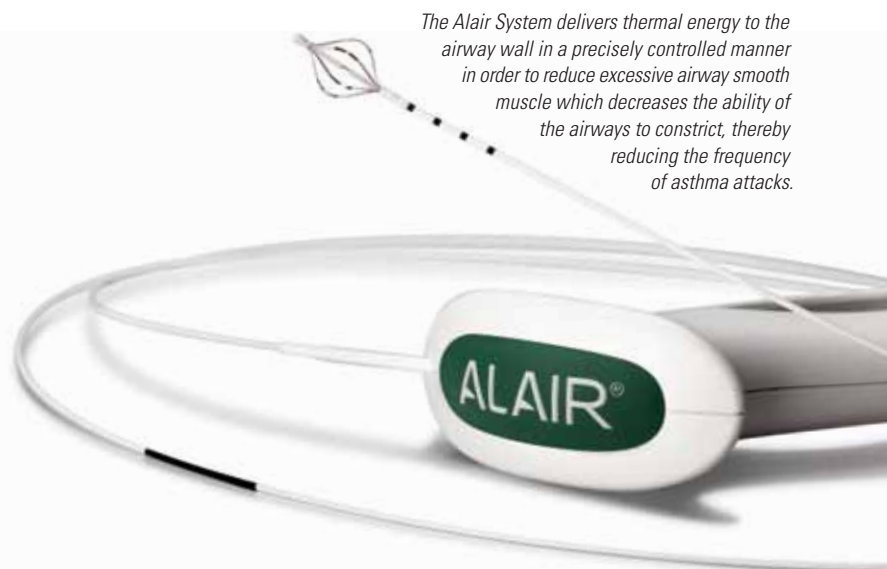
*The catheter in place*



*The intact mucosa directly after the treatment*



*The expanded device in the right lower lobe*



*The Alair System delivers thermal energy to the airway wall in a precisely controlled manner in order to reduce excessive airway smooth muscle which decreases the ability of the airways to constrict, thereby reducing the frequency of asthma attacks.*

Bronchial thermoplasty is a non-drug procedure for the treatment of severe persistent asthma in patients 18 years and older whose asthma is not well controlled with inhaled corticosteroids and long-acting beta-agonists. With the acquisition of Asthmatx and its Alair<sup>®</sup> Bronchial Thermoplasty System in October 2010, Boston Scientific is committed to providing the most advanced technology solutions to interventional pulmonologists and the two million Americans suffering with this disease.

# Running.

But not to the Emergency Room.



“The change has been great. I feel like I am 18 or 20 years old again.”

## Up to Four Different Inhalers, Oral Prednisone and Daily Maintenance

**Medications** are what Mike McLeland was taking to try and help control his severe asthma symptoms. During pollen and cold seasons, Mike would visit the emergency room two to three times a month. In more than one case, an ambulance was called because Mike could not breathe. “Triggers were anything from cats and dogs, to outside pollen and cold weather. Anything like that would trigger my asthma,” Mike explained.

Mike’s quality of life was impacted by his severe asthma, missing time from work, making frequent visits to the emergency room and experiencing unpleasant side effects from the steroid medications. Like Mike, more than two million Americans suffer from severe asthma, many that are still symptomatic despite current drug therapy available today.

Mike decided to participate in a clinical study for the ALAIR® Bronchial Thermoplasty System in 2007, the first procedure to treat severe asthma. Since having the procedure, Mike has been able to participate in an active lifestyle that was not achievable before having bronchial

thermoplasty. He **runs marathons**. He participated in a **bike ride** across Iowa of over 400 miles and competed in a **triathlon**. Mike has also seen a benefit on the job from having the bronchial thermoplasty procedure. For the first time ever, he was able to speak for four hours in front of a class of 200 people without worrying about having to stop due to shortness of breath or wheezing.

*marathons*

## Boston Scientific Sponsors Report Conducted by Asthma and Allergy Foundation of America

### For almost a decade the Asthma and Allergy Foundation of America


(AAFA) has been known for its *Asthma Capitals™ Report* — an annual report that names the 100 most challenging places to live with asthma. The report is an independent research project of the AAFA and in 2012 is being sponsored exclusively by Boston Scientific. The report was made available in May in support of asthma awareness month.

The AAFA has scientifically researched and evaluated conditions in metropolitan areas in America and ranked them based on quality of life for people with asthma. The Foundation reviews 12 factors including: crude death rate for asthma; estimated prevalence of adult and pediatric asthma; risk factors, such as air pollution, pollen counts and public smoking bans; and medical factors, such as the number of asthma medications used per patient and the number of asthma specialists in the area.

The AAFA is the leading national nonprofit organization fighting asthma and allergic diseases. The organization provides free information, conducts educational programs, fights for patients’ rights, and funds research to find better treatments and cures.

# WHAT'S NEW

## Expect 19ga Flex Needle Offers Flexibility and Large Size for Acquiring Tissue Samples



In February 2012 Boston Scientific introduced its new Expect™ 19ga Flex Endoscopic Ultrasound (EUS) Aspiration Needle.

Available worldwide, the needle is designed for acquiring tissue samples under EUS guidance for cancer diagnosis in organs adjacent to the gastrointestinal tract.

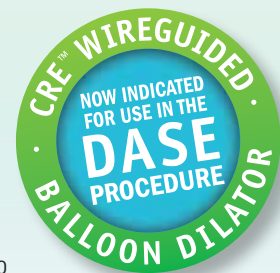
“High-quality diagnostic samples are critical for accurately assessing malignancies and choosing the appropriate treatment path for patients,” said Shyam Varadarajulu, M.D., Chief of Endoscopy, University of Alabama at Birmingham. “The improved design of the Expect 19ga Flex Needle allows for access to challenging anatomy and sampling of solid and cystic lesions where traditional needles of this size can’t be used. These new features provide an important advance in EUS-guided diagnosis.”

The Expect 19ga Flex Needle is made of Nitinol, which offers improved flexibility and resistance to deformation compared to traditional stainless steel needles. The echogenic pattern provides excellent visibility and precise needle guidance within the targeted anatomy. As a result, physicians may be able to more easily and accurately obtain a tissue sample.

## Dilator Balloon Now Indicated for Use in the DASE Procedure

The CRE™ Wireguided Balloon Dilator is now indicated for use in the U.S. (as well as other CE-marked countries) for endoscopic dilation of strictures of the Sphincter of Oddi following sphincterotomy.

The CRE Wireguided Balloon Dilator is constructed of Pebax® and uses a Three-in-One Technology, designed for successive, gradual dilation of strictures, helping to eliminate the need for multiple balloons to employ multi-size dilation therapy. The rounded shoulder design is engineered to help facilitate Balloon Endoscopy and to provide visualization during dilation. The preloaded guidewire is designed to facilitate placement within tight strictures and tortuous anatomy. *See case on p. 5.*



## Boston Scientific is Proud to be a Member of Practice Greenhealth,

the nation’s leading membership and networking organization for institutions in healthcare that have made a commitment to sustainable, eco-friendly practices. With over 1,200 hospital members and 60 supplier members, Practice Greenhealth’s mission is to collaborate and provide education, tools and information about the best environmental practices to help healthcare organizations supercharge their operational efficiency, reduce their environmental footprint, and improve the health of their communities. Through this partnership, Boston Scientific will be able to educate hospitals on how they, too, can be more environmentally friendly and work together towards a common goal. *See article p. 2.*



PRACTICE  
Greenhealth™

ACCESS Magazine was produced in cooperation with several physicians. The procedures discussed in this document are those of the physicians and do not necessarily reflect the opinion, policies or recommendations of Boston Scientific Corporation or any of its employees.

Results from case studies are not predictive of results in other cases. Results in other cases may vary.

**CAUTION:** The law, including Federal (USA) law, restricts these devices to sale by or on the order of a physician. Indications, contraindications, warnings and instructions for use can be found in the product labeling supplied with each device.

**WARNING:** The safety and effectiveness of the WallFlex Biliary Stent for use in the vascular system has not been established.

AdvaniX, Alair, Autotome, CRE, Dreamtome, Expect, Extractor, Hydratome, Jagtome, Jagwire, Resolution, SpyBite, SpyGlass, Trapezoid, Ultratome, WallFlex are registered trademarks of Boston Scientific Corporation or its affiliates.

©2012 Boston Scientific Corporation or its affiliates. All rights reserved.

DINEND2307EB

ENDO-77318-AA May 2012

Boston  
Scientific

Defining tomorrow, today.™