Learn more on:
www.bostonscientific.com/watchman-eu

Results from case studies are not predictive of results in other cases. Results in other cases may vary.
All cited trademarks are the property of their respective owners.
CAUTION: The law restricts these devices to sale by or on the order of a physician. Indications, contraindications, warnings and instructions for use can be found in the product labelling supplied with each device. Information for the use only in countries with applicable health authority product registrations.

SH-205701-AA JAN 2014 Printed in Germany by medicalvision.

Boston Scientific
Advancing science for life™

www.bostonscientific-international.com

DINSH0016EA

Boston Scientific
Advancing science for life™

Reducing the risk of stroke in atrial fibrillation with the WATCHMAN™ Left Atrial Appendage Closure Device

1

Patient Case

With the courtesy of:
Pr D. Babuty, Dr B. Pierre, Department of Cardiology François Rabelais University, Tours, France
Dr S. Debiais, Department of Neurology François Rabelais University, Tours, France

PATIENT HISTORY

A 51-year old man suffering from persistent atrial fibrillation associated with hypertension and type-2 diabetes mellitus was admitted to the neurological department with ischemic stroke in December 2011. He received a vitamin K antagonist (VKAs), and the International Normalized Ratio (INR) control check upon admission was in therapeutic range (2.9). The stroke was localized in the region of the right lenticular capsular artery. A few days later a new cerebral CT showed haemorrhagic transformation of the ischemic stroke (Figure 1), with an unchanged neurological status. VKAs were stopped and the patient went home with antiplatelet therapy only (aspirin 160 mg). The symptoms were fully reversible and the patient recovered, with a neurological status allowing good autonomy (Rankin score = 0).

In August 2012 the patient was still in atrial fibrillation. The neurological examination was normal without sequellae. Cerebral FLAIR MRI showed multiple sequellae of ischemic stroke in the vertebrobasilar region (right cerebellum: Figure 2). A CHA_2DS_2-VASc score of 4 justified permanent oral anticoagulation because the annual risk of a thromboembolism event was 4 %. However, the haemorrhage risk was estimated to be high by the neurologist.

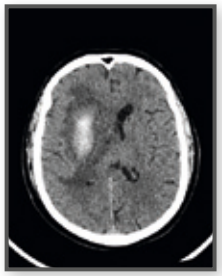

Figure 1

Haemorrhagic transformation of ischemic stroke in the right lenticular capsular artery region.

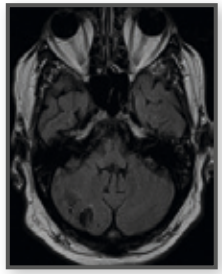

Figure 2

Cerebral MRI showed multiple ischemic sequellae in the right cerebellum six months later.

TREATMENT SELECTION

The implantation of a left atrial appendage closure device was suggested by the cardiologist. Transoesophageal echocardiography was performed and showed a thrombus in the left atrial appendage (Figure 3). After discussion with the neurological team on the benefit/risk ratio of oral anticoagulation therapy it was decided to treat the patient with a new oral anticoagulant agent until the thrombus disappears and later to implant a WATCHMAN device. Dabigatran was administered at 110 mg twice daily.

Figure 3

Thrombus in the left atrial appendage (red line).

In November 2012, a new transoesophageal echocardiography showed the left atrial appendage free of thrombus. Dabigatran was stopped and replaced with (unfractionated heparin. Cardiac CT showed a left atrial appendage as broccoli anatomy.

IMPLANT PROCEDURE

Three days later the thrombus was no longer present after anticoagulation therapy, as demonstrated by repeat TOE, prior to this attempt at WATCHMAN implant. The implantation of a WATCHMAN device (size 21 mm) was performed under general anaesthesia after opacification of the left atrial appendage (Figure 4). An immediate check of the left atrial appendage closure by contrast infusion and echodoppler was excellent,with no peri-device flow. Unfractionated heparin (UFH) was administered for three days after the procedure and then Dabigatran was restated.

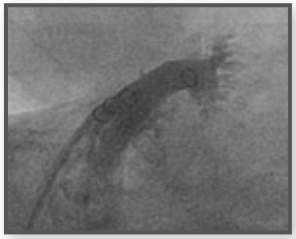

Figure 4

Opacification of the left atrial appendage during the procedure via the sheath.

PATIENT OUTCOMES

In accordance with recommendations we assessed the WATCHMAN device by TOE (transoesophageal echocardiography) 45 days after implantation. The left atrial appendage closure was total, with no flow between the device and the wall of the appendage (Figure 5). Oral anticoagulation was stopped and placed by an antiaggregant agent (aspirin 160 mg), which was definitively stopped in April 2013.

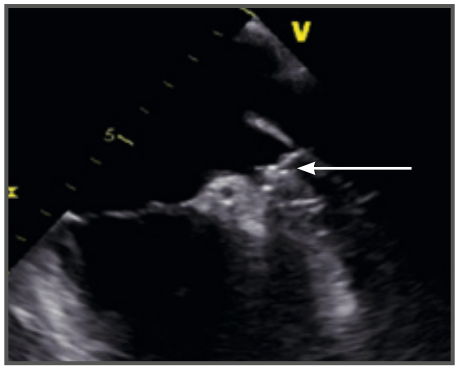

Figure 5

Six weeks after the WATCHMAN implantation TOE showed closure of the left atrial appendage (white arrow)