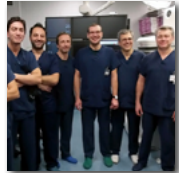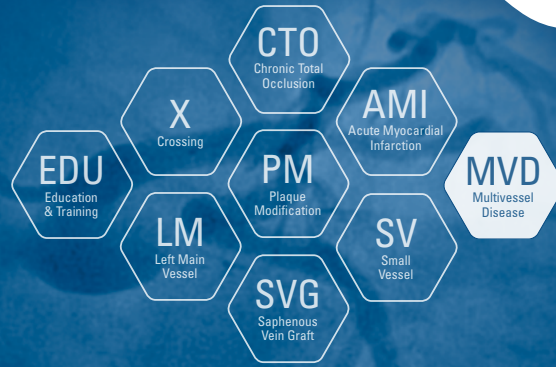


MASTER THE COMPLEX™

Optimizing revascularization through innovation, training, and education.



CASE STUDY

FFR-GUIDED PCI WITH NEW COMET™

FFR PRESSURE GUIDEWIRE REVEALS THE TRUE PICTURE

**Clinica Montevergine, Mercogliano, Italy
Federico II University, Naples, Italy**

Cioppa A., Granata F., Popusoi G., Pucciarelli A., Salemme L., Verdoliva S., Stabile E., Tesorio T.

As interventional cardiologists are being presented with more complex patients, FFR is an essential tool to use to effectively guide PCI. The COMET™ FFR pressure guidewire can be delivered in challenging anatomy and is designed to be easily disconnected and reconnected over the course of the procedure to deliver multiple devices.



70 year old man with previous PCI to RCA

Patient History

- 70 year old man with previous PCI to RCA
- Baseline angiography showed diffuse disease and calcium of the mid LAD (**click on video 1**)

Techniques Used

- Pre-dilation
- Stenting
- FFR pre and post treatment after each procedural step

COMET™ FFR Pressure Guidewire Characteristics

- Asahi co-developed for true workhorse capabilities
- Free rotation while steering and reliable re-connection
- Optical pressure sensor



FFR with adenosine

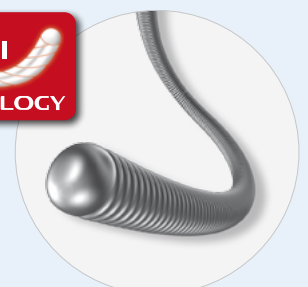Clarify treatment strategy with FFR

- FFR with the new COMET™ Pressure guidewire (0.14" Boston Scientific / Asahi Intecc) was selected to interrogate the lesion
- COMET™ crossed the lesion easily and resting FFR showed a value of 0.76 (borderline value). Intracoronary adenosine was given and the value dropped to 0.59 (**Figure 2**)

KEY LEARNINGS

This case highlights:

- **New Asahi co-developed COMET™ FFR Pressure guidewire's ability to assess and perform PCI with multiple devices and reconnections**
- **How FFR guidance changes treatment strategy and alerts the operator to the need for further intervention in sub optimal PCI - where ischemia is still present**





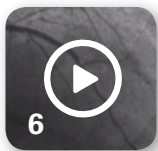3
Pre dilation with semi compliant balloon



4
Positioning of Promus PREMIER™ 2.5 x 38 DES



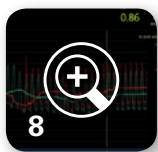5
Inflation of Promus PREMIER™ 2.5 x 38 DES



6
Distal edge dissection and FFR value of 0.73



7
Implantation of distal Promus PREMIER™ 2.5 x 12 DES with FFR value of 0.84 (not pictured)



8
Final angio



9

Pre Dilatation Reveals Calcium

- The COMET™ Pressure guidewire was disconnected and the lesion was pre dilated with a 2.5 x 20 mm EMERGE™ semi compliant balloon. Balloon inflation revealed significant calcium (**click on video 3**)
- Due to significant calcium, the vessel was then treated with a non-compliant 2.5 x 15 mm NC Quantum Apex™. Next, the COMET™ pressure guidewire was re-connected and the resting Pd/Pa was 0.80 (not pictured)

Stents Placed

- Next, a Promus PREMIER™ 2.5 x 38 DES was positioned (**click on video 4**) and inflated (**click on video 5**) and post dilated with a non-compliant balloon 2.5 x 20 mm

Post Stenting FFR performed, edge dissection discovered

- COMET™ was reconnected and IC adenosine was administered, giving an FFR value of 0.73. After further analysis an edge dissection was discovered at the distal stent edge (**click on video 6**)
- A Promus PREMIER™ 2.5 x 8 mm DES was implanted to cover the distal edge dissection. After stent implantation and post dilation with NC Quantum Apex FFR showed yet another FFR value under 0.80

Plaque shift discovered

- Further analysis showed that the limited blood flow was caused by plaque shift due to the initial ballooning with long inflation times. To finish the case, the operator decided to implant the final 2.5 x 12 mm Promus PREMIER™ DES distal to the previous stents (**Figure 7**) with an FFR value of 0.84 (not pictured)

Final FFR performed, non ischemic result

- The final re connection and FFR measurement showed 0.86 (**figure 8**) and the absence of ischemia in the distal left main (**click on video 9**)

SUMMARY

- In this procedure, the use of FFR helped to clarify the continued presence of ischemia, requiring additional treatment methods.
- It's important to note that the last FFR value was negative for ischemia, demonstrating the efficacy of FFR to guide the entire procedure, achieving an optimal final result.
- Numerous disconnections and reconnections of the new COMET™ FFR Pressure guidewire helped the operators to start, treat and perform final measurements without making the procedure longer and more expensive.