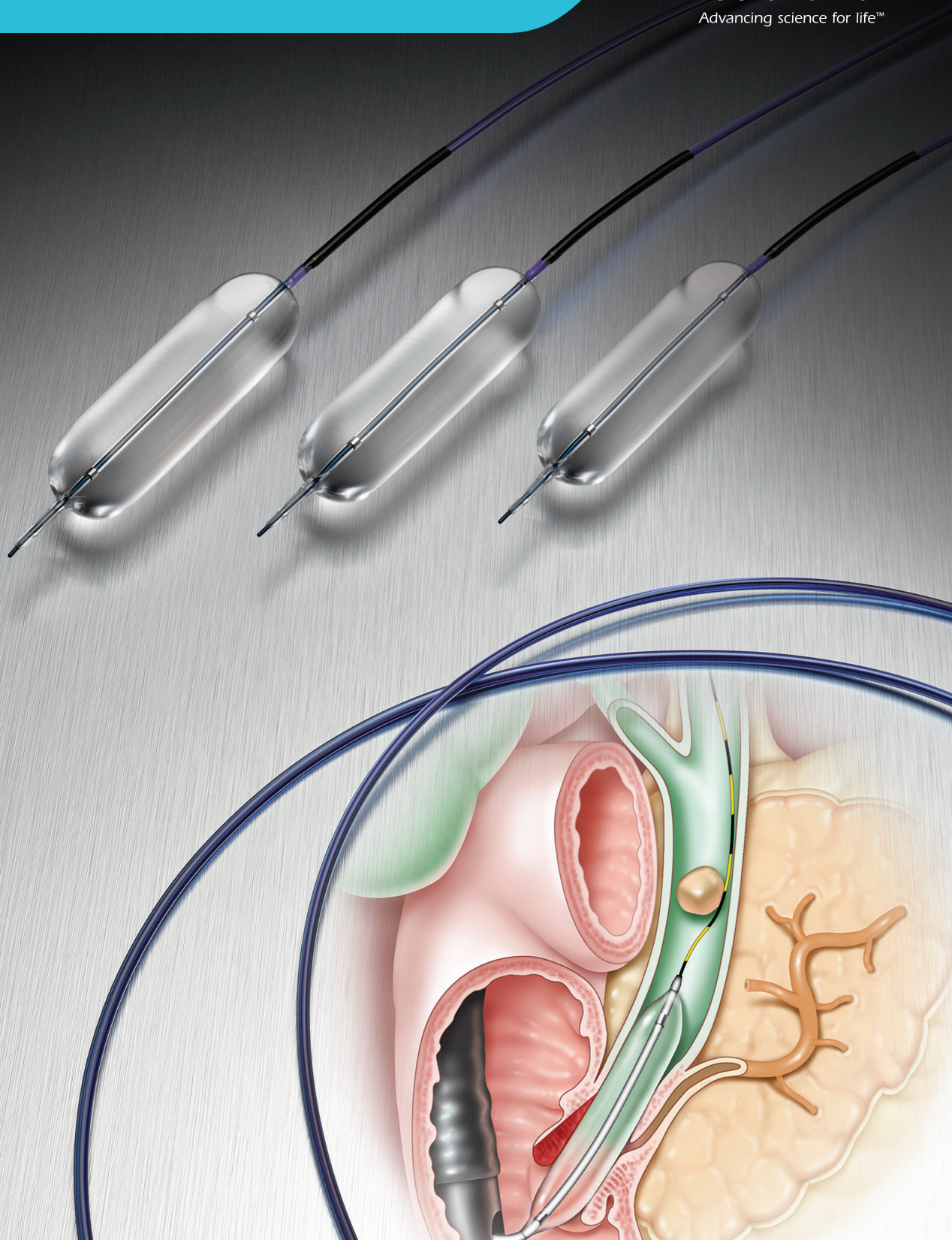


# CRE™ PRO Wireguided Balloon Dilatation Catheter

DASE Abstract Collection

**Boston  
Scientific**  
Advancing science for life™



The abstracts (in this collection) represent the opinions of the authors and are not necessarily the opinion of Boston Scientific.

# Contents

Small Sphincterotomy Combined with Papillary Dilatation with Large Balloon Permits Retrieval of Large Stones without Mechanical Lithotripsy	2
Endoscopic Sphincterotomy Plus Large-Balloon Dilatation Versus Endoscopic Sphincterotomy for Removal of Bile-Duct Stones	3
Post-Sphincterotomy Transampullary Balloon Dilatation is Not Associated with an Increased Incidence of Post-ERCP Pancreatitis	4
The Increase in Balloon Size to Over 15 mm Does Not Affect the Development of Pancreatitis After Endoscopic Papillary Large Balloon Dilatation for Bile Duct Stone Removal	5
Endoscopic Sphincterotomy Combined with Large Balloon Dilatation Can Reduce the Procedure Time and Fluoroscopy Time for Removal of Large Bile Duct Stones	6
Large Size Balloon Dilatation of the Ampulla after Biliary Sphincterotomy can Facilitate Endoscopic Extraction of Bile Duct Stones	7
Large Balloon Dilatation vs. Mechanical Lithotripsy for the Management of Large Bile Duct Stones: A Prospective Randomized Study	8
Biliary Sphincterotomy Dilatation for the Extraction of Difficult Common Bile Duct Stones	9
Endoscopic Balloon Sphincteroplasty as an Adjunct to Endoscopic Sphincterotomy in Removing Large and Difficult Bile Duct Stones	10



## Small Sphincterotomy Combined with Papillary Dilation with Large Balloon Permits Retrieval of Large Stones without Mechanical Lithotripsy

Atsushi Minami, Shinji Hirose, Tomohiro Nomoto, Shoichiro Hayakawa

**AIM:** To introduce a new method: small endoscopic sphincterotomy (ES) combined with endoscopic papillary large balloon dilation (SES + EPLBD) to treat patients with large biliary stones.

**METHODS:** Retrieval of large biliary stones was performed in 88 patients. Mean stone size was  $14 \pm 3$  mm and mean number of stones was  $2.5 \pm 3.5$ . Firstly, ES with a small incision was performed. Next, endoscopic papillary dilation was performed with a large balloon to slowly match the size of the bile duct. Stones were then retrieved from the biliary duct with a balloon and a basket.

**RESULTS:** Stone retrieval was successful in all cases except one cystic duct stone case without the need to crush large stones. Mean procedure time was  $30 \pm 5$  min. Dilating the papillary orifice with a large balloon made it possible to remove large stones smoothly without crushing them. After dilation with the large balloon, there were some instances of oozing, but no perforations. One instance of post-procedural pancreatitis (1%) occurred.

**CONCLUSION:** SES + EPLBD was effective for the retrieval of large biliary stones without the use of mechanical lithotripsy.

## Endoscopic Sphincterotomy Plus Large-Balloon Dilation Versus Endoscopic Sphincterotomy for Removal of Bile-Duct Stones

Jeung Ho Heo, MD, Dae Hwan Kang, MD, Hyo Jin Jung, MD, Dae Sik Kwon, MD, Jin Kwang An, MD, Bo Suk Kim, MD, Kyung Duk Suh, MD, Sang Yong Lee, MD, Joo Ho Lee, MD, Gwang Ha Kim, MD, Tae Oh Kim, MD, Jeong Heo, MD, Geun Am Song, MD, Mong Cho, MD

**BACKGROUND:** Endoscopic sphincterotomy (EST) to remove bile-duct stones is the most frequently used endoscopic technique. Few reports exist regarding application of large-balloon dilation (LBD) after EST for treatment of patients with bile-duct stones.

**OBJECTIVE:** To compare the effect of EST plus LBD with that of EST alone.

**DESIGN:** A prospective randomized controlled trial.

**SETTING:** A large tertiary-referral center.

**PATIENTS AND INTERVENTIONS:** Two hundred consecutive patients with bile-duct stones were randomized in equal numbers to EST plus LBD (12- to 20-mm balloon diameter) or EST alone.

**MAIN OUTCOME MEASUREMENTS:** Successful stone removal and complications such as pancreatitis and bleeding.

**RESULTS:** EST plus LBD compared with EST alone resulted in similar outcomes in terms of overall successful stone removal (97.0% vs 98.0%), large size (>15 mm) stone removal (94.4% vs 96.7%), and the use of mechanical lithotripsy (8.0% vs 9.0%). Complications were similar between the 2 groups (5.0% vs 7.0%,  $P = .767$ ). Complications were as follows for the EST plus LBD group and the EST group: pancreatitis, 4.0% and 4.0%; cholecystitis, 1.0% and 1.0%; and bleeding (delayed), 0% and 2.0%, respectively.

**CONCLUSIONS:** Based on the similar rates of successful stone removal and complications, EST plus LBD should be an effective alternative to EST. EST plus LBD is a safe and effective treatment for endoscopic removal of common bile duct stones.

## Post-Sphincterotomy Transampullary Balloon Dilation is Not Associated with an Increased Incidence of Post-ERCP Pancreatitis

Rahul Nathwani, Kuldip Banwait, Leonardo Salese, David Assis, David E. Loren, Thomas E. Kowalski

**BACKGROUND:** The incidence of post-ERCP pancreatitis has been reported to be significantly higher with ampullary balloon dilation as compared to endoscopic sphincterotomy (15.4% vs. 0.8%). The incidence of post-ERCP pancreatitis when performing ampullary balloon dilation following endoscopic sphincterotomy has not been reported.

**AIM:** To determine the incidence of post-ERCP pancreatitis when performing ampullary balloon dilation following endoscopic sphincterotomy.

**METHODS:** The charts of patients that underwent ampullary balloon dilation at Thomas Jefferson University from 2000 to 2006 were retrospectively reviewed. Data were collected including patient demographics, clinical presentation, indication for ERCP, cholangiographic findings and therapeutic interventions. Dilation was performed with a 4cm long Hurricane® RX hydrostatic balloons (Boston Scientific, Natick MA). Post-ERCP pancreatitis was defined by the presence of abdominal pain consistent with pancreatitis and a serum amylase at least 3 times above the upper limit of normal 24 hours after ERCP. Values are expressed as mean  $\pm$  SEM.

**RESULTS:** Ampullary balloon dilation following endoscopic sphincterotomy was performed in a total of 30 patients with a mean age at presentation of  $55.6 \pm 4.1$  years, of which 21 (70%) were females. The procedure was performed for choledocholithiasis in 15 (50%) patients, ampullary stenosis in 2 (7%) and strictures involving the distal common bile duct (CBD) in 13 (43%) patients. The etiology of the distal CBD stricture was primary sclerosing cholangitis ( $n = 6$ ), cholangiocarcinoma ( $n = 4$ ), chronic pancreatitis ( $n = 2$ ), and pancreas cancer ( $n = 1$ ). Ampullary balloon dilation was performed using a 10 mm dilating balloon in 16 (53%), 8 mm in 4 (13%), 6 mm in 4 (13%), and 4 mm in 5 (17%) patients. One patient was dilated to 13.5 mm using a CRE™ esophageal dilating balloon (Boston Scientific, Natick MA). Post-ERCP pancreatitis developed in 1 patient (3.3%) after dilation with a 6 mm balloon. In this study, post-sphincterotomy ampullary balloon dilation was not associated with either perforation or hemorrhage.

**CONCLUSION:** Ampullary balloon dilation following endoscopic sphincterotomy appears to be safe and is not associated with an increased incidence of post-ERCP pancreatitis. Although more extensive study of this technique is required, endoscopists may be reassured when performing post-sphincterotomy transampullary balloon dilation in order to accomplish therapeutic goals.

## The Increase in Balloon Size to Over 15 mm Does Not Affect the Development of Pancreatitis After Endoscopic Papillary Large Balloon Dilatation for Bile Duct Stone Removal

Young Hoon Youn, Hyun Chul Lim, Jae Hoon Jahng, Sung Il Jang, Jung Hwan You, Jung Soo Park, Se Joon Lee, Dong Ki Lee

**BACKGROUND:** Endoscopic papillary large balloon dilatation (EPLBD) after endoscopic sphincterotomy (EST) has recently become widely used for common bile duct (CBD) stone removal, but many clinicians remain concerned about post-procedural pancreatitis with increasing the balloon size to over 15 mm.

**AIM:** We aimed to evaluate the safety and efficacy of EPLBD with a relatively large balloon (15–20 mm) after EST and to evaluate the factors related to post-EPLBD pancreatitis.

**METHODS:** A retrospective review was undertaken of the endoscopic database of 101 patients with CBD stones who underwent EPLBD using a larger balloon size of over 15 mm (15–20 mm). Clinical parameters, endoscopic data, and outcomes were analyzed.

**RESULTS:** The mean age of the subjects was 69 years. All patients had a dilated CBD of over 11 mm (mean = 22.6 mm). The mean size of balloon used in EPLBD was  $17.1 \pm 1.9$  mm (range 15–20 mm). Mechanical lithotripsy was required in seven patients (6.9%). The rate of complete stone removal in the first session was 92.1%. Post-procedural pancreatitis developed in five cases (5.4%), but none were graded as severe. The smaller dilatation of the CBD, longer cannulation time, and longer time for stone removal were associated with post-procedural pancreatitis, but larger size of balloon did not affect the development of post-EPLBD pancreatitis.

**CONCLUSION:** EPLBD with a large balloon of over 15 mm with EST is an effective and safe procedure with a very low probability of severe post-procedural pancreatitis. Post-EPLBD pancreatitis was not associated with larger balloon size, but was associated with longer procedure time and smaller dilatation of the CBD.

## Endoscopic Sphincterotomy Combined with Large Balloon Dilation Can Reduce the Procedure Time and Fluoroscopy Time for Removal of Large Bile Duct Stones

Takao Itoi, MD, PhD, Fumihide Itokawa, MD, Atsushi Sofuni, MD, Toshio Kurihara, MD, Takayoshi Tsuchiya, MD, Kentaro Ishii, MD, Shujiro Tsuji, MD, Nobuhito Ikeuchi, MD and Fuminori Moriyaso, MD

**OBJECTIVES:** We sought to evaluate the safety, efficacy, and feasibility of endoscopic sphincterotomy plus large balloon dilation (ESLBD) and to compare procedural time and fluoroscopy time of ESLBD with those of endoscopic sphincterotomy (EST) alone for patients with large bile duct stones.

**METHODS:** Retrospective analysis.

**RESULTS:** A total of 101 patients with large bile duct stones were treated: 53 were treated by ESLBD and 48 with EST alone. ESLBD resulted in similar outcomes in overall successful stone removal (100% vs. 97%) and complications (4% vs. 6%); however, although the rate of complete stone removal in the first session using ESLBD tended to be higher than when EST alone was used, it was not statistically significant (96% vs. 85%,  $P=0.057$ ). Mechanical lithotripsy was required significantly more often in the EST group compared to the ESLBD group (25% vs. 6%,  $P<0.01$ ). Total procedure time in the ESLBD group was significantly shorter than that of the EST group (32 vs. 40 min,  $P<0.05$ ). Total fluoroscopy time in the ESLBD group was significantly shorter in the EST group (13 vs. 22 min,  $P<0.05$ ).

**CONCLUSIONS:** ESLBD is an effective and safe treatment in patients with large bile duct stones. In addition, ESLBD appears to decrease procedure time and fluoroscopy time and reduce the need for mechanical lithotripsy as compared to EST alone.

## Large Size Balloon Dilation of the Ampulla after Biliary Sphincterotomy can Facilitate Endoscopic Extraction of Bile Duct Stones

Draganov, Peter V. MD; Evans, William MD; Fazel, Ali MD; Forsmark, Chris E. MD

**GOALS:** Evaluate the efficacy and safety of large size balloon dilation of the biliary orifice after maximal biliary sphincterotomy to facilitate removal of difficult bile duct stones in a Western population.

**BACKGROUND:** Some bile duct stones may be difficult to remove with standard endoscopic retrograde cholangiopancreatography (ERCP) techniques. Even after multiple procedures, and the use of advanced, labor-intensive techniques complete stone clearance may be difficult to achieve.

**STUDY:** This is retrospective review of prospectively collected data. Patients who had failed stone extraction with standard balloon technique after maximal biliary sphincterotomy at the index ERCP underwent large size balloon dilation of the biliary orifice to facilitate stone removal. The main outcomes were complete stone clearance and complications.

**RESULT:** Forty-four patients were evaluated. Thirty-one (70%) had a prior failed ERCP in the past. Periampullary diverticulum was present in 13 patients (30%). Complete stone removal was accomplished in 42 patients (95%). In 37 patients (84%), complete stone clearance was accomplished at the index ERCP without the need for mechanical lithotripsy. Three patients (6%) required an additional ERCP and 2 patients (5%) required 2 additional ERCPs to accomplish complete stone removal. Three mild complications occurred (6.8%). None of the patients developed perforation or pancreatitis.

**CONCLUSIONS:** Large size balloon dilation after biliary sphincterotomy is simple, safe, and highly effective technique that can greatly assist in the management of difficult to extract bile duct stones.

## Large Balloon Dilation vs. Mechanical Lithotripsy for the Management of Large Bile Duct Stones: A Prospective Randomized Study

G. Stefanidis, MD, N. Viazis, MD, D. Pleskow, MD, S. Manalakopoulous, MD, L. Theocharis, MD, C. Christodoulou, MD, N. Kotsikoros, MD, J. Giannousis, MD, S. Sgouros, MD, M. Rodias, MD, A. Katsikani, MD and R. Chutanni, MD

**OBJECTIVES:** The removal of large bile duct stones (>12 mm) after endoscopic sphincterotomy (EST) remains a challenging issue in therapeutic endoscopy. The aim of this prospective, randomized, controlled trial was to compare the effectiveness and complications of EST followed by large balloon dilation (LBD) with that of EST followed by mechanical lithotripsy (ML) for the management of large bile duct stones.

**METHODS:** A total of 90 patients with large bile duct stones (12-20 mm) were randomized to EST followed by LBD (n=45) or EST followed by ML (n=45). Success rate was determined with a final cholangiogram, whereas type and rate of post-procedure complications were assessed prospectively.

**RESULTS:** Complete bile duct stone removal was accomplished in 97.7% of patients subjected to EST-LBD as compared with 91.1% of those subjected to EST-ML (P=0.36). Post-procedure complications were observed in two (4.4%) patients subjected to EST-LBD and in nine (20%) patients subjected to EST-ML (P=0.049). Rates of pancreatitis were similar between the two groups (one case in each), as was post-endoscopic retrograde cholangio pancreatography (ERCP) hemorrhage (one case in each group). None of the patients subjected to EST-LBD developed cholangitis, while this was seen in six patients subjected to EST-ML (0.0 vs. 13.3%, P=0.026). One patient subjected to EST-ML developed perforation, which was successfully managed conservatively. None of our patients with complications died.

**CONCLUSIONS:** EST followed by LBD is equally effective as EST followed by ML for the removal of large bile duct stones, although it is associated with fewer complications.

## Biliary Sphincterotomy Dilation for the Extraction of Difficult Common Bile Duct Stones

J. García-Cano, L. Taberna Arana, C. Jimeno Ayllón, M. Viñuelas Chicano, R. Martínez Fernández, L. Serrano Sánchez, C. J. Gómez Ruiz, M. J. Morillas Ariño, J. I. Pérez García, M. G. Pérez Vígara, E. Redondo Cerezo and A. Pérez Sola

**BACKGROUND AND AIM:** Endoscopic retrograde cholangiopancreatography (ERCP) with biliary sphincterotomy (BS) is the usual method for extracting common bile duct stones. However, following BS and by means of extraction balloons and Dormia baskets a complete bile duct clearance cannot be achieved in all cases. We present a study on the impact that hydrostatic balloon dilation of a previous BS (BSD) may have in the extraction rate of choledocholithiasis.

**METHODS:** A prospective study which included 91 consecutive patients diagnosed with choledocholithiasis who underwent ERCP. For stone removal, extraction balloons and Dormia baskets were used, and when necessary BSD was employed.

**RESULTS:** Complete bile duct clearance was achieved in 86/91 (94.5%) patients. BSD was used in 30 (33%) cases. In these cases, extraction was complete in 29/30 (97%); 23 (76%) patients in the BSD group had anatomic difficulties or bleeding disorders. The most frequently used hydrostatic balloon diameter was 15 mm (60%). There were 7 (7.6%) complications: two self-limited hemorrhage episodes in the BSD group and one episode of cholangitis, one of pancreatitis, and three of bleeding in the group in which BSD was not used.

**CONCLUSIONS:** BSD is a very valuable tool for extracting common bile duct stones. In our experience, there has been an increase in the extraction rate from 73% (Rev Esp Enferm Dig 2002; 94: 340-50) to 94.5% (p = 0.0001, OR 0.1, CI 0.05-0.45), with no increase in complications.



**NOTES**

---



---



---



---



---



---



---



---



---



---



---



---



---



---



---



---



---



---



---



---



---



---



---



---



---



---



---



---



---





Boston Scientific Corporation  
300 Boston Scientific Way  
Marlborough, MA 01752-1234  
[www.bostonscientific.com/gastro](http://www.bostonscientific.com/gastro)

**Ordering Information**  
**1.888.272.1001**

©2015 Boston Scientific Corporation  
or its affiliates. All rights reserved.

ENDO-63304-AD December 2015

All trademarks are the property of their respective owners.

Indications, Contraindications, Warnings and Instructions for Use can be found in the product labeling supplied with each device.

CAUTION: Federal (USA) law restricts this device to sale by or on the order of a physician.

CAUTION: The law restricts this device to sale by or on the order of a physician. Information for the use only in countries with applicable health authority product registrations