

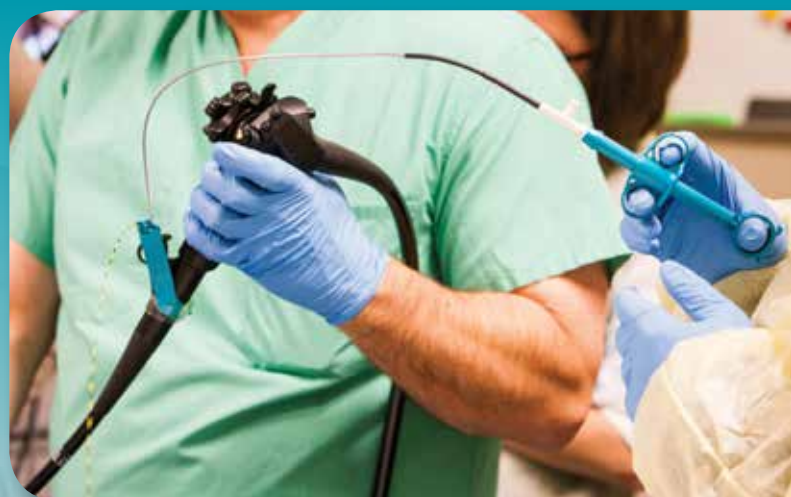access

ENHANCING PATIENT OUTCOMES. DELIVERING TOTAL VALUE.™



The RX Biliary System™

Its role in physician-controlled
wireguided cannulation



A Message From Dave Pierce

Since ERCP became a common practice for gastroenterologists, procedure techniques and application have evolved significantly. Innovation has been an important influencing factor and Boston Scientific has been a key contributor in this area. In both the development and continual improvement of devices and technologies, Boston Scientific has played a role in how physicians treat gastrointestinal diseases.

The RX Biliary System™, the first of its kind short-wire system, was designed to facilitate device exchange during ERCP. Since its introduction in 2001, we've heard



Left to right: **Tim Pratt**, executive vice president and chief administrative officer, **Karen Prange**, president, Urology and Women's Health, **Mike Mahoney**, chief executive officer, **Keith Dawkins**, executive vice president and global chief medical officer, **Mike Phalen**, president MedSurg, and **David Pierce**, president, Endoscopy at the opening of Boston Scientific's headquarters at its Marlborough, Massachusetts campus and home to its Endoscopy business.

from countless physicians and nurses who point to the system and its complementary devices as being easy to learn and easy to use as well as instrumental in helping improve procedural efficiencies (p. 2).

Although clipping for hemostasis had been in practice for a few decades, it continued to present challenges. The introduction of Resolution™ Clip in 2004 (p. 12), with its wide-jaw opening and the ability to reposition prior to deployment, has helped improve the ease of use and control for many physicians and nurses. In addition to clinical benefits — there are more than 220 studies on its safety and effectiveness — there are economic benefits as well. Endoscopic hemostasis appears to be less costly to the hospital than surgery on a per procedure basis and appears to be associated with a shorter length of stay.¹

Since 1981 we have been working to develop minimally invasive devices to advance the practice of endoscopy, and we are continually improving these devices while also developing clinical evidence. A study on the use of fully covered self-expanding metal stents for successful management of benign biliary strictures by Professor Jacques Devière, et al, (p. 4)² was published in the August 2014 journal *Gastroenterology*. Boston Scientific supported the 187-patient prospective study that included 13 tertiary referral centers in 11 countries — one of the largest studies of its kind.

With changes in health care and a focus on cost savings, we are also working with our customers to help address their critical business needs. Lean, supply chain and inventory management are playing a role in improving efficiencies in health care. To date, Boston Scientific has successfully implemented supply chain improvement solutions at more than 40 locations worldwide (p. 6).

Also in this issue is information on new products, including the Captivator™ II Single-Use Snares — the first snares to have both a hot and cold indication for clinical flexibility — and the Advanix™ Pancreatic Stent, our first stent indicated for the pancreas (back cover). New products are the result of great ideas. If you have a great idea, share it with us through our Innovation Portal at www.bostonscientific.com.

Dave Pierce

Senior Vice President, Boston Scientific
President, Endoscopy Division

1) Analysis performed by Boston Scientific's Health Economics & Reimbursement team utilizing 2009 Medicare IPPS and OPSS datasets.

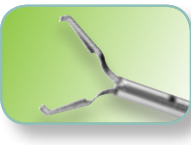


2) WallFlex™ Biliary RX Stents - Fully Covered, Partially Covered and Uncovered - are available in the United States and are indicated for use in the palliative treatment of biliary strictures produced by malignant neoplasms and for use in preoperative drainage of malignant biliary strictures. WallFlex Biliary RX Stents are not indicated in the United States for use in benign biliary strictures. The safety and effectiveness of the stent for use in the vascular system have not been established. WallFlex Biliary RX Stents are CE Marked for use in the palliative treatment of biliary strictures produced by malignant neoplasms and for treatment of benign biliary strictures.

Inside This Issue

Articles

- | | | | |
|--|---|---|--|
|  | 2 The RX Biliary System Still Having an Impact on the Practice of Endoscopy |  | 8 Boston Scientific Sponsors 'Train the Trainer' Event in Russia |
|  | 4 Prospective Multinational Study Published on Management of Benign Biliary Strictures |  | 9 Expanding Opportunities for Physician Education in China is Focus of Endoscopy Institute |
|  | 5 Helping Health Care Providers Navigate Complex International Landscapes |  | 9 Physicians from China Take a Hands-on Approach to Learning New Technologies |
|  | 6 GS1/GTIN Transition, Supply Chain Services, GPO Ranking in Europe |  | 10 Closing the Gap in Pancreatic Cancer |
|  | 7 Colon Cancer Survivor Advocates for Screening |  | 11 Boston Scientific Supports Advancements and Education for Patients Living with Tube Feeding Devices |
|  | 7 Working with the National Pancreas Foundation: New Online Resources for Patients and Physicians |  | 12 Resolution™ Clip – Playing an Important Role in the Practice of Hemostasis |
|  | 7 Boston Scientific Biliary Metal Stent is First with Pre-operative Drainage Indication |  | 18 News and New Devices |

Case Studies

- | | | | |
|--|--|---|---|
|  | 13-14 Resolution™ Clip Device |  | 16 CRE™ Single-Use Wireguided Balloon |
|  | 15 TWISTER® PLUS Rotatable Retrieval Device and Captivator™ II Single-Use Snares |  | 17 Expect™ Slimline (SL) Needle for EUS FNA |

The RX Biliary System

Still Having an Impact on the Practice of Endoscopy

More than a decade after its launch, the RX (Rapid Exchange) Biliary System™ is still changing the way endoscopic retrograde cholangiopancreatography (ERCP) is practiced worldwide.

Before Boston Scientific introduced the RX Biliary System in 2001, the only ERCP guidewires on the market were long guidewires. An assisting nurse or technician had to control the wire while the physician controlled the ERCP devices, requiring a great deal of communication and coordination. At the same time, the assistant might have to perform multiple tasks — advancing or retracting the guidewire, injecting dye, operating the device, inflating or deflating the balloon, flexing or relaxing the sphincterotome.

Getting it wrong could make cannulation more difficult, create problems advancing the wire to its desired target, cause the team to lose access to the bile or pancreatic ducts. “If you were trying to traverse a difficult stricture you might be pushing too hard and not know it because someone else was manipulating the wire,” says Oleh Haluszka, MD, chief of gastroenterology at Temple University School of Medicine, Philadelphia, Pennsylvania.

PUTTING CONTROL IN THE HANDS OF THE PHYSICIAN

The RX Biliary System, the first short-wire system of its kind, allowed physicians to control the wire. “I learned very quickly the benefits of a short-wire system,” says Josh Forman, MD, therapeutic endoscopist/gastroenterologist at the University of Maryland St. Joseph Medical Center.

“When you had someone else passing the wire it wasn’t the same. With the short-wire system, over time you develop a sense of tactile feedback that is incredibly invaluable. Now I couldn’t imagine doing this procedure without having my finger on the wire.”

“As the person responsible for the success or failure of the procedure, I want to have as much control in my hands as possible,” says Dr. Haluszka. “I want the feedback of the wire as I’m working in the duct, knowing that it’s looping the right way, not going into a side branch. When you control the wire, your brain is giving that message to your hands as opposed to verbalizing it to someone else. There’s less uncertainty about how hard to push.”

“I deal with a lot of malignant lesions,” explains Niraj Jani, MD, chief division of gastroenterology at the Greater Baltimore Medical Center, Maryland. “If you’re dealing with an obstructive lesion, you want to have a tactile sense of the stricture and ensure that you’re not going into a false tract or creating a perforation. With the RX system, you have the tactile sense and can make adjustments if you’re having trouble accessing the bile duct. The RX System allows you to assess the situation quickly and change what you need to do.”

RX LOCKING DEVICE KEEPS WIRE IN PLACE

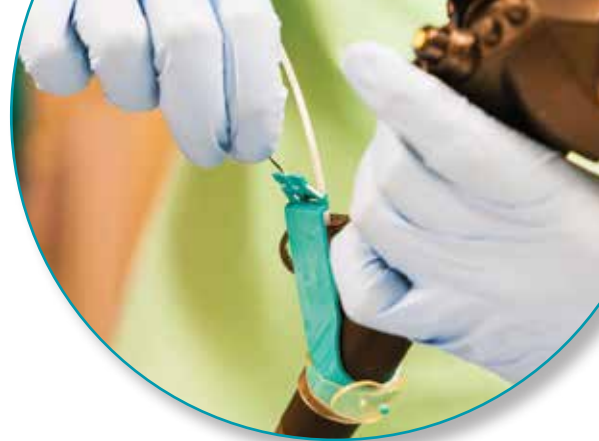The RX Biliary System locking mechanism used in conjunction with compatible RX devices helped enable physicians to make an exchange without displacing the wire.

“With the older cannulation systems, your biggest responsibility was to never lose the wire,” says Dr. Jani. “In some cases, with one little movement you would lose the wire and have to start the whole case again which can be extremely frustrating in a difficult cannulation case. The RX system gives you benefit of locking the wire in place.”

“The locking mechanism is especially helpful in complicated cases,” says Enrico Souto, MD, assistant professor and director of endoscopy at the University of Miami. “For example, you might need to cannulate both the left and right lobes of the liver. With RX, you can lock the first wire in place and move to the other side without worrying.”

ADVANTAGES FOR PATIENTS AND PHYSICIANS

When the RX Biliary System became available, some physicians immediately recognized its potential to help improve procedural efficiency. But they soon learned that while the system did indeed allow them to reduce the duration of a procedure, it also had other advantages for patients such as reduced fluoroscopy exposure and sedation requirements.



“With the RX system, I use a lot less fluoroscopy than I used to,” says Dr. Jani. “I don’t shoot a lot of dye because I don’t need to — I know where the wire is going. I only inject when I know I’m in the duct and I’m looking for something specific. Even when there is a malignancy, I don’t have to fill up the whole biliary system. I put in my stent and I’m done.”

Physicians also appreciate reducing their own exposure to fluoroscopy. “I’ve been practicing ERCP for 20 plus years so the less fluoro time the better,” Dr. Haluszka says. “That’s a concern for everybody in the room. The less radiation exposure for staff and patients the better it is.”

“RX really does improve your time of cannulation,” Dr. Jani says. “We used to intubate patients for ERCP. Now the majority of my cases in otherwise healthy patients are done under conscious sedation. You’ve just reduced an operating-room level procedure to a routine endoscopy. Recovery time is shorter and patients don’t complain of a sore throat.”

A SHIFT IN FOCUS TO COST SAVINGS

“It’s hard to imagine, but when we first launched the RX system in 2001, the economic pressures we have today didn’t exist,” says Ryan Hartman, director of marketing, Boston Scientific. “Physicians were focused on the clinical benefits of shorter and successful ERCP procedures.”

“But as economy became increasingly important, hospitals began scrutinizing costs. As they evaluated devices on a number of criteria important to them, including their own outcomes data, performance, safety, ease of use, etc., the RX Biliary System has prevailed and proven to be increasingly advantageous.”

RX IS EASY TO LEARN, EASY TO TRAIN

Over the years, feedback from physicians has been that the RX Biliary System is easy to learn. “Working with a shorter wire and the RX system makes ERCP so much easier on physicians and on our technicians,” Dr. Forman says. “They learn so much more quickly and while they help handle the wire, they never have to push. That really decreases the anxiety level in the room.”

Jennifer Maranki, MD, assistant professor at Temple University School of Medicine, says that the RX System also makes it easy for a supervising physician to train fellows. “Instead of worrying about the long exchange, you can dedicate more time to teaching them about scope position and other aspects of the procedure that are related to the devices being used,” she says.

CONTINUED INNOVATION

Widespread adoption of the RX Biliary System has profoundly changed how ERCP is performed. “I’ve been using the RX system since it came out and it’s become a more full complement of devices over time,” Dr. Haluszka says. “That really lends itself to my type of practice, which is geared towards therapeutic procedures.”

“Boston Scientific continues to refine its products to improve and grow,” Dr. Jani says. “They’ve branched into other areas that really help us with tissue acquisition. I do a large number of endoscopic ultrasounds and Boston Scientific is constantly looking to improve their EUS needles.”

BOSTON SCIENTIFIC AS A VALUED PARTNER

“One thing that really stands out for me about Boston Scientific is its level of customer support,” Dr. Forman says. “When we’re using new equipment or a technician is relatively new and needs training, we need help from our reps and they do an amazing job being there for us.”

“What separates Boston Scientific from other companies is that the sales representatives are constantly doing in-service training and educational conferences throughout the year for the nurses and technicians,” Dr. Jani says. “Their approach is much more academic. They don’t just bring in a product — they provide the clinical data and evidence to support their devices.”

Adoption Outside the U.S.


Physicians outside the U.S. also recognize the benefits of the RX biliary System. To date, the RX locking device and RX compatible devices are in use in over 45 countries, including China, Brazil and many countries throughout Europe.

“The system gives me control of the guidewire without having to communicate specific instructions to my assistant. Having control of the wire has increased my cannulation success rate,” explains Dr. Teresa Staiano of the Institute of Ospitalieri, Cremona, Italy.

“Using the locking device I can perform multiple exchanges and withdrawal of devices with a reduced risk of losing the guidewire. Maintaining access and controlling the exchange of devices is critical for therapeutic ERCP.”

Prospective Multinational Study Published on *Management of Benign Biliary Strictures*

A study on the use of fully covered self-expanding metal stents for successful management of benign biliary strictures by Professor Jacques Devière, et al, was published in the August 2014 journal *Gastroenterology*. The study was designed to evaluate the ability to remove the Fully Covered WallFlex™ Biliary RX Stent after extended indwell and to determine treatment success of biliary obstructions resulting from benign biliary strictures.



Boston Scientific funded the **187-patient prospective study** that included **13 tertiary referral centers** in **11 countries** and **5 continents** – one of the largest study of its kind.

“The results of this study reinforce that fully covered self-expanding metal stent placement has the potential to reduce the number of ERCP procedures required in the management of benign strictures,”

said Boston Scientific Endoscopy President, Dave Pierce. “Boston Scientific is committed to advancing science through investment in clinical research and improving quality of life for patients.”

DATA HIGHLIGHTS¹

- The WallFlex Biliary RX Stents were successfully removed by endoscopy from all 155 patients in whom this procedure was attempted.
- Stricture resolution without the need to restent at the time of stent removal was successful in approximately 75% of patients.
- Approximately 85% of these patients remained stricture-free after a mean follow-up of 20 months.
- The study results demonstrate that fully covered self-expanding metal stents are an effective treatment alternative to plastic stents, and may significantly reduce the need for multiple sequential endoscopic retrograde cholangiopancreatogram stent exchanges and the associated complications and costs.

1. <https://clinicaltrials.gov/ct2/show/NCT01543256>

WallFlex™ Biliary RX Stents – Fully Covered, Partially Covered and Uncovered – are available in the United States and are indicated for use in the palliative treatment of biliary strictures produced by malignant neoplasms and for use in preoperative drainage of malignant biliary strictures. WallFlex Biliary RX Stents are not indicated in the United States for use in benign biliary strictures. The safety and effectiveness of the stent for use in the vascular system have not been established. WallFlex Biliary RX Stents are CE Marked for use in the palliative treatment of biliary strictures produced by malignant neoplasms and for treatment of benign biliary strictures.

Helping Health Care Providers Navigate Complex International Landscapes

In the European Union (EU), economic pressures and varying country regulations create a challenging and complex landscape for health care providers and the companies that offer products and services to them. To begin with, each country within the EU has unique regulations, and many countries — Italy and Spain, for example — have more than a dozen regions, each with its own reimbursement practices.

“Unlike the U.S., in many of the European countries there aren’t clear pathways to address the clinical and cost benefits of new health technologies to governments and payers,” says Luca Stefanini, Boston Scientific’s market access manager for Endoscopy in the EU. “We have to explore new pathways with the local network each time.”

To meet these challenges, Boston Scientific created the Health Economics and Government Affairs Team (HEGA) serving not only Europe but all regions outside the United States, and which is supported by the Health Economics and Reimbursement team. HEGA collects, analyzes and presents clinical outcomes and cost data to the appropriate authorities and makes the case for reimbursement.

The HEGA team interacts directly with physicians, hospitals, researchers, third-party payers, patient organizations, scientific societies and government entities. The team also works closely with Health Technology Assessment (HTA) bodies, regional and national agencies throughout the EU that are responsible for evaluating the clinical and cost effectiveness of health technologies.

“Health care trends across Europe are not drastically different, yet conditions and goals of individual health care systems can vary greatly. In order to be effective, HEGA needs to maintain a clear understanding of these variations at the national, regional and local levels,” explained Mark McIntyre, senior director of HEGA Europe.

DEMONSTRATING VALUE, WINNING ACCESS FOR PATIENTS

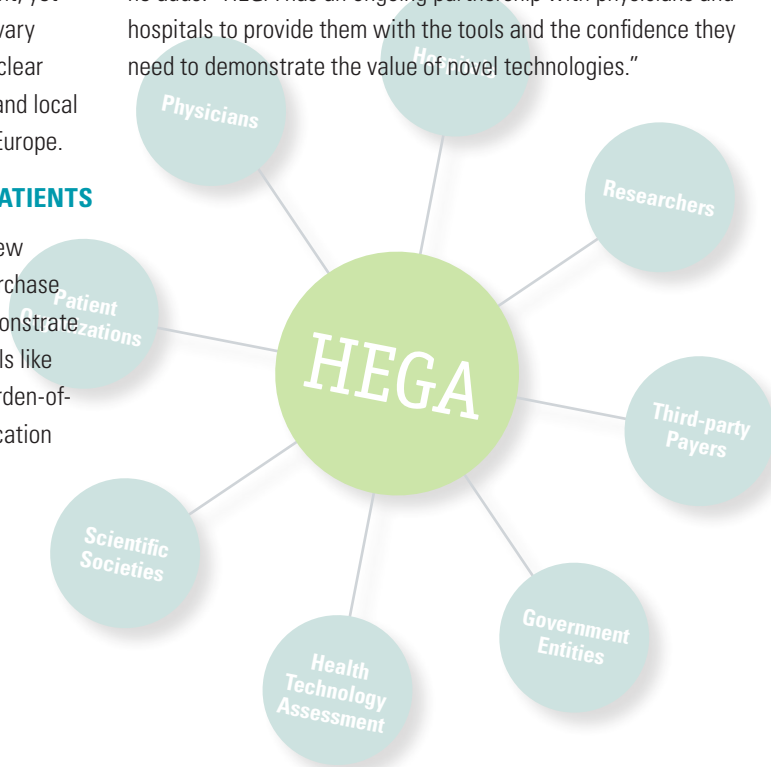
“Often, physicians recognize the potential clinical value of new technologies for their patients, but lack the resources to purchase them,” Stefanini says. “Our health economists work to demonstrate the value of our technologies through health economics tools like cost-effectiveness analyses, budget-impact models and burden-of-disease assessments. The final scope is to obtain fund allocation or reimbursement.”

“Sometimes we are brought in early in the research process, so that we can provide sources for economic data to help clinicians demonstrate cost as well as clinical effectiveness,” he adds.

HEGA also provides customers with training and education. Last year the HEGA team identified an unmet need in Italy for administrators and institutional clinicians to better understand health economic principles. “Collaboration between clinicians and administrators is often scarce,” Stefanini explains. “We helped to bridge this gap through training.”

Stefanini also cited the example of a hospital in the UK where physicians were eager to adopt Boston Scientific’s WallFlex™ Biliary RX Metal Stents but procurement preferred to use plastic stents, which are available at a lower price. With help from HEGA, the hospital was able to demonstrate that the higher acquisition cost of WallFlex Stents was more than offset by other savings.

“Our relationship with customers is focused on patient therapies and developing economic evidence in support of these procedures,” he adds. “HEGA has an ongoing partnership with physicians and hospitals to provide them with the tools and the confidence they need to demonstrate the value of novel technologies.”



GS1/GTIN Transition:

Global Standards Helping Customers Improve Supply Chain Efficiencies

GS1 are the most widely used supply chain standards in the world. By adopting these standards and implementing Global Trade Item Numbers (GTINs) for its packaging, Boston Scientific is helping to better serve its customers and play a part in improving supply chain efficiencies. GTINs adhere to GS1 standards and serve as globally unique identification numbers of an item in the supply chain as it moves from manufacturing through distribution and use. The GTIN numeric code and corresponding bar code identify key product attributes.



BENEFITS OF STANDARDIZATION

Having a single common method to identify product is a critical step in helping trade partners better manage their supply chains – ultimately helping to improve efficiencies and thereby reducing costs. As GTIN is adopted and implemented within the medical device industry, a range of potential benefits could be realized, including improved inventory management, product tracking for estimating deliveries and calculating the cost of devices used per procedure.

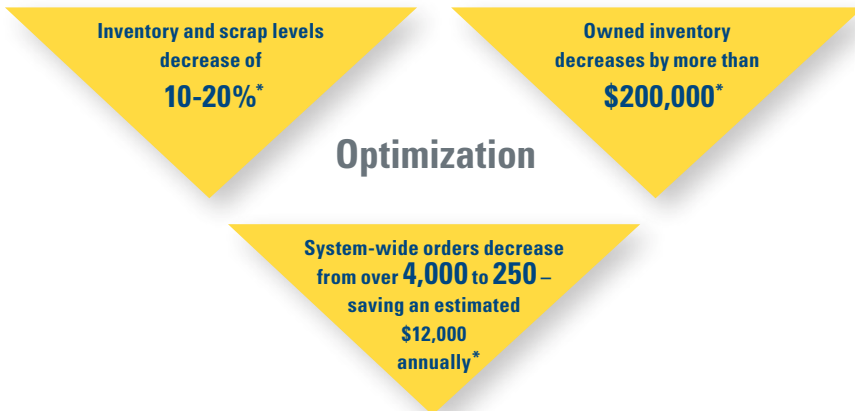
CUSTOMER IMPACT

Implementation of GTIN product labels began in March of 2014 and all products are expected to be completed by the end 2014. These changes will impact only those customers who are currently scanning product label bar codes as they will need to add the GTIN to their materials management information systems. For customers who do not scan bar codes, the UPN will remain on the label for their continued use. Products may be ordered from Boston Scientific using either number.

A complete list of products transitioning to the GTIN part numbers along with their original HIBC UPN part number may be found at www.bostonscientific.com/gs1. Customers may send questions to GS1CustomerInquiries@bsci.com.

Operational Efficiencies and Cost Savings are Focus of Boston Scientific Optimization Services

To date, Boston Scientific has successfully implemented supply chain improvement solutions at more than 40 locations worldwide. By working with Boston Scientific, health care providers achieved results such as:



The Supply Chain Essentials program offers a strategic approach and includes a range of services to help health care providers improve operational efficiencies and cost savings measures. Services include inventory optimization, order consolidation, vendor management inventory (VMI), supply chain simplification, and more.

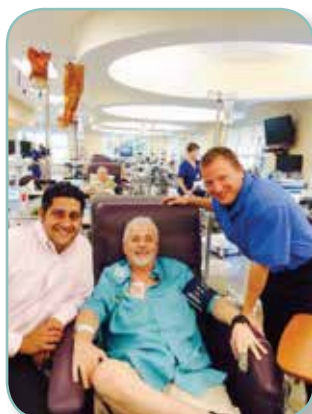To learn more email SupplyChainEssentials@bsci.com.

*Findings based on current BSC customer results. Actual results may vary.

GPO in Europe Ranks Boston Scientific as Top Supplier

Boston Scientific ranked in the top five best-performing medical device suppliers during a 2013 assessment. The company was among 50 suppliers evaluated by a major group purchasing organization in Germany composed of approximately 400 hospitals. Boston Scientific received high marks in the following evaluation criteria categories: on-time delivery, communication, service and flexibility, quality and environment.

Colon Cancer Survivor Advocates for Screening



Boston Scientific employees Michael Frino and Ryan Rector visit Mark Braden during one of his chemotherapy treatments.

Colorectal cancer is one of the most preventable yet least prevented cancers.

The Bradens are sharing their story to educate others and to urge individuals over age 50 to get screened. When Mark Braden turned 50, his physician recommended that he have a sigmoidoscopy—and not a colonoscopy—to screen for colorectal cancer. That would turn out to be one of his biggest regrets. As a result, his cancer was not detected because a sigmoidoscopy only screens

part of the colon. At age 55, Mark was diagnosed with Stage IV colon cancer. Over the next two years, Mark would undergo multiple surgical procedures and chemotherapy treatments before finally being told that there were no more treatment options available.

Feeling hopeless, Mark's wife Patti went online to search for a solution and read about WallFlex™ Colonic Stents on the Boston Scientific website. Shortly after conducting her research, Patti was introduced to Michael Frino, a Boston Scientific sales representative.

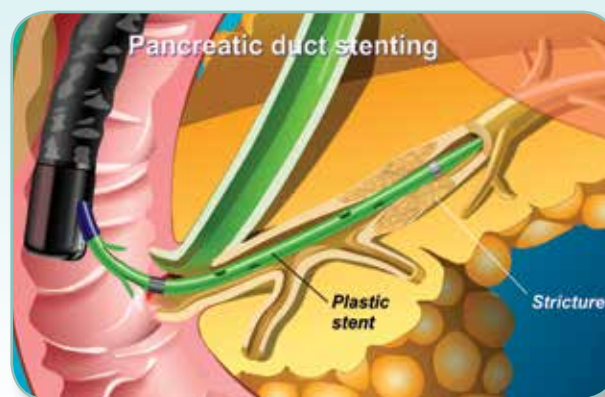
Mark was not a candidate for a colonic stent, but Frino was able to connect Mark with a local surgeon who provided treatment options when Mark was previously told he had none.

Now 58, Mark considers his experience to be a miracle. **“We consider ourselves blessed to laugh, cook together and enjoy sunsets on the beach,”** he said. **“I wish I had a colonoscopy in the beginning so I could have spared my family this painful journey. I urge others to get screened at 50 or younger if they are high risk.”**

The Boston Scientific Close the Gap team recently developed and launched new web content to help educate patients about colorectal cancer, risk factors and the importance of screening for prevention. The following site is now available to share with patients who may be at high risk for the disease: www.preventcrc.com.

Working with the National Pancreas Foundation: **New Online Resources for Patients and Physicians**

With funding from Boston Scientific, the National Pancreas Foundation has developed videos to educate patients about endoscopic retrograde cholangiopancreatography and endoscopic ultrasound fine-needle aspiration. The videos, along with other information on pancreatic diseases are intended to provide easy-to-understand information for patients, and to enhance communication between patients and physicians. Visit www.pancreasfoundation.org or www.animatedpancreaspatient.com.



Pancreatic duct stenting is explained as part of the Understanding ERCP video.

Boston Scientific Biliary Metal Stent is First with Pre-operative Drainage Indication

The U.S. Food and Drug Administration (FDA) recently cleared the expanded indication for WallFlex™ Biliary RX Metal Stents for the treatment of biliary strictures produced by malignant neoplasms and relief of malignant biliary obstruction prior to surgery. With the expanded indication, the use of WallFlex Biliary RX Metal Stents may be an option for pre-operative drainage of the bile duct for patients who are receiving neoadjuvant chemotherapy before undergoing surgery. This represents the first biliary metal stent with labeling to support pre-operative drainage.

NOTE: Use of the WallFlex Biliary RX Fully Covered Stent for the treatment of benign strictures or stenoses has not been cleared for use in the United States.

WARNING: The safety and effectiveness of the WallFlex Biliary Stent for use in the vascular system has not been established.

Boston Scientific Sponsors *'Train the Trainer' Event in Russia*

Russian physicians in collaboration with the World Endoscopy Organization (WEO) organized a two-day training event held July 11-12, 2014, in Moscow. Unlike other gastrointestinal endoscopy training that is purely clinically focused, the Program for Endoscopic Teachers focused on best-practice methods for instructing and organizing endoscopic training programs. Boston Scientific was the sole sponsor of the "train the trainer" event, providing financial and in-kind support, including "the use of several porcine models which played a key role in the hands-on portion of the training."

"We brought together 15 of our top endoscopists in Russia to take part in this training," explained Professor Evgeny Fedorov.

"In order to effectively expand and advance the practice of endoscopy in Russia, we need to focus on becoming effective teachers as well as sharing clinical knowledge. This is of particular importance when instructing trainees in residency or fellowship programs for which we designed this program."



Physicians and members of the Boston Scientific education team at the training event held in Moscow, Russia.

Professor Evgeny Fedorov from the University Hospital N31, Moscow, Russia, and Professor Douglas Faigel from the Mayo Clinic in Scottsdale, Arizona, worked closely with the WEO and Boston Scientific to organize the training. They also participated as part of the faculty that was made up of key opinion leader physicians from around the world, including Dr. James Anthony DiSario of the U.S.,

Professor Marina Khrustaleva of Russia, Professor Mikhail Korolev of Russia, Dr. Nageshwar Reddy of India, Dr. Roque Saenz of Chile,

Professor Yury Starkov of Russia, Professor Thierry Ponchon of France, and Dr. Jacques Van Dam of the U.S.

Evaluating trainee skills, developing materials and determining facility requirements were a few of the agenda topics. In addition to presentations, breakout sessions allowed faculty and attendees to discuss local issues

impacting training, how to structure training programs, as well as the availability of online resources for endoscopy teachers, research and publications. During hands-on sessions, stations with porcine models were used to demonstrate how to teach endoscopic retrograde cholangiopancreatography access and therapeutic techniques, metal stenting, hemostasis and endoscopic ultrasound fine needle aspiration.

“In order to effectively expand and advance the practice of endoscopy in Russia, we need to focus on becoming effective teachers as well as sharing clinical knowledge. This is of particular importance when instructing trainees in residency or fellowship programs for which we designed this program.”

— **Professor Evgeny Fedorov**
Moscow, Russia

Expanding Opportunities for Physician Education in China is Focus of Endoscopy Institute



From left to right: Professor Suning You, director of continuing education ministry of the Chinese Medical Association and Professor Zhaoshen Li, chairman of the Chinese Society of Digestive Endoscopy, with Michael Durkin from Boston Scientific.


In March of 2014, Boston Scientific opened the doors to its new Endoscopy Institute as part of the company's Institute for Advancing Science and Innovation Center in Shanghai, China. More than 20 key opinion leader physicians attended the opening ceremony, including Professor Zhaoshen Li, chairman of the Chinese Society of Digestive Endoscopy and Professor Suning You, director of Continuing Education at the Ministry of the Chinese Medical Association. In addition, the group participated in an education summit roundtable where they discussed the challenges and opportunities of ERCP training.

The Endoscopy Institute will serve as a focal point for conducting training using its state-of-the-art facilities, performing academic research, developing education programs and more. An advisory board made up of national experts is responsible for the development of the curriculum. These education programs are expected to provide training opportunities to approximately 670 practitioners throughout China.

Physicians from China Take a Hands-on Approach to Learning New Technologies

Disease states as well as procedural techniques for cholangiopancreatography and endoscopic ultrasound fine-needle aspiration were the focus of a day-long training session for 14 physicians visiting from China. The May 6, 2014 training took place at the American Society for Gastrointestinal Endoscopy Institute for Training and Technology located in Downers Grove, Illinois, and was hosted by Boston Scientific.

Dr. Cai Qiang from the Emory University School of Medicine, Atlanta, Georgia, and Dr. Sammy Ho from the Montefiore Medical Center, Bronx, New York, served as facilitators and presenters. In addition to the didactic portion, a significant amount of time was devoted to hands-on training in small groups. This gave the attendees ample time to discuss disease state management and address physicians' individual case scenarios.



From left to right: Dr. Gao Dao Jian, Eastern Hepatobiliary Surgery Hospital, Shanghai and Dr. Chen Sheng, Shanghai Ruijin Hospital at the training session.

Closing the Gap

in Pancreatic Cancer



Over the past year, the Boston Scientific Close the Gap team sponsored and participated in a number of events in support of the fight against pancreatic cancer, including the New England Pancreatic Cancer Research Walk and several educational symposiums for employees. Teams from local Boston Scientific offices in Illinois and New York also participated in regional walks to generate awareness about the disease. Through various fundraising efforts, more than \$35,000 was raised by the Close the Gap team in 2013 and donated to The Lustgarten Foundation to support pancreatic cancer research.

In 2014, Boston Scientific's Close the Gap team plans to partner with organizations to continue its education efforts as well as fundraising to find a cure. Organizations with participation opportunities are welcome to contact the Close the Gap team: CloseTheGap@bsci.com.

In 2014, an estimated 280,000 individuals around the world will receive a pancreatic cancer diagnosis, the majority of whom will die of the disease¹. Pancreatic cancer is the fourth leading cause of cancer related death, and it is expected to become the second leading cause by the year 2020¹. To date, there is no prevention or cure for this deadly disease.

The Lustgarten Foundation is a not-for-profit organization created in 1998 to advance the science related to the diagnosis, treatment, cure and prevention of pancreatic cancer. 100% of every donation they receive goes directly to pancreatic cancer research. Boston Scientific began its relationship with The Lustgarten Foundation in 2012. Learn more about The Lustgarten Foundation or make a donation by visiting: www.lustgarten.org.

more than **\$35,000** raised



¹ Statistics provided by The Lustgarten Foundation: www.lustgarten.org

Boston Scientific Supports *Advancements and Education for Patients Living with Tube Feeding Devices*

Through sponsorship and event participation, Boston Scientific is working with organizations that are supporting advancements in jejunal feeding tubes as well as education on the use of these devices.

The Oley Foundation is a national independent non-profit organization that through education, outreach and networking works to enrich the lives of patients dependent on home intravenous and tube feeding. In 2014, Boston Scientific became a Silver Sponsor of the organization and exhibited for the first time at the Oley Conference held June 23-27, in Orlando, Florida. More than 200 patients and caregivers attended the conference and exhibit to learn about disease management and developments in tube feeding devices.

Amanda Singer, who has been living with gastroparesis for several years, joined the Boston Scientific exhibit to speak with conference participants. Singer talked about how the EndoVive™ Through-The-Peg (TTP) Jejunal Feeding Tube helped her regain her active life, and how it helped her transition to stomach-tube feeding and eventually oral feeding. She also handed out teddy bears complete with their own percutaneous endoscopic gastrostomy (PEG) feeding tube to help educate nurses, caregivers and patients about how a feeding tube works and how it is placed in the abdomen. (See her full story at Boston Scientific's Endoscopy Channel www.bostonscientific.com/global-endoscopy.) Boston Scientific plans to continue its work with the Oley Foundation over the next year by participating in patient-advocacy conferences throughout the U.S.

GLOBAL STANDARDS IN SUPPORT OF TUBE COMPLIANCE

Boston Scientific is also working with the Global Enteral Device Supplier Association (GEDSA) to help educate the health care community about new international standards in medical device tubing connectors to enhance patient safety. The new standards are focused on preventing a non-feeding tube device being connected to a feeding tube port. Devices that adhere to the new standards are expected to be commercially available in 2015. GEDSA is working with several organizations to educate patients about the changes. For information about GEDSA please visit www.StayConnected2014.org.



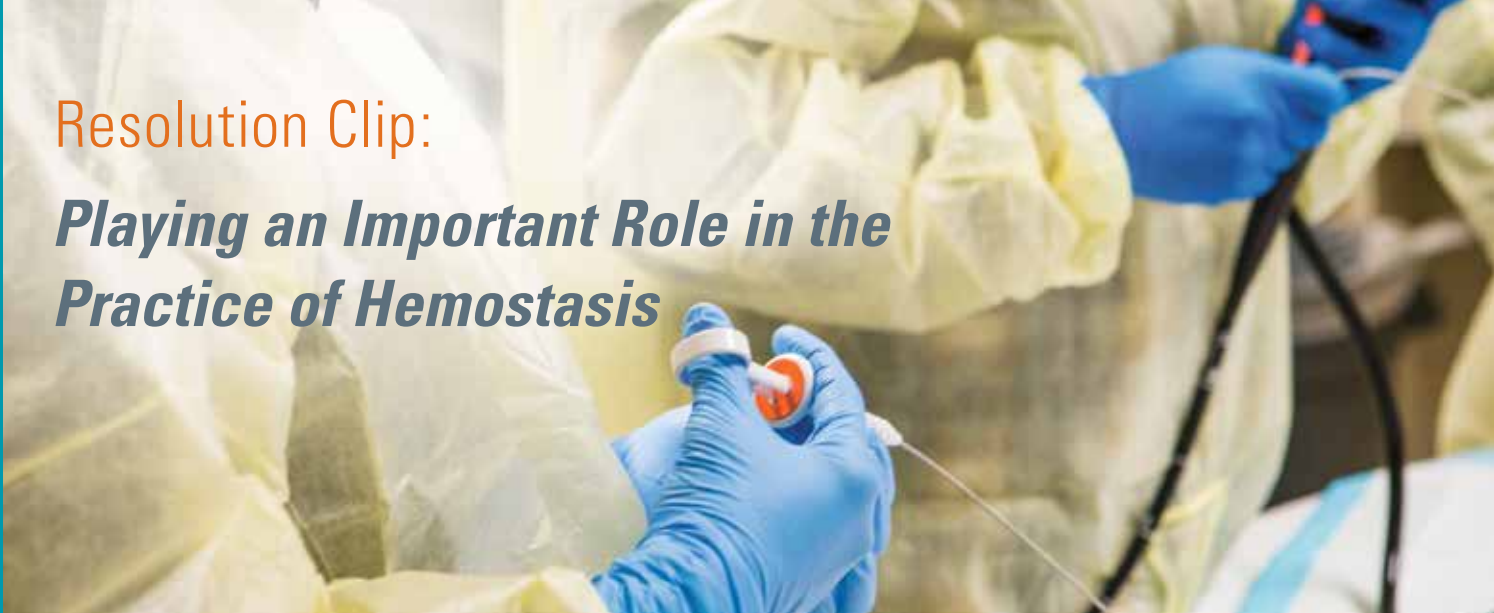“Without my Boston Scientific J-Tube I honestly don't know if I would be alive.”
— Amanda Singer

Boston Scientific
Advancing science for life.

Visit the **Boston Scientific Endoscopy Channel** on **YouTube** to view Amanda Singer's story.

Resolution Clip:

Playing an Important Role in the Practice of Hemostasis



Introduced in 2004, the Resolution™ Clip has played a large role in helping change the way physicians practice hemostasis and treat their patients. The wide jaw opening of the Resolution Clip and the ability to reposition prior to deployment has helped to significantly improve the ease of use and control of the device for many physicians. To date, over 5 million have been sold and more than 2.5 million patient lives have been impacted by Resolution Clip.

With more than 220 studies published on its safety and effectiveness, the Resolution Clip has a strong proven clinical history.

- Many of the studies have shown that fewer Resolution Clips were needed to treat patients than other clips.
- Study results demonstrated that acute ulcers treated with injection/multi-polar electrocautery (MPEC) had arithmetically more transmural and histologic injury than those treated with hemoclips.
- Successful closure of chronic gastric ulcers appears to accelerate the ulcer healing and cause less tissue injury than injection/MPEC.
- Mechanical clipping has been shown to provide initial hemostasis and reduce rebleeding compared to these other modalities.

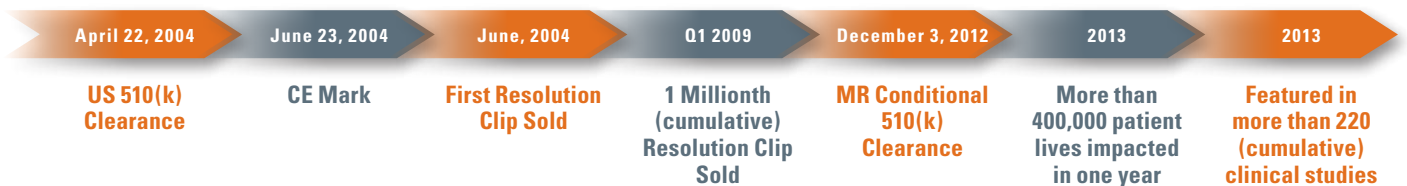“The initial two Resolution Clip Devices with their wide jaws and closing pressure were able to take the opposing sides of the luminal perforation and to provide an adequate seal. By utilizing the Resolution Clip to close the perforation during the endoscopy, the patient was able to avoid surgery.”

Excerpt from a case study by **Eric C.S. Lam, MD, FRCP**, University of British Columbia, Vancouver, British Columbia, Canada, in the May/June 2014 issue of ACCESS magazine.

“The clip of choice is Resolution Clip, capable of opening, closing and repositioning. The deployment apparatus is also less prone to technician error and failed deployments than other clips on the market.”

Excerpt from case study by **David A. Florez, MD**, Elms Digestive Disease Specialists, Charleston, South Carolina, in the Oct. 2012 issue of ACCESS magazine.

RESOLUTION™ CLIP



Why Clip Retention Matters

Recent studies show that 20% of ulcer rebleeds occur between 4 and 30 days in patients whose ulcer hemorrhage started as an outpatient before hospitalization, while at least 50% of ulcer rebleeds for inpatients occur 1 week or more after initial hemostasis. These findings suggest a clinical need for longer clip retention in many of these patients. In a randomized, prospective study on

hemoclippping of chronic canine ulcers, “the Resolution Clip was retained significantly longer” than other hemoclips in the study with no delay in ulcer healing. With new health care guidelines focused on patient satisfaction and reducing hospital stays and readmissions, longer clip retention could have a significant impact on these measures.

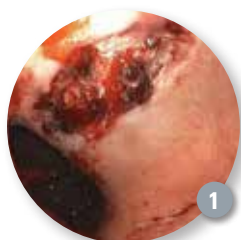Combination Therapy with Resolution Clip Devices Closes a Mallory-Weiss Tear



CASE PRESENTED BY:

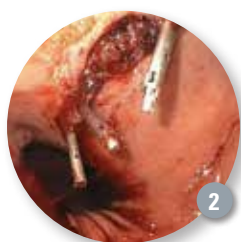
JOHN J. CANELLA III, M.D.

Midwest Gastrointestinal Associates PC
Omaha, Nebraska, USA



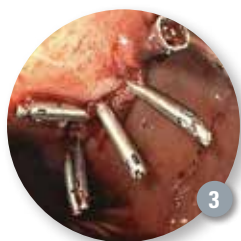PATIENT HISTORY

A 77-year-old male, without significant past medical history, presented to the emergency department after a few episodes of hematemesis. Earlier in the day he had eaten a bologna sandwich and, shortly thereafter, became nauseated with increasing epigastric distress. He described multiple episodes of "violent vomiting" followed by hematemesis. At presentation, he was orthostatic and his hemoglobin was 7.6 gm/dL. He denied NSAIDs, antiplatelet agents, or anticoagulant use. He was admitted to the ICU, and adequately resuscitated with IV fluids and 2 units of packed cells prior to endoscopy.



PROCEDURE

The patient was sedated with midazolam 5mg and fentanyl 50mcg IV, and monitored appropriately in the ICU. A high-definition upper endoscope was advanced under direct visualization into the esophagus. A large (2.5cm), longitudinal mucosal defect consistent with a Mallory-Weiss tear was encountered along the lesser curvature of the stomach (Figure 1). This was within the intrathoracic portion of a small sliding hiatal hernia and was actively bleeding. Blood was encountered in the stomach and duodenum, which were completely inspected and void of additional lesions.



Attention was then turned to treatment of the actively bleeding Mallory-Weiss tear. Epinephrine (1:10,000 x 4cc) was injected to stop the bleeding and improve visualization for anticipated clip closure. Two Resolution Clip Devices were successfully applied to the distal aspect of the lesion resulting in excellent tissue apposition. A single clip was then applied at the proximal margin, resulting in narrowing of the center portion of the lesion from 10mm to approximately 5mm, allowing

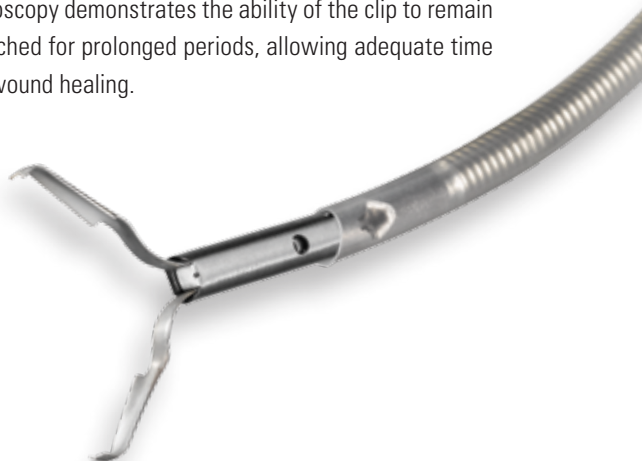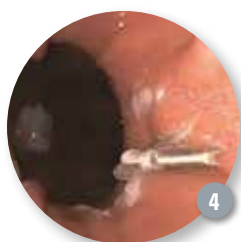better grasping for additional clips (Figure 2). A total of seven Resolution Clip Devices were placed with excellent tissue apposition and cessation of bleeding (Figure 3).

POST-PROCEDURE / PATIENT OUTCOME

The patient had no post-procedure complications. In addition to endoscopic therapy, proton pump inhibitor therapy was initiated and continued on an outpatient basis. He remained stable throughout his hospitalization and was discharged within 48 hours. A follow-up endoscopy was performed five weeks later. Excellent healing was observed and 3 clips remained in place (Figure 4).

CONCLUSION

This case demonstrates the typical presentation of upper gastrointestinal bleeding secondary to a Mallory-Weiss tear and successful treatment with the Resolution™ Clip Device. Endoscopic treatment of these lesions has been accomplished utilizing injection of epinephrine or sclerosants, thermal therapy, and mechanical modalities including clips. In this particular case, epinephrine was utilized as a vasoconstrictor, allowing for cessation of bleeding and improved visualization for combination therapy with Resolution Clip Devices. Thermal therapy was not considered given the size and depth of the lesion and concern for perforation. Clip application has proven efficacy for treatment of Mallory-Weiss tears, and this case illustrates successful tissue apposition and resultant hemostasis of a large lesion. Follow-up endoscopy demonstrates the ability of the clip to remain attached for prolonged periods, allowing adequate time for wound healing.



Resolution Clip Devices Close Muscularis Propria Laceration of the Esophagus



CASE PRESENTED BY:
VITOR ARANTES, M.D., MSc, Ph.D
 Professor of Medicine and Surgery
 Director of Endoscopy Unit
 Alfa Institute of Gastroenterology
 Federal University of Minas Gerais
 Belo Horizonte, BRAZIL

PATIENT HISTORY

A 72-year-old male was referred for endoscopic ultrasound (EUS) examination due to suspicion of stones in the common bile duct. The patient's health history included more than 20 years of alcohol and tobacco use as well as a past cholecystectomy and common bile duct surgical exploration. Thirty years prior, a partial gastrectomy with Billroth I reconstruction was performed due to peptic ulcer disease.

PROCEDURE

During endoscopic evaluation, a diminutive flat-elevated 0-IIa reddish lesion was noted in the middle third of the esophagus (Figure 1). EUS disclosed common bile duct stones and, after evaluation of the esophageal lesion, it was determined that the mucosa and superficial submucosa layers were affected. No suspicious lymph nodes were observed; however, the biopsy was consistent with esophageal squamous-cell cancer. After discussion with the patient and his physician, he was not considered a good candidate for major surgery. The management plan included endoscopic retrograde cholangiopancreatography (ERCP) and endoscopic submucosal dissection (ESD) of the esophageal lesion.

The patient initially underwent ERCP under anesthesia sedation. A common hepatic duct stricture associated with choledocholithiasis was noted and an endoscopic sphincterotomy with plastic stenting was performed. One week later, ESD was performed under general anesthesia with CO₂ insufflation. The lesion was demarcated, mucosal incision was performed (Figure 2) and the tumor was resected enbloc in a total of 60 minutes. Due to submucosal infiltration and fibrosis encountered during the procedure, submucosal dissection was conducted in the deep submucosal layer close to muscularis propria (MP). At the end of the procedure a profound laceration of the MP layer was observed with exposition of the longitudinal fibers and possible micro perforation (Figure 3). A decision was made to close the defect with metallic clips. Two Resolution Clip Devices were applied and complete closure of the defect was obtained, utilizing the border

of the mucosal layer to cover the laceration entirely (Figures 4 and 5). The specimen was fixed, stained with lugol showing adequate lateral margins and sent for histological assessment (Figure 6).

OUTCOME / POST PROCEDURE

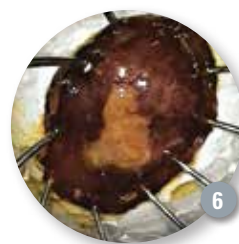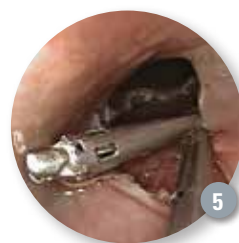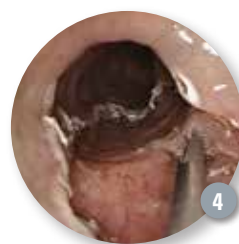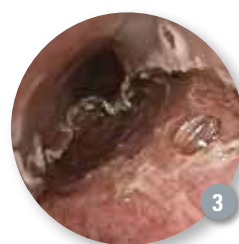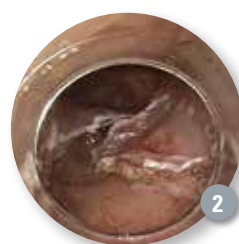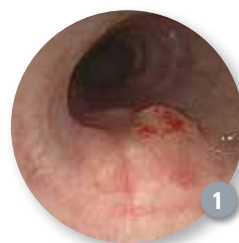The patient remained asymptomatic in the postoperative period, without subcutaneous emphysema or chest pain, and was kept on intravenous antibiotics (cephalosporin for three days). A liquid diet was introduced on the first postoperative day. The patient was discharged after three days of observation and instructed to return to a regular diet.

Histology revealed a well-differentiated squamous-cell cancer with infiltration up to a deep submucosa layer that measured as 1500µm from the muscularis mucosae with free vertical and lateral margins and no lymphovascular invasion. The patient was referred for adjuvant chemo radiotherapy (CRT) and afterwards will be scheduled for another ERCP for biliary stricture cytology, increased dilation and multiple stenting.

CONCLUSION

This case illustrates that even a diminutive incidental esophageal neoplastic lesion, under 1cm, can be extremely aggressive with deep submucosal invasion. ESD allowed complete removal of the tumor enbloc and precise histological assessment and staging indicated a need for additional CRT due to the risk of lymph node metastasis.

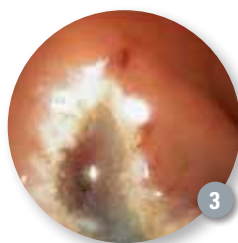
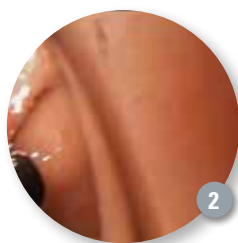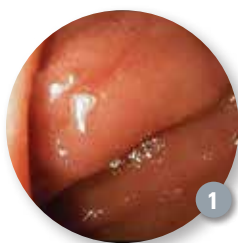Endoscopists who perform advanced endoscopic resection need to be well trained in the management of complications, particularly bleeding and perforation. Resolution Clip Devices offer a perfect solution for repair of lacerations of the MP layer and perforations during EMR/ESD. **The Resolution Clip was handled simply and easily by my assistant and the elongated arms of the clip helped facilitate approximation of the defect, allowing for repositioning of the device as many times as needed in order to accomplish a safe suture.**



Removal of a Large Duodenal Polyp During Endoscopic Mucosal Resection



CASE PRESENTED BY:
JEREMY BARBER, D.O.
Mercy Health
Michigan, USA



PATIENT HISTORY

A cachectic 66-year-old woman weighing 89 lbs. with chronic pancreatitis and mesenteric stenosis was referred for removal of duodenal adenoma after a routine endoscopy. A routine esophagogastroduodenoscopy (EGD) and endoscopic ultrasound were performed previously, with the biopsy proving duodenal adenoma at the duodenal bulb (Paris classification IIa, 1.7cm, **Figure 1**). The patient was referred for minimally invasive treatment due to surgical risk.

PROCEDURE

An upper EGD was performed with monitored anesthesia care. The patient was placed in a left lateral position and the gastroscope was inserted into the duodenal bulb. In the apex of the duodenal bulb entering into duodenal sweep there was noted the 1.7cm adenoma. Using an Interject™ Sclerotherapy Needle, the polyp was lifted using a saline solution with indigo carmine (3 cc). Three injections were made at the lateral margins (**Figure 2**). An en bloc resection of the adenoma was performed using a 15mm Captivator™ II Single-Use Snare with cautery applied (**Figure 3**). Argon plasma was applied to the margins utilizing a circumferential catheter.

Three Resolution™ Clips were placed without difficulty to close the less than 3cm defect. Excellent hemostasis was achieved.

The polyp was dragged into the gastric lumen and then a TWISTER® PLUS Rotatable Retrieval Device was used to retrieve the specimen.



PATIENT OUTCOME

The patient tolerated the procedure well and was placed on a soft diet for one week and was counseled on smoking cessation. A repeat endoscopy is scheduled for three months to check for residual adenomatous tissue.

Although there is limited data for use of argon plasma, the technique was utilized to decrease the risk of polyp recurrence and for closure.

CONCLUSIONS

The stiffness of the Captivator II Snare was designed for en bloc resection of flat polyps with an ability to grab the polyp and provide tactile response to the assistant to ensure the correct amount of pressure is applied when resecting. The TWISTER PLUS Rotatable Retrieval Device is essential for retrieving specimens.



Endoscopic Papillary Balloon Dilation After Sphincterotomy for Difficult Choledocholithiasis: a Single Center Experience



CASE PRESENTED BY:
MARCELLO CAMPAIOLI, M.D.

Gastroenterology and Digestive Endoscopy Unit
S. Stefano Hospital
Prato Hospital, ITALY

PATIENTS

A year-long endoscopic study of nine patients (6 male, 3 female) with difficult common bile duct (CBD) stones was performed. The patients' ages ranged from 35 to 83 years of age, with the average age, being approximately 67 years of age.

PROCEDURE

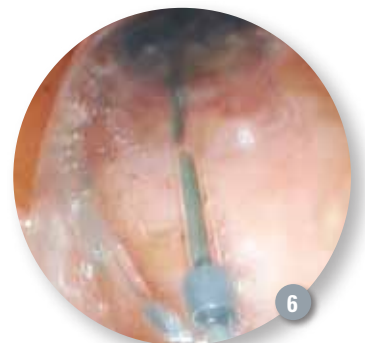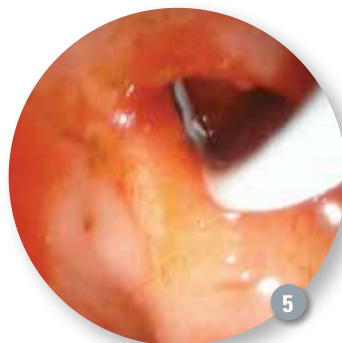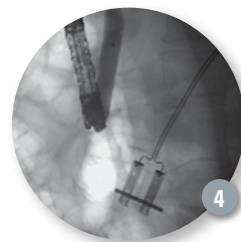
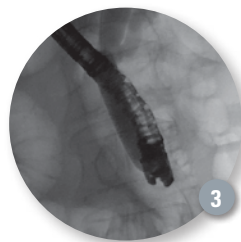
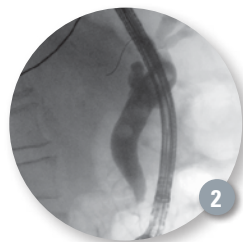
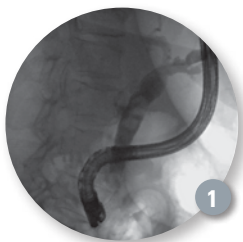

Endoscopic retrograde cholangiopancreatography (ERCP) was performed with a side-viewing endoscope to view the stones (**Figures 1 and 2**). After a complete endoscopic sphincterotomy, patients underwent papillary large-balloon dilation using a through-the-scope catheter gradually inflated with a CRE™ Single-Use Wireguided Biliary Balloon Dilator (**Figure 3**). The catheter balloon sizes used included 10-12mm in five cases up to 12mm; 12-15mm in three cases up to 13.5mm; and 18-20mm in one case up to 19mm, according to the size of the largest stone and the maximum diameter of the distal bile duct in the cholangiography. The duration of the papillary balloon dilatation was 30 seconds (**Figure 4**). Stones were then removed using a retrieval balloon catheter and/or a basket (**Figure 5**).

OUTCOMES

Stones were successfully removed from the common bile ducts of all nine patients without the use of mechanical lithotripsy. And no perforation or bleeding requiring transfusions occurred. Additionally, no clinically significant pancreatitis appeared after ERCP.

CONCLUSIONS

In our experience, endoscopic balloon dilatation with a large size balloon is a technique that may be preceded by complete sphincterotomy in the treatment of difficult common bile duct stones. **The CRE Wireguided Balloon is the only dilation balloon that is indicated for use during this type of procedure.**



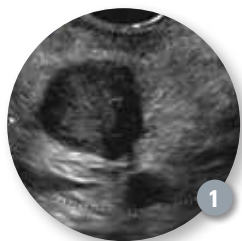Expect Slimline (SL) Endoscopic Ultrasound Aspiration Needle for Diagnosis of Neuroendocrine Pancreatic Tumor



CASE PRESENTED BY:

MARIA CHIARA PETRONE, M.D.

Chief of Endosonography Unit
Division of Gastroenterology and
Gastrointestinal Endoscopy
San Raffaele Scientific Institute, ITALY

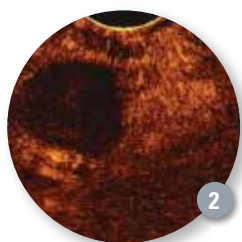

PATIENT HISTORY

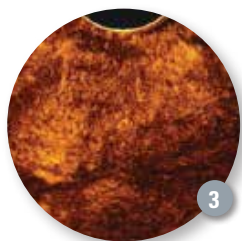A 58-year-old male had a CT scan performed during preoperative staging of prostate carcinoma that indicated an incidental finding of a solid nodule in the head of the pancreas.

PROCEDURE

Endoscopic ultrasound fine needle aspiration (EUS-FNA) was performed under deep propofol sedation, indicating a hypoechoic and homogeneous nodule located in the head of the pancreas. The lesion measured about 16mm with regular borders and appeared to be predominantly green at elastography evaluation (**Figure 1**).


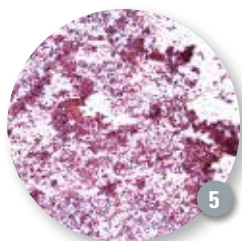
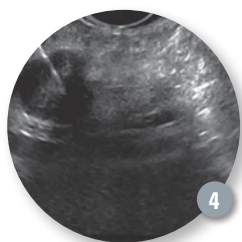


The Doppler signal was negative and after contrast agent infusion, the lesion showed a hypervascular pattern (**Figures 2 and 3**). FNA was performed using a 25 gauge Expect™ Slimline (SL) Endoscopic Ultrasound Aspiration Needle (**Figure 4**). The sharpness and flexibility of the needle allowed smooth access to the tumor. A slow-pull technique using the stylet was performed for capillary sampling. The actuation and precision of the puncture allowed us to obtain adequate material in a single pass, sufficient even to perform immunostaining.



CONCLUSION

Final cytological diagnosis was positive for neuroendocrine tumor (**Figure 5**). **This case nicely illustrates the efficacy of the 25 gauge Expect Slimline (SL) Endoscopic Ultrasound Aspiration Needle, allowing precise puncture to obtain an excellent cytology specimen.**



News and New Devices

- **The Advanix™ Pancreatic Stent** and NaviFlex™ RX Pancreatic Delivery System, and NaviFlex Pushers are indicated for pancreatic duct drainage. The Advanix Pancreatic Stent is made of a flexible material, comes in a wide range of sizes and shapes, and has radiopaque markers to provide enhanced visualization* under fluoroscopy.

*Radiopaque markers are not available on all stents. Data claim does not apply to the 3Fr stent.



- **The Captivator™ II Single-Use Snares** are Boston Scientific's first line of stiff and rounded snares that are available in multiple sizes with both a hot and cold snaring indication. They are specifically designed for the removal of diminutive polyps, colonic endoscopic mucosal resection (EMR) as well as standard polypectomy. Four new sizes allow clinical flexibility by expanding the size options to range from 10mm to 33mm.

- **The TRUEtome™ Cannulating Sphincterotome** is now available with a preloaded guidewire. The TRUEtome Dreamwire™, TRUEtome Hydra and TRUEtome Jag Cannulating Sphincterotomes use DirecTip™ Technology to provide a center-lumen design. This design allows the guidewire to extend from the center of the sphincterotome to aid in positioning and facilitates wireguided cannulation.



- **WallFlex™ Stents. Guaranteed.** Boston Scientific is committed to providing physicians with the highest quality stents. If a physician is not satisfied with the patency of a covered or partially covered WallFlex Stent that is placed endoscopically in accordance with the directions for use, Boston Scientific will provide a replacement WallFlex Stent of identical dimensions. Contact your Boston Scientific representative for details about the program or visit www.bostonscientific.com/endo-resources. This program may not be available in all countries.

WARNING: The safety and effectiveness of the WallFlex Biliary Stents for use in the vascular system has not been established.

Opt-in to receive ACCESS magazine electronically and email updates on new products, indications and resources. Visit www.bostonscientific.com/endo-access-subscribe.

ACCESS Magazine was produced in cooperation with several physicians. The procedures discussed in this document are those of the physicians and do not necessarily reflect the opinion, policies or recommendations of Boston Scientific Corporation or any of its employees.

Results from case studies are not predictive of results in other cases. Results in other cases may vary.

Indications, Contraindications, Warnings and Instructions for Use can be found in the product labeling supplied with each device.

Caution: Federal (U.S.) law restricts this device to sale by or on the order of a physician.

CAUTION: The law restricts these devices to sale by or on the order of a physician. Information for the use only in countries with applicable health authority product registrations.

WARNING: The safety and effectiveness of the WallFlex Biliary Stent for use in the vascular system has not been established.

All trademarks are property of their respective owners.

TWISTER® PLUS is a trademark of Horizons International Corp. Distributed by Boston Scientific Corporation, Natick, Massachusetts; manufactured by Horizons International Corp., Heredia, Costa Rica.

©2014 Boston Scientific Corporation or its affiliates. All rights reserved.

DINEND2335EA

ENDO-271817-AA September 2014

**Boston
Scientific**