




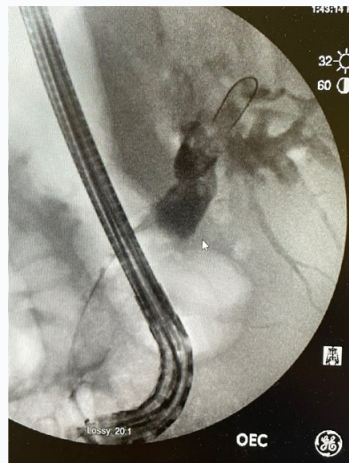
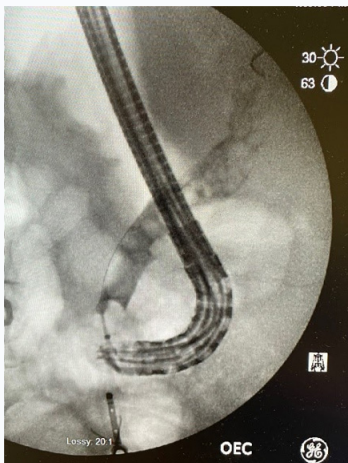
EXALT™ Model D Single-Use Duodenoscope With SpyGlass™ DS Direct Visualization System for Retained Common Bile Duct Stent and Stone Impaction

Eric Frizzell, M.D.
Pinehurst Medical Clinic, Pinehurst, N.C.



Patient History & Assessment

An 86-year-old woman with a history of Extended spectrum beta-lactamases Escherichia coli cholangitis due to a retained common bile duct (CBD) stent presented to attempt complete clearance of her CBD. The stent had been initially placed seven years ago. She had been seen both locally and at a tertiary center with three previous attempts to remove the stent as the stent is not intended to be used as a permanent implant. These were only partially successful as the stent was impacted in a CBD stone cast of the bile duct.



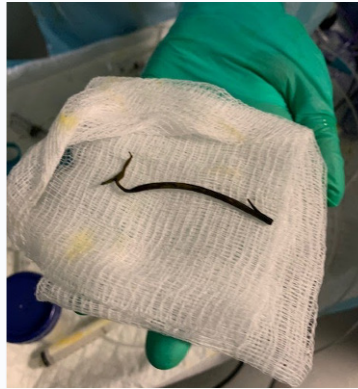
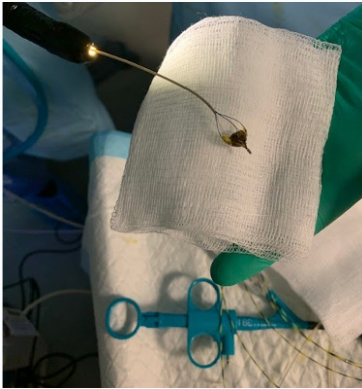Procedure

An ERCP was performed using EXALT Model D due to previous history of MDR infection. The CBD was cannulated and contrast injected, showing multiple stones in the CBD.

[Read More >>](#)

Procedure

1. After dilation of the previous sphincterotomy with a CRE™ Wireguided Balloon Dilatation Catheter, multiple stones were removed with balloon sweeps.
2. The CBD was then examined with the SpyGlass™ DS system, revealing a retained stent in the mid CBD.
3. The stent was removed with the SpyGlass Retrieval Basket.
4. Multiple stones were found above a common hepatic duct stricture. These were fractured with EHL and fragments were removed with the basket.
5. Stricture was biopsied with the SpyBite™ Biopsy Forceps.



Case Outcome/Discussion

The patient was discharged after the procedure and has done well. The biopsy of the stricture showed only inflammation.

The use of the EXALT Model D system in patients with a history of MDR infection eliminates the risk of contamination of scopes to ineffective reprocessing.

The use of the SpyGlass System allowed direct visualization of the stent. Using the SpyGlass™ Retrieval Basket to capture the stent under direct visualization was straightforward.

Removing stone fragments and the stent required removing the entire Spyglass and Model D system from the patient in order to clear the basket.

Ampullary dilation allowed for direct cannulation of the CBD with SpyGlass System.

IMPORTANT INFORMATION: These materials are intended to describe common clinical considerations and procedural steps for the use of referenced technologies but may not be appropriate for every patient or case. Decisions surrounding patient care depend on the physician's professional judgment in consideration of all available information for the individual case. Boston Scientific (BSC) does not promote or encourage the use of its devices outside their approved labeling. Case studies are not necessarily representative of clinical outcomes in all cases as individual results may vary.

Images provided courtesy of Eric Frizzell, M.D.

CAUTION: The law restricts these devices to sale by or on the order of a physician. Indications, contraindications, warnings and instructions for use can be found in the product labeling supplied with each device. Products shown for INFORMATION purposes only and may not be approved or for sale in certain countries. This material not intended for use in France. Rx Only. All trademarks are the property of their respective owners.

©2021 Boston Scientific Corporation or its affiliates. All rights reserved. ENDO-966204-AA