

# GreenLight XPS™ Laser Therapy System

A SYSTEMATIC APPROACH TO THE  
VAPORIZATION INCISION TECHNIQUE (VIT)



**Ricardo R. Gonzalez, MD**

Urologist  
Houston Methodist Urology Associates  
Houston, Texas

# GreenLight XPS™ Laser Therapy System:

## A SYSTEMATIC APPROACH TO THE VAPORIZATION INCISION TECHNIQUE (VIT)

### TECHNIQUE SPOTLIGHT

Ricardo Gonzalez, MD

Focusing on key fundamentals and following a systematic approach to laser vaporization can enhance GreenLight Laser Therapy surgical efficiency.

Dr. Ricardo Gonzalez has used GreenLight Laser Therapy effectively in his practice for over 17 years. The following technique summary was developed based on his experience with the technology and his patient outcomes.

#### Patient selection

Most patients with moderate-to-severe benign prostatic hyperplasia (BPH) are GreenLight Laser Therapy candidates for urologists with adequate experience. First cases are best performed using the classic systematic vaporization technique on patients with glands approximately 50cc and with minimal median lobe component.

Many patients present with larger prostates or intravesical median lobe. With additional experience with the GreenLight system, additional techniques can be employed to help provide these patients an option, as well.

Traditionally, for prostates over 80 grams, many would consider the standard of care to be an open prostatectomy. In my practice, I do not feel that is the safest option for benign disease. For larger prostates, I typically use the Vaporization Incision Technique (VIT) to remove prostate tissue. This systematic approach uses anatomical landmarks, committing to getting to the capsule and removing as much tissue as possible.

#### Patient workup

Patient examination: Flexible cystoscopy and transrectal ultrasound (TRUS) are strongly encouraged. These methods:

- Help with surgical planning
- Allow for easier capsule recognition intra-operatively
- Aid in patient counseling
- Help rule out other pathology


*American Urological Association (AUA) guidelines also recommend: AUA symptom score, PSA when appropriate, flow rate and post void residuals. Formal urodynamics are optional but helpful in select cases.*

#### OR preparation

- Broad spectrum antibiotic
- DVT prophylaxis
- B & O Suppettes™ suppository (B & O 16A) at the time of surgical prep
- Hold anticoagulation when safe and in consultation with cardiologist

## OR equipment and anesthesia

- General anesthesia with laryngeal mask preferred, especially if the patient is on anticoagulants but spinal can also be used
- Comfortable rolling chair to perform the procedure sitting
- Continuous flow cystoscope (23–24.5F) with laser bridge for MoXy™ Liquid Cooled Fiber, and visual obturator to avoid traumatizing mucosa upon scope insertion
- Continuous flow resectoscope (26–28F) with a separate laser bridge for MoXy Fiber may be helpful for larger, bloody glands
- Dedicated urology HD camera (pendulum style) recommended locked out of the way of the fiber



Cystoscope set with visual obturator

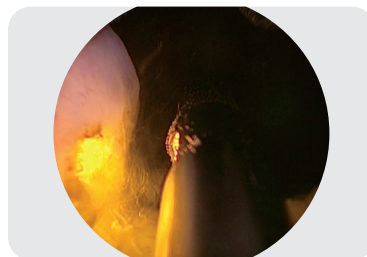

Resectoscope set with visual obturator

- Camera filter or 30-degree telescope with built-in GreenLight system filter preferred
- Two to four 3-liter bags of normal saline with large irrigation tubing
- Additional 1-liter bag of saline for irrigation of the MoXy Fiber; ensure this is connected utilizing IV tubing and irrigating prior to fiber insertion into the scope
- GreenLight Fiber

## GreenLight™ Laser Therapy fundamentals

- **Fiber-to-tissue distance:** 1–3mm away from tissue is optimal, but not in contact with tissue. The MoXy Fiber tip is 2.1mm and provides a good visual to help determine proper fiber-to-tissue distance. Always ensure the ability to visualize laser-tissue interaction.



Optimal fiber-to-tissue distance

- **Sweep speed:** adjust sweep speed to maximize vaporization efficiency. The key is to heat the tissue to 100 degrees Celsius for vaporization to occur.
- **Sweep arc:** 30 degrees is optimal
- **Power settings:** start low and increase to maintain maximal vaporization while maintaining visibility
- Minimize the number of times the bladder is drained during the procedure, as this can result in undesired bleeding due to reduction of pressure within the bladder

## Scope handling and maneuvering

This is important and differs somewhat from transurethral resection of the prostate (TURP):

- Rotate the fiber as described in the Fundamentals section with the dominant hand
- Manipulate the scope (not the camera) with the non-dominant hand. The scope can be used to mechanically manipulate and palpate tissue.
- Move both hands together and rotate the scope, as one would with TURP, to circumferentially treat the prostate

# THE VAPORIZATION INCISION TECHNIQUE (VIT) PROCEDURE

## Identifying landmarks

✓1 ✓2 ✓3

- Atraumatically, locate the ureteral orifices (UOs) using a visual obturator. (Fig. 1) ✓1
- If they cannot be seen, at least try to identify the ureteric ridge. After the bladder neck is opened with 5 and 7 o'clock lateral incisions, UOs are more easily visualized in large prostates.
- Assess how much median lobe is present and assess the amount of intravesical tissue to be vaporized. (Fig. 2)
- Introduce the laser fiber in the visual field, confirm irrigation for both scope and laser fiber and activate aiming beam. ✓2
- Identify the verumontanum. Using coagulation, you may demarcate the limits of distal dissection (3 and 9 o'clock position) at the level of the verumontanum. (Fig. 3) ✓3
- The bladder should be kept at least moderately distended. This helps identify the prostate from the bladder anteriorly and laterally, and also helps control bleeding.

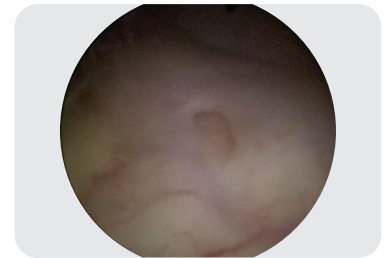


Figure 1 - Left ureteral orifice

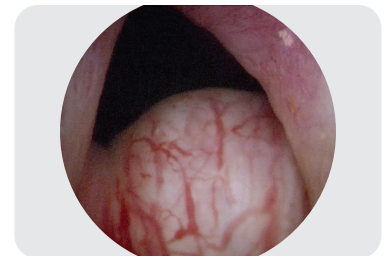

Figure 2 - Assessment of median lobe

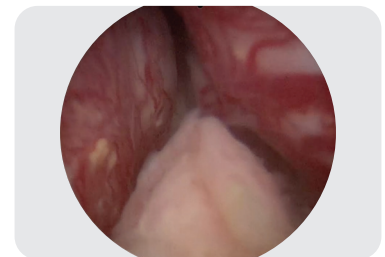

Figure 3 - Verumontanum

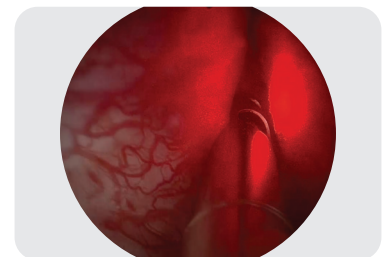


Figure 4 - Aiming beam

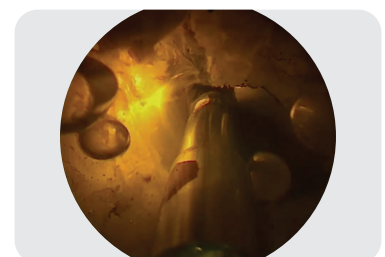


Figure 5 - Scuba-like bubbles

## Create a Working Channel

✓4

- Activate aiming beam by putting the laser on "ready." (Fig. 4)
- Begin with low power (80-120W) with the goal to turn up the power quickly as a good flow is established.
- If the lateral lobes are touching, make a working channel that's made between 9 and 3 o'clock on low energy with a fast sweep. Once there's good flow with the continuous flow cystoscope, I can visualize the median lobe and expose the lateral sucli at 5 and 7 o'clock.

Efficient vaporization remains the key goal and is confirmed with the creation of large, "scuba-like" bubbles. (Fig. 5) Small, "champagne-like" bubbles result from a combination of vaporization and coagulation. Vaporizing without the creation of bubbles is evidence of coagulation and is the biggest cause of post-operative irritative symptoms.

### Bubbles = Feedback



- Bubbles are an indicator of vaporization efficiency
- Greater distance results in more coagulation; less vaporization

### Lack of bubbles = Trouble (coagulation, edema)

- You will notice increased bubbles during vaporization when using the system at higher power
- You may need to make adjustments to manage increased bubble formation and maintain good visualization

## Median lobe



- Start at 5 o'clock. Begin at the 5 o'clock sulcus at the bladder neck, and create a groove from the bladder neck towards the apex. Repeat the treatments to deepen and widen the groove down to the surgical capsule. 
- Repeat this same process at the 7 o'clock sulcus at the bladder neck to the apex, deepening to capsule. Increasing to 120W may be needed to maintain efficient vaporization. (Fig. 6, 7 & 8)
- Once these grooves have been created, you will have demarcated the median lobe from other prostate tissue.
- As the 5 and 7 o'clock grooves are completed and you reach the distal edge of the median lobe, veer onto the lateral lobe on the apex. This can help avoid getting into bleeders on each side of the veru.
- Demarcate the proximal and distal edge of the median lobe to define the boundary along the capsule and approximately 1 cm proximal to the verumontanum.
- Increase energy to 180W and vaporize the isolated median lobe. You can also consider vaporesecting by making longitudinal laser grooves in the median lobe until you reach the capsule.
- Remove the isolated median lobe tissue with medially directed lasing along the surgical capsule on both sides (180W). 

Ensure that the resected tissue is small enough to be removed with graspers at the end of the procedure. If not, cut the median lobe into smaller sections before releasing these segments into the bladder.

- Push the tissue sections into the bladder for removal later in the procedure.
- On high energy, smooth the floor of the prostate to create a gentle slope from bladder neck to veru. Do not undermine the bladder.

Bleeding may be encountered during the procedure, especially at the 5 and 7 o'clock locations where the vasculature enters the prostate. Vaporizing around and through these areas to control it is important. If needed, utilize the TruCoag™ Hemostatic Control feature and "paint" around the bleeder to create hemostasis.




Figure 6 - Laser firing at 5 o'clock

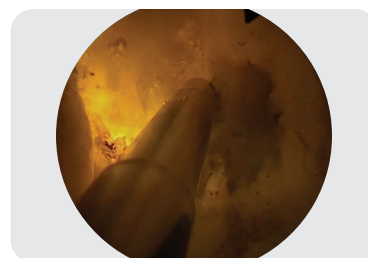

Figure 7 - Laser firing at 7 o'clock

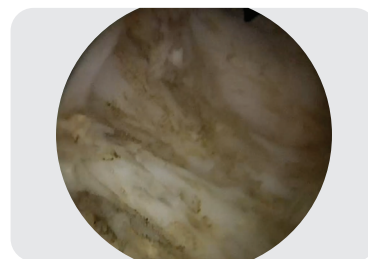


Figure 8 - Bladder neck fibers

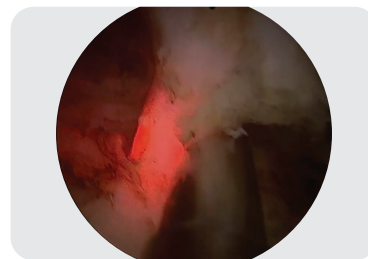


Figure 9 - Directing the laser beam medially to resect the median lobe

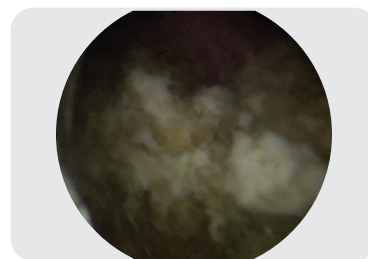


Figure 10 - Resected tissue in the bladder

# THE VAPORIZATION INCISION TECHNIQUE (VIT) PROCEDURE

## Lateral lobes

✓7 ✓8 ✓9 ✓10

- Create an anterior 1 o'clock groove from the bladder neck to the apex, deepening to the surgical capsule (120W). ✓7
- Follow the surgical capsule with the laser fiber. Starting this groove in the middle of the prostate is easiest, but the goal is to visualize the anterior commissure to help identify the prostate capsule and drop down the lateral lobes. Release the left lateral lobe from the surgical capsule. (Fig. 11)
- Complete the left lateral lobe treatment with systematic vaporization or vapor incision fragmentation of the isolated tissue (180W). ✓8
- Create an anterior 11 o'clock groove from the bladder neck to the apex, deepening to the surgical capsule (120W). Follow the surgical capsule with the laser fiber to release the right lateral lobe from the surgical capsule. ✓9
- Complete the right lateral lobe treatment with systematic vaporization or vapor incision fragmentation of the isolated tissue (180W).

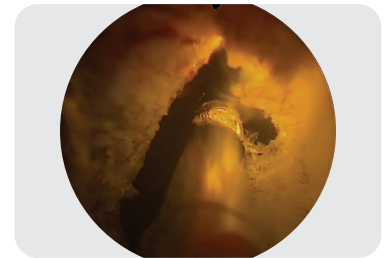


Figure 11 - Lasing lateral tissue



Figure 12 - Lasing anterior tissue

## Anterior tissue

- After the lateral lobes and median lobe are adequately treated, address the anterior tissue. Remember, the prostate is the thinnest in this area and the anterior lateral lobes.
- First, look to see if there's anterior tissue that needs treatment. If you really started in the anterior commissure, which is one o'clock and 11 o'clock, there should be very little tissue left anteriorly to treat.
- However, if treatment is necessary, turn the energy down and rotate the scope if needed so that you get the beak out of the way and so that the 30-degree lens is looking at the roof. Working retrograde can avoid the creation of "flaps" that obscure vision and help in protecting the external sphincter. (Fig. 12)
- From there, very carefully vaporize any anterior tissue that needs to be removed.

## Apical tissue

- Once all anterior tissue has been removed, check for apical tissue. There's often more tissue than you expect there. (Fig. 13) ✓10
- Decrease the power to lower wattage (~120W) to limit bleeding.
- Working "around the corner" at the apex is important; work laterally and not posteriorly to the level of veru until there is no apical obstruction.
- To remove the distal apical tissue, work in a retrograde manner away from the sphincter.
- Vaporize alongside and even beyond the veru if adenoma extends distally in larger glands staying proximal to the external sphincter. (Fig. 14)

If possible, work away from danger; if it's a ureteral orifice, work in the opposite direction. If it's the sphincter, also work in the opposite direction giving your back to danger.

## Completing the procedure

- 50-65% of the prostate volume should be eliminated for a durable outcome. (Fig. 15) ✓11 ✓12
- In my experience, PSA is reduced more than 50% after adequate healing. The fossa should look like a well-resected TURP defect.
- The remaining fossa will be relatively smooth. Within 3 months, there is generally smooth re-epithelialization.
- Confirm the surgical endpoint, verification of anatomic landmarks, hemostasis and tissue removal. ✓11
- Consider administering Lasix™ 10mg approximately 10 minutes prior to completing the procedure, if desired. This not only helps diuresis, but also helps irrigate the catheter.
- Atraumatic placement of a Foley catheter (20 or 22F 2-way; a 3-way Foley may be placed, but may not offer benefits for patients treated as outpatients). Patients on anticoagulants need a 3-way catheter and can be observed overnight if CBI is required. ✓12

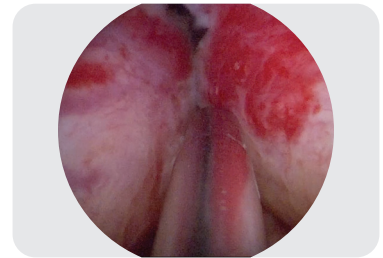


Figure 13 - Untreated left apical tissue

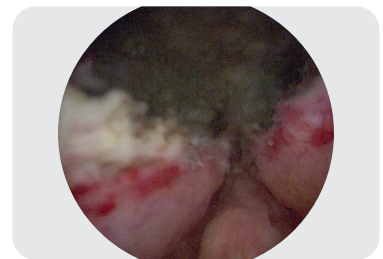

Figure 14 - Treated apical tissue

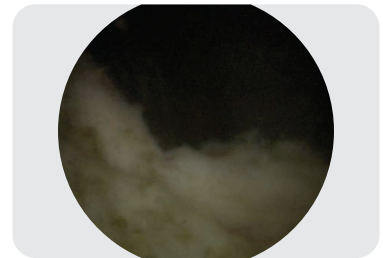


Figure 15 - Open fossa

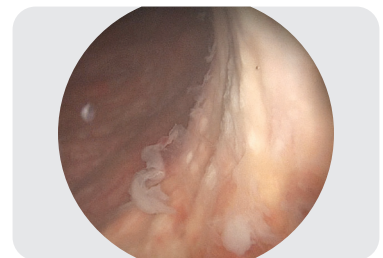


Figure 16 - Fossa 4 weeks post-op

# A SYSTEMATIC APPROACH TO VAPORIZATION INCISION TECHNIQUE (VIT)

As with all surgical procedures, there are a number of ways to successfully treat BPH using the GreenLight XPS Laser Therapy System. However one chooses to systematically approach a given procedure, adherence to the basic principles outlined below is the cornerstone to repeatable surgical success and patient satisfaction.

- ✓ **1** Identify key anatomic landmarks with cystoscope.
- ✓ **2** Introduce the laser fiber, confirm irrigation and activate aiming beam.
- ✓ **3** Demarcate limits of distal dissection at level of verumontanum.
- ✓ **4** Create working channel (80-120W) from bladder neck to apex if lateral lobes are coapting.
- ✓ **5** Repeat treatment at 5 and 7 o'clock to widen groove; continue to vaporize to surgical capsule.
- ✓ **6** Remove isolated median lobe tissue by lasing along surgical capsule (180W).
- ✓ **7** Create groove in anterior commissure from bladder neck to apex, deepening to surgical capsule (120W).
- ✓ **8** Complete left lateral lobe with systematic sequential vaporization or vapo-resection.
- ✓ **9** Release right lateral lobe from surgical capsule (120W).
- ✓ **10** Complete right lateral lobe with systematic sequential vaporization or vapo-resection.
- ✓ **11** Confirm surgical endpoint and verify landmarks, hemostasis and tissue removal.
- ✓ **12** Case completion, place Foley catheter.

The GreenLight™ Laser System is intended for incision/excision, vaporization, ablation, hemostasis and coagulation of soft tissue, including the Vaporization Incision Technique (VIT) for benign prostatic hyperplasia (BPH). The laser system is contraindicated for patients who: are contraindicated for surgery, contraindicated where appropriate anesthesia is contraindicated by patient history, have calcified tissue, require hemostasis in >2mm vessels, have uncontrolled bleeding disorders, have prostate cancer, have acute urinary tract infection (UTI) or severe urethral stricture. Possible risks and complications include, but are not limited to, irritative symptoms (dysuria, urgency, frequency), retrograde ejaculation, urinary incontinence, erectile dysfunction, hematuria - gross, UTI, bladder neck contracture/outlet obstruct, urinary retention, perforation - prostate, urethral stricture.

Caution: U.S. Federal law restricts this device to sale by or on the order of a physician.

CAUTION: The law restricts these devices to sale by or on the order of a physician. Indications, contraindications, warnings and instructions for use can be found in the product labeling supplied with each device. Information for use only in countries with applicable health authority registrations. Material not intended for use in France.

Products shown for INFORMATION purposes only and may not be approved or for sale in certain countries. Please check availability with your local sales representative or customer service.

IMPORTANT INFORMATION: These materials are intended to describe common clinical considerations and procedural steps for the use of referenced technologies but may not be appropriate for every patient or case. Decisions surrounding patient care depend on the physician's professional judgment in consideration of all available information for the individual case.

Boston Scientific (BSC) does not promote or encourage the use of its devices outside their approved labeling. Case studies are not necessarily representative of clinical outcomes in all cases as individual results may vary.

Results from case studies are not necessarily predictive of results in other cases. Results in other cases may vary.

All images are the property of Boston Scientific. All trademarks are the property of their respective owners.

**Boston  
Scientific**  
Advancing science for life™

Boston Scientific Corporation  
300 Boston Scientific Way  
Marlborough, MA 01752  
www.bostonscientific.com

© 2020 Boston Scientific Corporation  
or its affiliates. All rights reserved.

URO-553310-AA JAN 2020