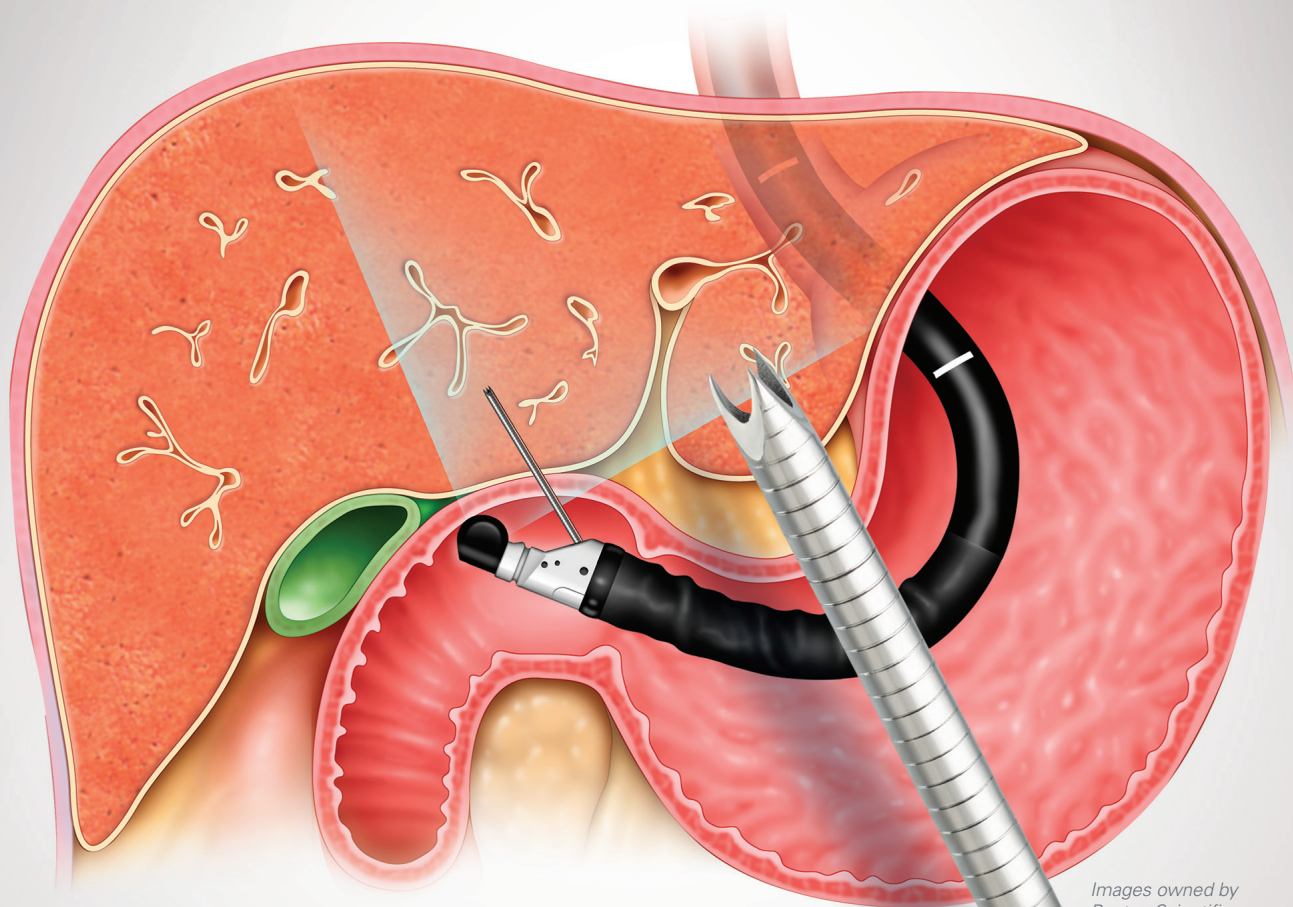


# Acquire™ 19ga Flexible FNB Device

Suitable for EUS-Guided Liver Biopsy

**Boston  
Scientific**  
Advancing science for life™



Images owned by  
Boston Scientific.



## A Choice for EUS-Guided Liver Biopsy

More recently, endoscopic ultrasound guided liver biopsy (EUS-LB) has been discussed as a liver biopsy method.<sup>1</sup> EUS-LB uses high frequency ultrasound to visualize the liver for biopsy from inside the stomach and duodenum. Based on the limited evaluation of EUS-LB, the data suggests that EUS-LB is a safe method for liver biopsy.<sup>1</sup>

# Why EUS-Guided Liver Biopsy?

The Boston Scientific Acquire™ EUS-FNB 19ga Flexible Needle design is well-suited for liver biopsy cases, which require needle flexibility for navigation and acquisition in challenging lobe anatomy.

The Acquire EUS-FNB 19ga Flexible Needle is designed with a Franseen needle tip—a three-point cutting design proven for sample acquisition.<sup>2,3</sup> As the biggest needle size in Acquire Needle family, the Acquire 19ga Flexible Needle may help meet the American Association for the Study of Liver Disease (AASLD) guidelines<sup>4</sup> for liver biopsy. Reasons to consider EUS-Guided Liver Biopsy:

Click here to watch EUS-guided liver biopsy programs and cases on [EndoSuite.com](https://www.endsuite.com).

---

## **EUS-LB Safety:**

- Real-time Doppler helps to avoid intrahepatic vessels<sup>1</sup>
- Low complication rates\* (a multi-center study calls out a complication rate of 0.9%<sup>1</sup>)

---

## **EUS-LB Clinical Efficacy:**

- Reduce sampling error using fanning technique and ability to sample both lobes of liver<sup>1</sup>
- Simultaneous evaluation of the pancreas, gallbladder, common bile duct and other structures<sup>1</sup>
- Concurrent EGD to evaluate upper digestive disorders such as Barrett's, varices, workup for abdominal pain, etc.<sup>1</sup>
- Adequate or superior specimens to percutaneous and transjugular<sup>5</sup>

---

## **EUS-LB Patient Experience:**

- Single procedure is convenient and cost effective<sup>1</sup>
- Patient stays within gastroenterology allowing for ongoing direct communication<sup>1</sup>
- Sedation/analgesia for patient comfort, reduced anxiety, and eliminates need for breath hold<sup>1</sup>

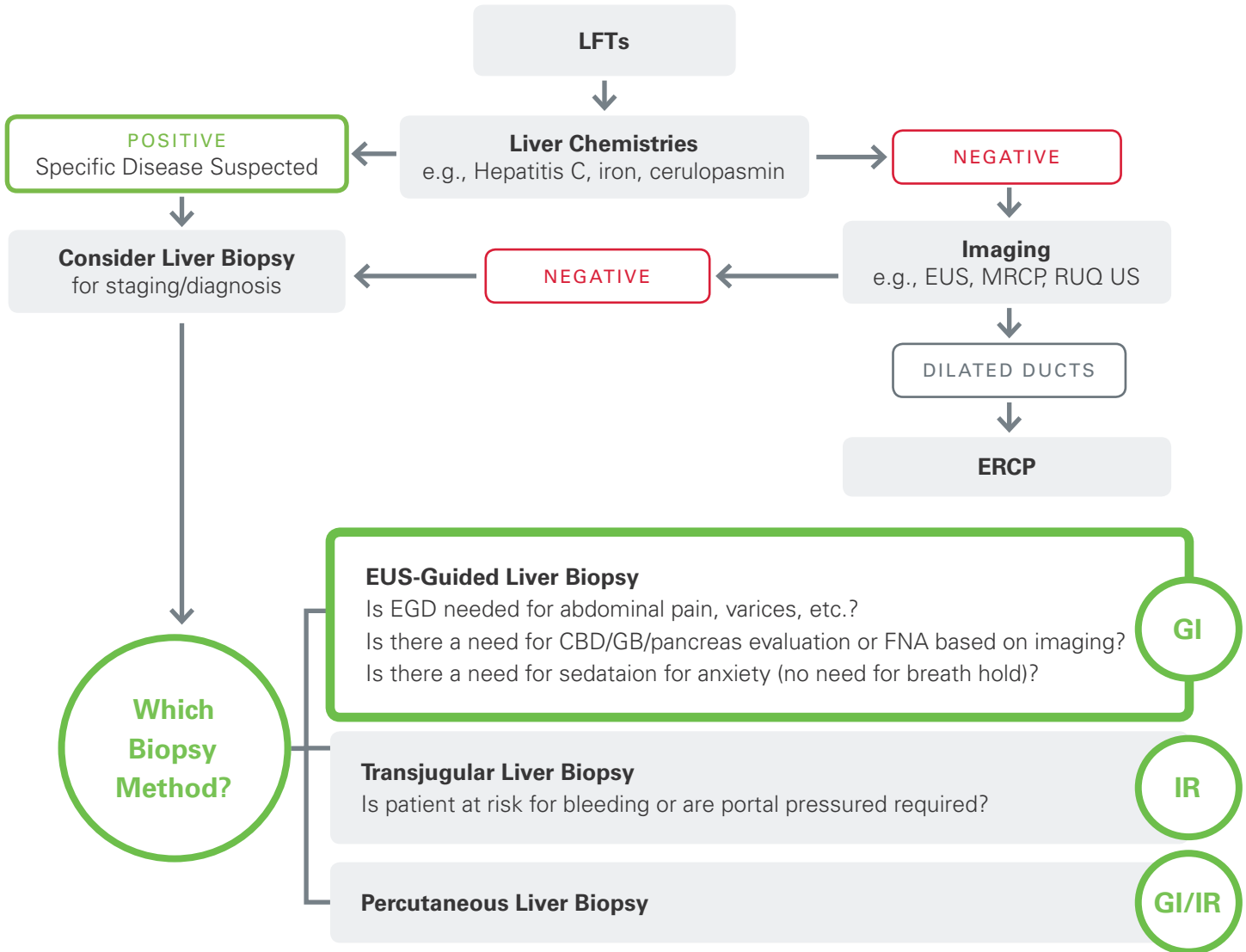
---

## **EUS-LB Hospital Benefits:**

- Only a few minutes added to endoscopic procedure.<sup>1</sup> From a ten patient study, liver FNA for histology added 4 minutes on average to the time of the EUS procedure<sup>7</sup>
- Potential to increase outpatient referrals<sup>1</sup>
- Keeps the procedure within GI

*\*Further studies required*

# Elevated Liver Function Test (LFT) Patient Pathway\*



*Patient pathway presented by David L. Diehl, MD, FACP, FASGE Director, Interventional Endoscopy, and Amitpal Singh Johal, MD, Director, Endoscopy Geisinger Medical Center Clinical Professor of Medicine, Temple School of Medicine*

## Patient Selection

An ideal candidate where EUS Guided Liver Biopsy should be considered is any patient undergoing an endoscopic procedure who also needs a liver biopsy:

- Patient with elevated LFT's and negative EUS for stones and/or stricture
- Patients with suspected liver disease who is undergoing an EGD (Barrett's, varices, abdominal pain, etc.)
- Patients who require sedation for liver biopsy
- Patients who require biopsy of both left and right liver lobes

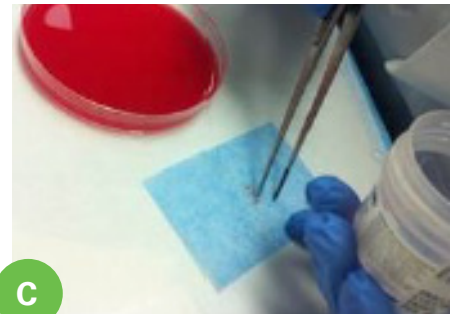
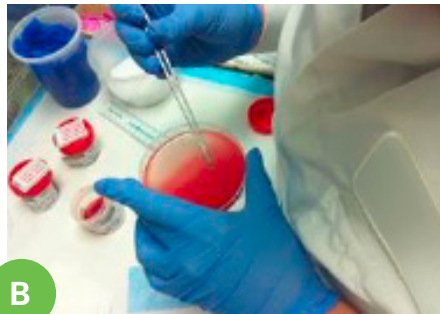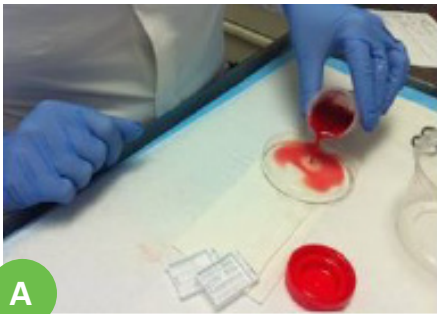
\*A patient with thrombocytopenia or coagulopathy may be better suited for transjugular liver biopsy

# Pathology

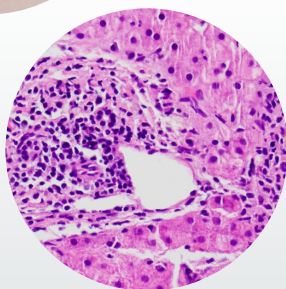
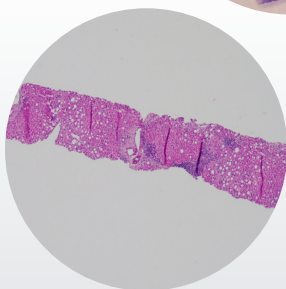
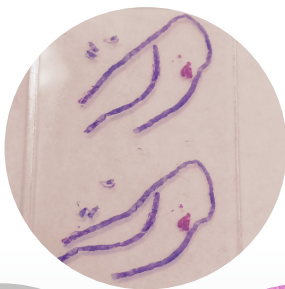## Specimen Preparation:

Speak to pathology to ensure proper handling of the specimen. The process below is intended to be performed by pathology to consolidate tissue:

1. Express into formalin
2. Technician pours contents into petri dish (figure a)
3. Pieces of liver tissue distinguishable from clot (figure b)
4. Wrap specimen in lens paper (figure c)
5. Process as surgical specimen



Photos provided by Dr. Diehl and Dr. Johal.



Portal Triads= 28

Mean Total Specimen Length = 8cm

## Specimen Adequacy:

- Specimen adequacy remains widely debated and can vary by pathologist and liver biopsy method
- Diagnostic tissue adequacy of 98% in EUS-LB prospective multicenter trial with 19ga Flex needle<sup>1</sup>
- Needles as small as 20ga may be used in transjugular liver biopsies

Image, portal triads and Specimen length information are provided by Jose M. Nieto, D.O.

## Endoscopic Ultrasound-Guided Liver Biopsy: A Multicenter Experience<sup>1</sup>

Diehl et al.

- 8 centers biopsied 110 patients with 19Ga Expect or 19Ga Flex
- 98% specimen adequacy for pathological diagnosis (median tissue length = 38mm; median CPT = 14)

### Quantified yields from endoscopic ultrasound liver biopsies.

	Patients	Median tissue length, mm (range)	Median CPTs (range)
Both Lobes	68	40 (9 - 148)	17 (65)
Left Only	34	32 (0 - 203)	13 (0-68)
Right only	8	49 (8-113)	14 (6-34)

CPTs, complete portal triads

## EUS-Guided Liver Biopsy Provides Diagnostic Samples Comparable with Those via the Percutaneous or Transjugular Route<sup>5</sup>

Geisinger Medical Center, Danville, PA

- EUS-LB of both lobes had better tissue yield (TSL & CPT) than PC & TJ
- EUS LB of left lobe only was equivalent to PC and TJ

### EUS-LB Needle

19Ga Expect

### TJ Needle

18 or 19Ga

### PC Needle

18 or 20Ga

Methods	No. of Cases	TSL (mm)	CPT
EUS-LB	110	38 (24-81)*	14 (9-27)*
EUS-LB (transgastric only)	34	32 (16-66)	13 (6-23)
EUS-LB (both transgastric and transduodenal)	68	40 (30-82)**	17 (10.5-29)*
PC-LB	27	25 (15-38)	10 (7-16)
TJ-LB	38	34 (24-48)	15.5 (9-21)

\* Indicates statistically significant p value compared to PC

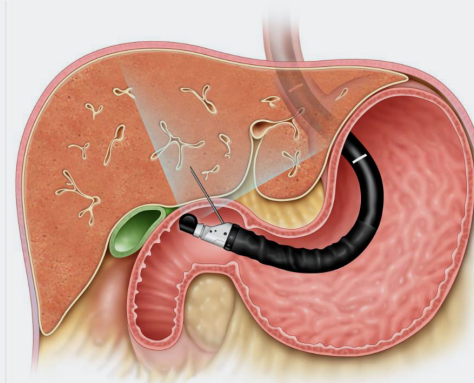
\*\* indicates statistically significant p value compared to TJ

The values of CPT and TSL were reported as median with range of 25th to 75th percentile

## 113 Consecutive Transgastric Liver Biopsies for Hepatic Parenchymal Diseases: A Single-Institution Study<sup>6</sup>

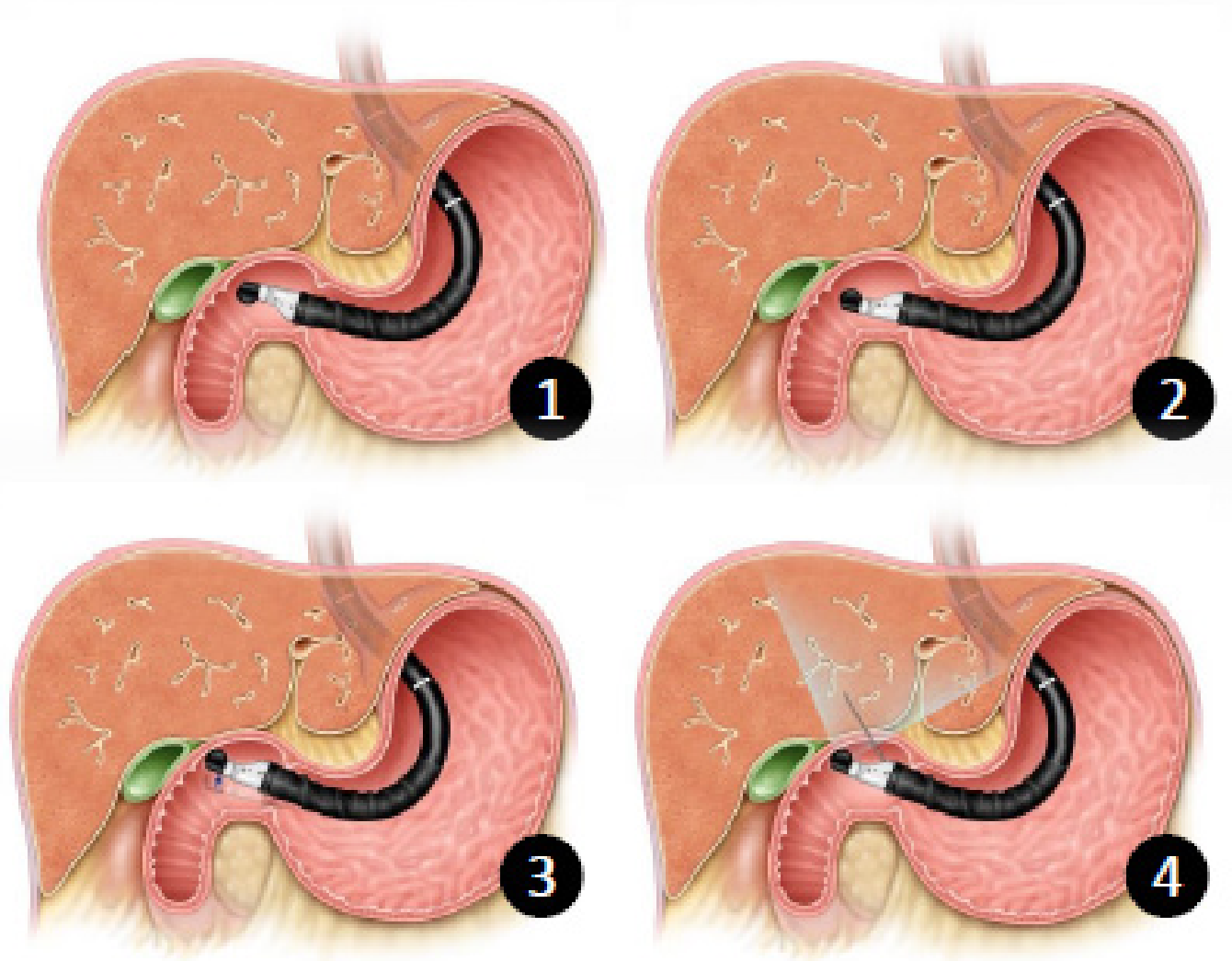
Indiana University, Indianapolis, IN

- More complete portal tracts provided by 19Ga Flex needle compared to QuickCore and ProCore needles
- 19 Flex was non-inferior to percutaneous or transjugular approaches in regards to number of portal tracts provided





## Ease of Access



*Images owned by Boston Scientific.*

### **Right Lobe Access**

1. Approach the apex of duodenal bulb (Refer to figures 1-4 above)
2. 180 degree torque
3. Knob up
4. Use Doppler to identify puncture site
  - Site should have minimal blood flow
  - Acquire 19ga Flexible FNB Device
  - Perform 7-10 actuations with 20cc suction

### **Left Lobe Access**

- Identify celiac artery
- 90° counter clockwise torque
- Knob up

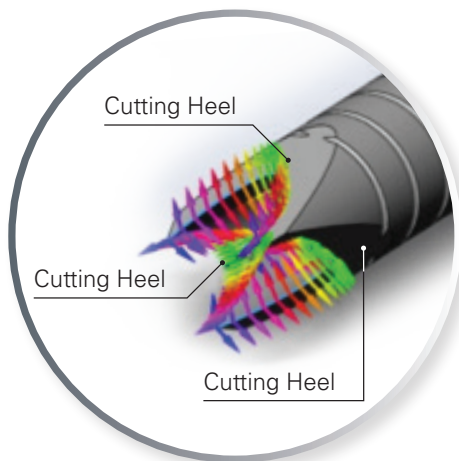


Image owned by Boston Scientific.

## The Acquire™ EUS-FNB needle is designed to capture bigger tissue specimens

### The Acquire EUS-FNB needle has the following features:

- High quality cutting surfaces that allow for a circumferential cut
- Three points that are designed to provide stability at puncture
- Echogenicity that allows for visibility of the needle under EUS
- The 19ga Flex is constructed with Nitinol, which is more resistant to needle deformation through tortuous anatomy compared to stainless steel\*
- Improving MD confidence and sample quality

### Ordering Information— Acquire 19ga Flexible FNB Device

Order Number	Needle Size	Minimum Working Channel	Sheath Diameter	Quantity
M00555580	19ga Flex (1.14mm)	2.8mm	1.73mm	Box 1

### Ordering Information— Expect™ Slimline (SL) 19ga Flexible Needle

Order Number	Needle Size	Minimum Working Channel	Sheath Diameter	Quantity
M00555530	19ga Flex (1.14mm)	2.8mm	1.73mm	Box 1
M00555531	19ga Flex (1.14mm)	2.8mm	1.73mm	Box 5

Packaging includes a 20cc syringe and one-way stopcock

Working length: 137.5cm to 141.5cm, adjustable

Needle length: 0cm to 8cm, adjustable

\*Data on file; comparable size.

#### References

1. Diehl, D. L., et al (2015) Endoscopic ultrasound-guided liver biopsy: a multicenter experience. *Endoscopy International Open*, 3(3), E210–E215.
2. Reference: Dahnert, Wolfgang F, et al (1992) Fine-Needle Aspiration Biopsy of Abdominal Lesions: Diagnostic Yield for Different Needle Tip Configurations. *Interventional Radiology*, 185:263-268.
3. Ballard, Gary L. and Boyd, Wayne R. (1978) A Specially Designed Cutting Aspiration Needle for Lung Biopsy. *American Journal of Roentgenology*, 130: 899-903.
4. Rockey, Don C. et al (2009) Liver Biopsy. *Hepatology*, 49(3): 1017-1043.
5. Pineda JJ, Diehl DL, Miao CL, Johal AS, Khara HS, Bhanushali A, Chen EZ. EUS-guided liver biopsy provides diagnostic samples comparable with those via the percutaneous or transjugular route. *Gastrointest Endosc*. 2015 Aug 22
6. Nakanishi Y1, Mneimneh WS, Sey M, Al-Haddad M, DeWitt JM, Saxena R. 113 Consecutive Transgastric Liver Biopsies for Hepatic Parenchymal Diseases: a Single Institution Study. *Am J Surg Pathol*. 2015 Jul;39(7):968-76
7. Gor et al. Histological adequacy of EUS-guided liver biopsy when using a 19-gauge non-Tru-Cut FNA needle. *GASTROINTESTINAL ENDOSCOPY* Volume 79, No. 1 : 2014.

All trademarks are the property of their respective owners.

Indications, contraindications, warnings and instructions for use can be found in the product labeling supplied with each device.

Caution: Federal U.S. law restricts this device to sale by or on the order of a physician.

CAUTION: The law restricts these devices to sale by or on the order of a physician. Information for the use only in countries with applicable health authority registrations. Material not intended for use in France.

**Boston Scientific**

Advancing science for life™

Boston Scientific Corporation  
300 Boston Scientific Way  
Marlborough, MA 01752  
www.bostonscientific.com  
www.EndoSuite.com

**Ordering Information**  
**1.888.272.1001**

©2017 Boston Scientific Corporation  
or its affiliates. All rights reserved.

ENDO-356602-AB December 2017