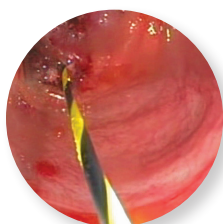

Endoscopic Palliation of Symptomatic Malignant Colonic Obstruction

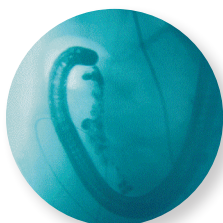

Sri Komanduri, MD, MS

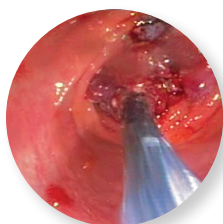
Director, EUS
Assistant Professor of Medicine
Section of Gastroenterology and Nutrition
Rush University Medical Center
Chicago, IL



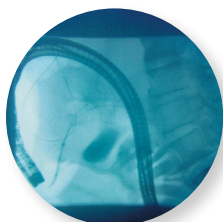
A guidewire is advanced proximal to the tumor



Contrast agent injected into the lesion to identify the stricture



The WallFlex delivery system is introduced into the colonoscope



WallFlex Stent partially deployed

Patient History and Assessment

A 66-year-old man with a history of hypertension was admitted because of nausea, vomiting and generalized abdominal pain over a two week period. Laboratory studies revealed an iron deficiency anemia. Initial abdominal film suggested a partial proximal colonic obstruction. A CT scan of the abdomen revealed a large transverse colon mass with proximal dilatation of the colon and distal small bowel. We also observed innumerable liver metastases. The CEA level was 832 ng/ml (nl < 5), suggestive of metastatic colon cancer. A colonoscopy was initially performed and a large fungating mass was found in the distal transverse colon just distal to the hepatic flexure. Mucosal biopsies revealed an infiltrating colon adenocarcinoma. Subsequently, a second colonoscopy was performed for palliation of the colonic obstruction.

Identifying and Measuring the Stricture

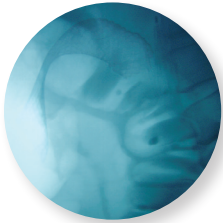After reaching the mass with a standard colonoscope, a standard Boston Scientific biliary cannula was advanced and full strength contrast was injected under fluoroscopic guidance. The mass was outlined as a 7cm irregular stricture with normal colon proximal.

WallFlex Colonic Stent Placement

Due to its proximity to the hepatic flexure and the extent of proximal dilatation, a larger diameter stent with flexibility was desirable. We have often found stenting of the right colon to be difficult because of the lack of stent flexibility and migration problems. The WallFlex Stent system reduces these concerns with its increased flexibility and flared end, and, at the same time, maintains the convenience of a Through-the-Scope (TTS) deployment system.

This system allows for reconstraining and repositioning the stent at up to 70% deployment; extremely valuable in a tortuous area such as the hepatic flexure.

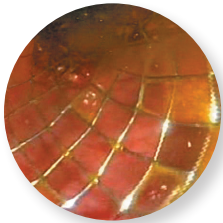
A 0.035 inch Hydra Jagwire™ Guidewire was advanced with ease proximal to the tumor and coiled under fluoroscopic guidance. A WallFlex Stent with a 25mm diameter body, 30mm flare and 12cm length was selected and the delivery system was introduced into the colonoscope. Under endoscopic and fluoroscopic guidance, the WallFlex Stent was positioned above the stricture and initially deployed 50% and reconstrained due to suboptimal placement. After recapturing the stent, the catheter was repositioned using the fluoroscopic markers to identify its distal and proximal ends. Upon deployment, the stent was successfully placed across the stricture and confirmed with fluoroscopic images.



WallFlex Stent fully deployed

Post Deployment

A post-placement Kidneys, Ureters and Bladder (KUB) radiograph demonstrated accurate placement of the stent across the stricture. Within one hour, a repeat KUB was performed and decompression of the proximal colon and small bowel was documented, and the patient experienced a rapid release of a large volume of stool. Preoperatively, the cecum was dilated to 10cm and, post stent placement, was down to 6cm, indicating that the obstruction was relieved. The patient tolerated the procedure well, resuming a full diet two days post stent placement. Discharged from the hospital on the fifth day, the patient had no complaints when he returned for a check up at three months; he had gained 15 pounds, was eating a full diet, and had no difficulty with bowel movements. Overall, the patient reported his quality of life had improved dramatically and this has increased his desire to complete chemotherapy.



WallFlex Stent fully deployed

Summary of Clinical Experience

The proper selection of a colonic stent is essential when providing palliation of obstruction. Until recently, right-sided colonic lesions have been regarded as too difficult for colonic stenting. The advent of flexible Through-the-Scope (TTS) stents has significantly improved our options, by providing a flexible, large diameter, flared stent amenable to difficult right colonic strictures.

Boston Scientific
 Advancing science for life™

Boston Scientific Corporation
 One Boston Scientific Place
 Natick, MA 01760-1537
www.bostonscientific.com/endo-resources

Ordering Information
1.888.272.1001

©2013 Boston Scientific Corporation
 or its affiliates. All rights reserved.

ENDO-180403-AA August 2013

Results from case studies are not predictive of results in other cases. Results in other cases may vary.
 Jagwire and WallFlex are registered or unregistered trademarks of Boston Scientific Corporation or its affiliates.
 Indications, Contraindications, Warnings and Instructions for Use can be found in the product labeling supplied with each device.
Caution: Federal (USA) law restricts this device to sale by or on the order of a physician.